ATLANTIS PRESS
Advances in Intelligent Systems Research, volume 167
International Scientific and Practical Conference "Digitization of Agriculture - Development Strategy" (ISPC 2019)

Structural features of the mucous membrane of the pelvic part of the urogenital canal of fur animals of the canine family

Vladimir Telenkov
Veterinary Faculty
Omsk State Agrarian University named after P.A. Stolypin
Omsk, Russia
vn.telenkov@omgau.org

Gennady Khonin
Veterinary Faculty
Omsk State Agrarian University named after P.A. Stolypin
Omsk, Russia
ga.khonin@omgau.org

Sergey Meleshkov
Veterinary Faculty
Omsk State Agrarian University named after P.A. Stolypin
Omsk, Russia
sf.meleshkov@omgau.org

***Abstract*—The prostate gland and the mucous membrane of the prostatic pelvic part of the urogenital canal were studied in a silver-black fox and a blue fox, the representatives of the predatory order belonging to the family of canine. The research method used was morphometry. The correlation analysis of the data was performed on the basis of the Pearson linear correlation coefficient. The structural features of the epithelium cells of the prostatic section of the pelvic part of the urogenital canal are presented, a moderate correlation between the height of the epithelium and the relative mass of the prostate gland in the studied animals was investigated. It was noted that the epithelium of the mucous membrane of the prostatic section of the pelvic part of the urogenital canal was represented by a multi-layered transitional epithelium, which is different due to the epithelial cell size. The prostatic lumen of the pelvic part of the urogenital canal is of a fissured shape, the mucous membrane has numerous complex folds The results of the study can be useful to fur-bearing animal breeders, veterinary morphologists, physiologists and practitioners of veterinary medicine.**

Keywords—fur animals, silver-black fox, blue fox, urogenital canal, epithelium, mucous membrane, prostate gland.

I. Introduction

In the modern Russian and foreign literature, the structure and topography of the prostatic section of the pelvic part of the urogenital canal were described in detail in some animals [1,6,9,10] and humans [4,7,12]. However, there is fragmentary information in relation to predatory animals. The researchers do not specify any distinguished features of the mucous membrane of the urogenital canal, describing that the membrane is assembled along its entire length in longitudinal folds and lined with transitional epithelium [3,4]. In relation to the muscular layer, it is noted that it consists of longitudinal and circular muscle fibers. It is common to distinguish the pelvic part and genital organs in the urogenital canal, and the prostatic section of the pelvic part of the urogenital canal in the prostate gland [1,6,9].

There are researchers who believe that the pelvic part of the urogenital canal, especially its prostatic section and the prostate gland, are directly related to the so-called "sphincter system", which helps to keep urine in the bladder and prevents the reflux of seminal fluid and sperm into the bladder during sexual intercourse [5,8,11,12].

Taking into account the findings about the mucosa of the prostatic section of the pelvic part of the urogenital canal in fur animals of the canine family, we come to the conclusion that there is a need to clarify some aspects such as the size and relative mass of the prostate gland, the features of the mucous membrane in the prostatic section of the pelvic part of the urogenital channel, the structure of the muscular and serous membranes.

II. Research methodology

The purpose of the research is to study the structure of the mucous membrane of the prostatic section of the pelvic part of the urogenital canal in a silver-black fox and a blue fox.

The research samples were 5 bodies of a silver-black fox and 5 bodies of a blue fox, weighing 3.9 ± 0.1 kg and 4.1 ± 0.1 kg, respectively, the samples were brought from animal farms of the Omsk Region and the Republic of Tatarstan.

Not later than one hour after slaughter, the prostate gland together with the prostatic section of the pelvic part of the urogenital canal were removed from the body of an animal. Measurements were made with a metal ruler with divisions in 1 mm. The material for histological examination was kept in 4% neutral aqueous formaldehyde solution, and then it was poured into paraffin blocks. Histological specimens were made according to the standard technique, were stained with hematoxylin and eosin, and then studied under a "Reichert" light microscope. The morphometry of epithelial cells was performed using an MOB-1-16x ocular micrometer.

According to the methodological guidelines [2], statistical processing of the research results and assessment of the significance of differences in secondary data were performed using a Lenovo laptop and the Microsoft Excel 2007 office program. The correlation analysis of the data was performed on the basis of the Pearson linear correlation coefficient.

III. Research results and discussion

In the animals studied from the dorsal and lateral sides, the zone of transition of urethral tract into the urogenital one is framed by the prostate gland, which covers the urogenital canal from the dorsal and lateral surfaces, limiting the prostatic section of the pelvic urogenital canal.

In the silver fox, the prostatic section of the pelvic part of the urogenital canal is projected at the level of the second sacral vertebra and slightly protrudes cranially beyond the cranial branches of the pubic bones by 2/3 of its length. In the blue fox, the middle part of the prostatic section of the pelvic part of the urogenital canal is located on the border of the second and third sacral vertebrae and protrudes cranially beyond the cranial branches of the pubic bones by 1/3 of its length.

The thin capsule covering the prostate gland consists of loose fibrous connective tissue. In its surface layer, there are mostly collagen fibers, which include bundles of smooth myocytes, as well as a small amount of elastic fibers. The study of the inner layer of the capsule shows that it consists only of bundles of smooth myocytes, which the silver fox has a bit more than the blue fox.

The highest concentration of cross-striated muscle tissue is observed in the ventral interlobar groove of the prostate gland, which is part of the prostatic section of the pelvic part of the urogenital canal. These fibers reach the middle of the lateral surface of the prostate gland, penetrating into the capsule. In the cranial third of the organ capsule, there is the largest number of cross-striated muscle fibers, the number of which decreases towards the caudal margin of the prostate gland. The bundles of smooth myocytes are ring-shaped, and among them, there are individual cross-striated muscle fibers (Fig.1).

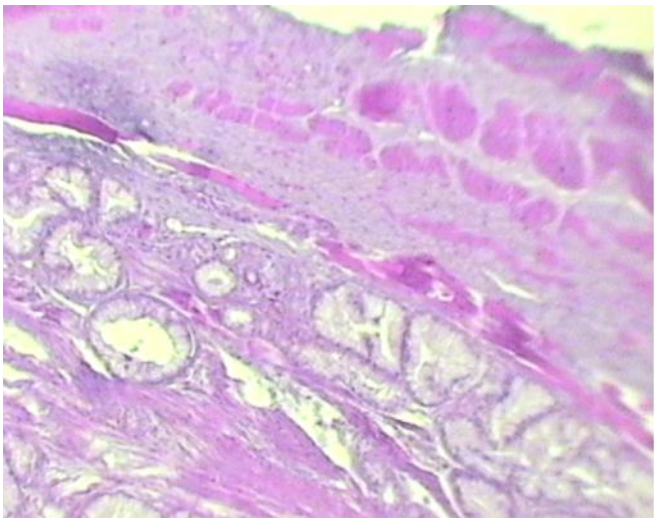

Fig. 1. The capsule of the prostate of a silver-black fox. It was stained with hematoxylin and eosin. Field lens 40, Field glass 15.

The partitions of the prostate gland consist of bundles of smooth myocytes, which include a small amount of collagen fibers. Blood vessels and nerve bundles penetrate into the stroma of the organ from the side of the capsule. The submucosa of the prostatic section of the pelvic part of the urogenital canal is formed by the partitions expanded and directed toward the center of the prostate gland. They mainly consist of collagen fibers. The elastic fibers are few, their number in the stroma of the prostate gland increases in the direction from the periphery of the organ to its center. In groups of animals of the canine family, we established a positive moderate correlation between the elements of stroma and the relative mass of the prostate gland in the silver fox and weak correlation in the blue fox (according to the Pearson linear correlation coefficient, R = 0.362 and R = 0.192, respectively) (Table I).

TABLE I. PARAMETERS THE ELEMENTS OF STROMA OF THE PROSTATE GLAND, X ± SX

Parameters	Silver-black fox	Blue fox
Width of capsule, mcm	64,0±9,0	38,0±7,0
Width of partitions, mcm	58,0±4,0	42,0±8,0
The differences between the indicators within the same group of animals are P <0.05		

Based on the findings, we found out that the prostate parenchyma in a silver fox and blue fox has a tubular-alveolar structure with different configuration of the end sections: from round to oval-elongated and irregular. There are also end sections that do not have a lumen, as well as end sections with nodules included in the lumen. End sections are interconnected by a system of intralobular ducts. The latter flow into the collecting ducts opening into the prostatic section of the pelvic part of the urogenital canal at an acute angle. The epithelium of the collecting excretory ducts is multi-row, up to four rows (Fig. 2).

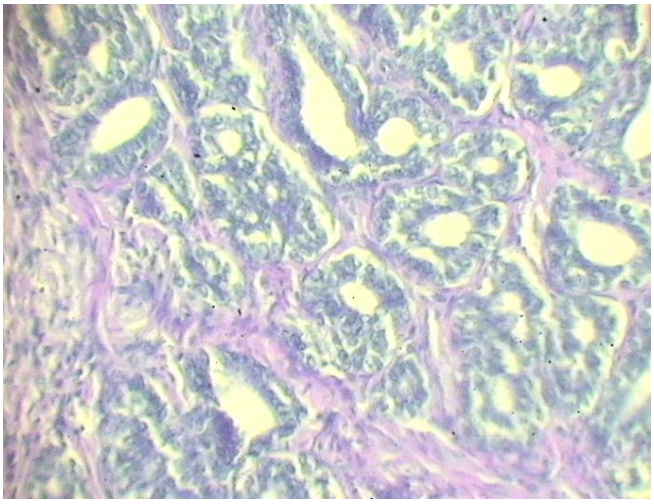

Fig. 2. The collecting excretory ducts of the prostate of a silver-black fox. It was stained with hematoxylin and eosin. Field lens 40, Field glass 15.

In the ducts with a large diameter, the epithelium has the appearance of a single row with inclusions of low prismatic epithelium. In epithelial cells the nucleus is of a round and oval shape, in the basal row the shape may be fusiform. In the studied animal species, the cytoplasm of epithelial cells of the end sections and excretory ducts of the prostate gland is stained with oxyphilic.

The study of the mucous membrane of the prostatic section of the pelvic part of the urogenital canal in a silver-black fox and a blue fox shows that the membrane is lined with a multi-layered (up to 5 layers) epithelium with the inclusion of a multi-layered prismic epithelium. The nuclei of epithelial cells are mostly rounded in shape (Fig. 3).

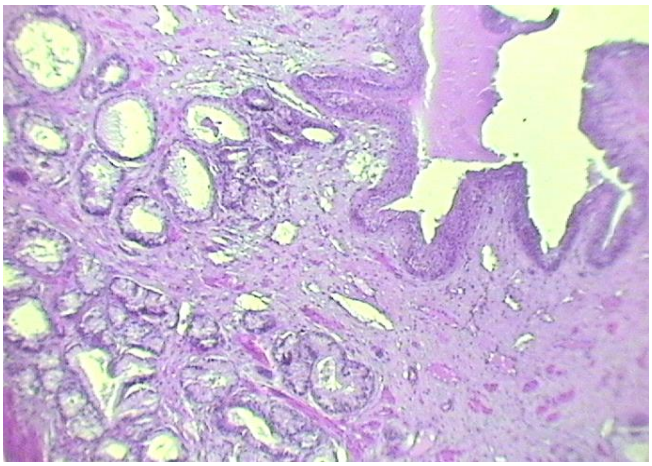

Fig. 3. The prostatic section of the pelvic part of the urogenital canal of a silver-black fox. It was stained with hematoxylin and eosin. Field lens 40, Field glass 15.

Sinusoidal capillaries filled with blood are located in the submucosa of the mucous membrane of the prostatic section of the pelvic part of the urogenital canal, and there are also arteries and large nerve bundles of the oval form. Most of the longitudinal and circular fibers of the muscular layer are interwoven with each other. At the both poles of the parietes of the prostatic section of the pelvic part of the urogenital canal there are vascular nerve tracts with well-marked nerve bundles (up to three in a silver-black fox and up to four in a blue fox). In addition, small nerve bundles are found in the serous membrane of the parietes of the urogenital canal.

The prostatic lumen of the pelvic part of the urogenital canal is of a fissured shape, the mucous membrane has numerous complex folds (Fig. 4).

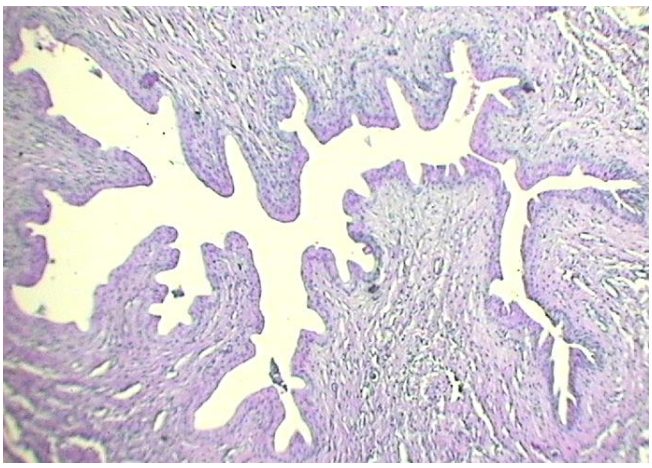

Fig. 4. The prostatic section of the pelvic part of the urogenital canal of a blue fox. It was stained with hematoxylin and eosin. Field lens 40, Field glass 15.

The urethral crest of the prostatic section of the pelvic part of the urogenital canal is very well developed, there is the seed tubercle here, into which the vas deferens flows into one mouth.

The intrinsic layer of the mucous membrane is represented by loose collagen fibers. Elastic fibers form the basis of the folds. In the submucosal base, elastic fibers located longitudinally and circularly are detected, the greatest concentration of which is observed in the seed tubercle. Here they are located predominantly circularly. In addition, the submucosa of the seed tubercle has a wide network of sinusoidally dilated capillaries forming a spongy layer (Fig. 5).

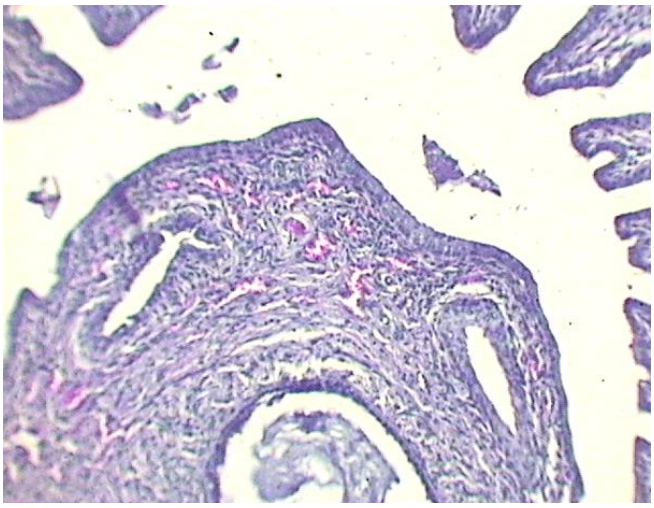

Fig. 5. The seed tubercle of a blue fox. It was stained with hematoxylin and eosin. Field lens 40, Field glass 15.

Obviously, such a structure provides the filling of the seminal tubercle with venous blood during sexual intercourse and the obstruction of the urogenital canal, thereby preventing the ingress of seminal fluid and sperm into the bladder during ejaculation.

The shape of the lumen of the prostatic section of the pelvic part of the urogenital canal, the different height of the epithelium of the mucous membrane allow us to assume that there is an epithelial sphincter in it. The findings of our research complement the research work of L.E. Etingen and D.B. Nikityuk [5], who believe that the main role of muscle fibers in the sphincter does not exclude the presence of other components, including the structure sinuosity of the mucous membrane, the folds of which usually change their configuration in the sphincter zones of hollow organs.

Previous studies have shown that the speed of urine passing through the urogenital canal depends not only on the contractile ability of the sphincter, but also on the state of the canal itself [8,12]. Under natural conditions, male silver-black foxes and blue foxes urinate in the same way as other predators. The urination can be done only with the help of the “sphincter system” mechanism, in which a significant role belongs to the layers of epithelium cells that have heterogeneous configuration and height [9]. Examining the groups of animals of the canine family, we found a positive moderate correlation between the height of the epithelium and the relative mass of the prostate gland (according to Pearson’s linear correlation coefficient R = 0.424 and R = 0.421 in a silver-black fox and blue fox, respectively) (Table II).

TABLE II. PARAMETERS OF THE PROSTATE GLAND AND THE PROSTATIC SECTION OF THE UROGENITAL CANAL, X ± SX

Parameters	Silver-black fox	Blue fox
Length of prostate gland, mm	9,21±0,56	10,43±0,67
Width of prostate gland, mm	6,62±0,36	7,81±0,28
Height of prostate gland, mm	5,03±0,48	5,72±0,58
Weight of prostate gland, mg	200±12	380±31

Weight of prostate gland, in relation to body weight, %	0,0056±0,0004	0,0091±0,0009
Height of epithelium of the prostatic section of the pelvic part of the urogenital canal, mcm	13,49±1,27	15,64±2,13
The differences between the indicators within the same group of animals are P <0.05		

Since the epithelial cells of the urogenital canal play the role of mechanical protection, in our opinion, the different height of the epithelial cells and the number of epithelial layers are the local protective and adaptive response of the body to the increase in the urine flow rate.

According to some authors [1,3,12], the collective excretory ducts opening into the prostate section of the pelvic part of the urogenital canal in some predatory and humans are lined with a prismatic multi-row epithelium. Large excretory ducts are lined with the transitional epithelium, which in its structure is identical to the epithelium of the prostatic section of the pelvic part of the urogenital canal. Our study does not confirm the presence of transitional epithelium in the collective ducts. In the silver fox and blue fox, the collective excretory ducts are lined with a cubic or prismatic epithelium, which confirms the findings of the research done on cats [9].

Analyzing the organization of the macro- and microstructure of the prostate gland and the prostatic section of the pelvic part of the urogenital canal in fur animals, and comparing our findings with the studies in some predatory and humans [1,6,8,12], we can establish similarities in their structure, but also significant differences. The prostate gland is an organ that is inextricably linked with the pelvic part of the urogenital canal. It forms a single organ complex along with its prostatic section of the pelvic part. In the lumen of the prostatic section of the pelvic part of the urogenital canal, the sperm is diluted with seminal fluid of the prostate gland. This secretion preserves the sperm from the aggressive factors of the environment and the internal environment of the female's genitals, contributing to successful fertilization.

The analysis of our findings and their comparison with the literature data suggest that the epithelium of the mucous membrane of the prostatic section of the pelvic part of the urogenital canal is a structure that actively protects the bladder from retrograde urine reflux when urinating, regardless of its volume and flow rate, as well as reflux of seminal fluid and sperm during sexual intercourse.

The findings are of particular interest for solving theoretical and practical problems in the field of morphology, diagnostics and treatment of diseases of the urinogenital organs in fur-bearing animals.

IV. Conclusion

Based on the literature data and our findings, we argue that the epithelium of the mucous membrane of the prostatic section of the pelvic part of the urogenital canal in a silver-black fox and a blue fox is represented by a multi-layered transitional epithelium, which is different due to the epithelial cell size. The mucous membrane has numerous complex folds which form a fissured shape of the urogenital canal. The longitudinal and circular fibers of the muscular layer of the prostatic section of the pelvic part of the urogenital canal are interwoven with each other.

On the top of the seed tubercle, the seed tubes open into the thickness of the prostatic section of the pelvic part of the urogenital canal. The seed tubes penetrate into it from the vesicular margin of the prostate gland.

In the prostatic section of the pelvic part of the urogenital canal, the epithelium is multi-layered transitional with the inclusion of multi-layered prismatic epithelium. The mucous membrane in the prostatic section of the pelvic part of the urogenital canal is characterized by complex folding. This folding depends on the height of the epithelial layer and the number of prostatic ducts opening into the lumen of the urinary tract.

Thus, our findings on the morphology of the prostate gland of the urogenital canal in fur animals of the canine family correspond to the basic laws of the structure of tubular organs, which are complex biological systems in terms of functioning and morphology.

References

[1] D.W. Anderson, G.B. Anderson, Atlas of canine anatomy, Philadelphia, pp. 790-815, 1994.

[2] G.G. Avtandilov, Medical Morphometry: a Guide, M, Medicine, 384 p., 1990.

[3] M.B. Bharadway, M.L. Calhoun, “Histology of the urethral epithelium of domestic animals,” Am. J. Vet. Res., No 20, p. 231, 1952.

[4] W.A. Bloom, A textbook of histology. 9 ed. Fhiladelphia, Toronto,.pp. 27-49, 1968.

[5] L.E. Etingen, D.B. Nikityuk, “Some Structural and Functional Criteria for the Organization of Hollow Internal Sphincter Organs,” Morphology, Vol. 115, No. 1, pp. 7-10, 1999.

[6] J. Frewein, B. Vollmerhaus, Anatomie von Hund und Katze, Berlin, 460 p., 1994.

[7] V.I. Kirpatovsky, I.V. Kabanova, I.S. Mudraya, Bladder and Prostate Gland. Unified Anatomical and Functional Complex, Saarbrücken, Lap Lambert, 134 p., 2017.

[8] A. Kretschmer, R.M. Bauer, T. Hüsch, A. Haferkamp, F. Thomsen, D. Kronlachner, A. Obaje, R. Anding, T. Pottek, A. Rose, R. Olianas, A. Friedl, W. Hübner, R. Homberg, J. Pfitzenmaier, F. Queissert, C.M. Naumann, C. Wotzka, T. Hofmann, R. Seiler et al., “Targeting moderate and severe male stress urinary incontinence with adjustable male slings and the perineal artificial urinary sphincter: focus on perioperative complications and device explantations,” International Neurourology Journal, Vol. 21, No 2, pp. 109-115, 2017.

[9] S.F. Meleshkov, “Structural Features of Urethral Mucosa in the Domestic Cat,” Agrarian Bulletin of the Urals, Vol. 9 (51), pp. 79-83, 2008.

[10] A.P.Popov, Structural and Functional Bases of Veterinary Andrology: Monograph, Ulan-Ude, FGOU BGSHA, pp. 249-263, 2004.

[11] O.A. Suarez, K.A. McCammon, “The artificial urinary sphincter in the management of incontinence,” Urology, Vol. 92, pp. 14-19. 2016.

[12] A.G. Zernova, “Features of the Structure of Sphincter Apparatus of Visceral Smooth Muscle Tissue in Various Organs,” Morphological features of the muscular system: Collection of Interregion, Scientific-Practical Conf. of Students, Graduate Students and Young Scientists, Rostov-on-Don, pp. 83-90, 2018.