ATLANTIS PRESS
Advances in Health Sciences Research, volume 16
International Conference on Health and Well-Being in Modern Society (ICHW 2019)

The Effect of Different Doses of Molybdenum on the Functional State of the Digestive System

Sherkhov Z.Kh.
Faculty of Medicine
Kabardino-Balkaria State University n.a. Kh.M. Berbekov
Nalchik, Russia
zsherhov@mail.ru

Khandokhov T.Kh.
Institute of Chemistry and Biology
Kabardino-Balkaria State University n.a Kh.M. Berbekov
Nalchik, Russia
handohovv@mail.ru

Voynov V.B.
Research Technology Neurotechnology Center
South Federal University
Rostov, Russia
vvoynov@sfedu.ru

Molov A.A.
Faculty of Medicine
Kabardino-Balkaria State University n.a. Kh.M. Berbekov
Nalchik, Russia
zsherhov@mail.ru

Sherkhova L.K.
Institute of Chemistry and Biology
Kabardino-Balkaria State University n.a Kh.M. Berbekov
Nalchik, Russia
saratoga_l@mail.ru

Shavaeva F.V.
Faculty of Medicine
Kabardino-Balkaria State University n.a. Kh.M. Berbekov
Nalchik, Russia
zsherhov@mail.ru

Shkhagumov K.Yu.
Faculty of Medicine
Kabardino-Balkaria State University n.a. Kh.M. Berbekov
Nalchik, Russia
handohovv@mail.ru

***Abstract* – The effect of molybdenum production wastes on the structure and functions of the digestive organs of forest mice (Apodemus silvaticus) was studied. The small intestine, liver, and pancreas were studied. In intestines, the signs of chronic enteritis are predominant, adhesions of the apical portions of the villi and hyperplasia of the lymphoid tissue are observed. In the acinar cells of the pancreas, the content of nucleic acids is reduced. Damage to the central part of the insular apparatus and impaired blood supply in the endocrine pancreas of both groups are observed. Hepatocyte hypertrophy, an increase in the number of binuclear and polyploid cells, expansion of the central veins and lymphoid infiltration are observed. Molybdenum content in the liver tissue is high. Summarizing the data obtained, it can be concluded that molybdenum in physiological doses has a beneficial effect on metabolism of cells and tissues of the intestine, pancreas and liver. Increased concentration above the physiological norm causes pathological changes.**

Keywords – molybdenum, pancreas, lymphoid tissue, nucleic acids, liver tissue

I. INTRODUCTION

Any organism, from protozoa to higher mammals, develops in a specific biogeochemical environment whose composition determines the development, functions and ecological features of the organisms. The significance of the geochemical environment for the development of organisms and evolution of life is determined by participation of chemical elements in metabolic processes and their entry into the composition of biologically active compounds [1–4]. The doctrine of the relationship between the chemical elemental composition of the body and the chemical composition of the earth crust was developed by Academician V.I. Vernadskiy. He found that the process of migration through plant and animal organisms is typical of most of the chemical elements [1, 5].

Anthropogenic biogeochemical provinces develop in a short time, and consequences of their impact on living organisms are unpredictable. In this regard, it seems relevant to assess multifactorial processes, as well as create scientific foundations of new technologies to protect organisms from harmful anthropogenic impact [1, 3, 5, 6].

Trace elements are an essential component of many industrial wastes. Being structural components of enzymes and hormones, they are involved in metabolism [1, 7, 8, 9]. Their imbalance in food affects biochemical reactions. Therefore, the accumulation of trace elements in technogenic biogeochemical provinces, their prolonged effect on the flora and fauna cause diseases or create the background for other diseases.

This work is relevant especially for the regions of the Russian Federation where there are biogeochemical provinces lacking (of natural type) and having an excessive amount of molybdenum (of anthropogenic type).

The purpose of this work is to study the effect of different doses of molybdenum on the morphophysiological state of the digestive organs of forest mice (Apodemus silvaticus).

II. METHODS AND MATERIALS

The following methods were used: polarographic, spectrographic, biochemical, enzyme immunoassay, histological and mathematical analyses. The use of these methods increased representativeness and accuracy of the results of the work.

III. RESULTS

The choice of the studied organs (small intestine, liver, pancreas) is due to the fact that the main place of absorption of trace elements, including molybdenum, is the small intestine. All these bodies have a common source of development and are interconnected functionally. Normally, their activity is aimed at providing the body with nutrients, macro- and microelements, they are involved in the pathological process. Therefore, to understand the mechanism of influence and methods for correcting the damaging effect of excess molybdenum on the body, a comprehensive study of the morphological physiology of the intestine, pancreas and liver is required.

In forest mice, signs of chronic enteritis predominate in the intestines. Villi are thickened and shortened, sometimes atrophied, adhesions of apical portions of villi, hyperplasia of lymphoid tissue are observed.

Histological examination of the pancreas in experimental rats and forest mice from contaminated areas shows signs of suppression of its activity. The basophilicity of acinocytes is reduced, zymogen granules are insignificant. There are foci of necrosis, minor hemorrhages and lymphoid infiltration. The obtained data are consistent with previous studies [10].

The content of nucleic acids in acinar cells and the amylolytic activity of the extract are significantly reduced, which indicates suppression of the synthesis of enzymes and protein (Table 1).

In the glandular tissue, the concentration of molybdenum is greater, and the amount of oxygen is less than in the control group (Table 2).

In the endocrine pancreas of both groups, damages to the central part of the insular apparatus and disturbed blood supply are observed. The content of glucose and uric acid in the plasma increases (Table 3).

The higher the functional state of the gland, the more pronounced the basophilicity is. The content of nucleic acids is also associated with the functional state [10]. Determination of the content of nucleic acids is a fairly accurate criterion for assessing the synthesis of enzymes of the gland. On drug sections, it is clear that the oxyphilic and basophil zones are moderate. The nucleus in the acinocyte is shifted to the basal part, and this part of the cell has pronounced basophilia. Enzyme synthesis occurs, and zymogen granules which fill the apical part of the cell are formed. In the control group of mice, the zymogen zone is packed with large granules, which indicates the active synthesis of enzymes.

In the lumen of some acini, centroacinar cells belonging to the initial section of the ductal system are visible. Among the acini there are intercalated excretory ducts. The walls of these ducts are lined with cubic epithelium. It is believed that these cells synthesize the liquid component of pancreatic juice. When reviewing micropreparations in the interlayer of connective tissue, there are vessels and interlobular excretory ducts. It has been established that the epithelium of the interlobular ducts contains endocrinocytes that produce pancreozymin-holitsistokinin, which is involved in the regulation of the secretory function of the endocrine pancreas.

TABLE I. CONTENT OF NUCLEIC ACIDS IN ACINE CYTES AND AMYLOLYTIC ACTIVITY OF PANCREATIC INFUSION OF EXPERIMENTAL RATS AND FOREST MICE FROM THE TERRITORY OF NHMP (N=30)

	Rats		**Mice**	
	Control	***TVMK***	***Control***	***NHMP***
The content of nucleic acids (cu)	0.14±0.002	0.08±0.0002 p<0.001	0.20±0.006	0.13±0.003 p<0.001
Amylolytic activity (% of glucose)	5.0±0.01	2.5±0.05 p<0.001	5.3±0.02	2.7±0.001 p<0.001

TABLE II. CONTENTS OF MOLYBDEN AND OXYGEN IN THE PANCREATIC GLAND OF EXPERIMENTAL RATS AND FOREST MICE FROM THE TERRITORY OF NHMP (N=30)

	Rats		**Mice**	
	Control	***TVMK 0,042 mg/kg***	***Control***	***NHMP***
Mo (mg%)	0.0010±0.0001	0.0020±0.0003 p<0.001	0.0015±0.0005	0.0038±0.0002 p<0.001
PO2 (mm)	40.0±0.9	32.4±2.4 p<0.001	43.1±0.4	33.0±0.7 p<0.001

TABLE III. CONTENT OF GLUCOSE AND URIC ACID IN BLOOD PLASMA OF EXPERIMENTAL RATS AND FOREST MICE FROM THE TERRITORY OF NHMP (N=30)

Indicators	**Rats**		**Mice**	
	Control	***TVMK 0,042 mg/kg***	***Control***	***NHMP***
Glucose (mmol/l)	5.16±0.014	9.21±0.43 p<0.001	5.25±0,13	8.15±0.15 p<0.001
Uric acid (mmol / l)	1.69±0.05	6.88±0.05 p<0.001	2.62±0,07	5.50±0.03 p<0.001

To assess the functional state of the pancreas of a forest mouse from the territory of NHMP, we used the same criteria. While reviewing the micropreparations, we paid attention to vascularization, development of connective tissue formations, and the number and size of the islets of Langerhans. The plethora of the body as a whole is of interest; blood stasis is observed in the capillaries and in the venous vessels. There are hemorrhages.

We believe that morphofunctional disorders of the gland are caused by a shortage of interstitial hormones due to damage to the intestinal mucosa under the influence of high doses of molybdenum. Damage to the insular apparatus is caused by a significant increase in the uric acid content in the plasma due to increased activation of xanthine oxidase with an excess of molybdenum. Uric acid lowers the B cells of the islets. Thus, concentration of molybdenum in the polluted environment is a diabetic agent.

The histostructure of the liver of the control group of animals. The analysis of microscopic preparations showed that the liver structure of these animals has a typical structure characteristic of mammals. Interlayers of connective tissues are more pronounced in the locations of the triads. The parenchyma of the liver has no pathological features.

In the liver of experimental rats and mice, hypertrophy of hepatocytes, an increase in the number of binuclear cells up to 25 %, and of polyploid cells up to 66 %, expansion of the central veins and lymphoid infiltration are observed. Small-drop fatty dystrophy is observed. The content of molybdenum in the liver tissue is increased, the content of glycogen and oxygen is reduced (Table 4).

TABLE IV. CONTENTS OF MOLYBDEN, OXYGEN, AND GLYCOGEN IN THE LIVER OF EXPERIMENTAL RATS AND FOREST MICE FROM THE TERRITORY OF NHMP (N=30)

	Rats		**Mice**	
	Control	***TVMK 0,042 mg/kg***	***Control***	***NHMP***
Glycogen (%)	3.90±0.02	2.5±0.03 p<0.001	4.21±0.01	1.03±0.02 p<0.001
Molybdenum (mg%)	0.023±0.02	0.133±0.0007 p<0.001	0.019±0.0003	0.061±0.0002 p<0.001
PO2 (mm)	52.2±0.30	41.3±0.60 p<0.001	53.0±0.80	39.3±0.60 p<0.001

When studying microscopic preparations of the liver of forest mice from the territory of NHMP, considerable hypertrophy of hepatocytes and the pycnotism of the nuclei are of interest. Hydrotopic dystrophy is observed in the liver during intoxication. Destructive changes in the nucleus and cytoplasm are observed in the center of the lobules, around the central vein. Violations in the location of the beams and expansion of blood vessels are not observed (Figure 1).

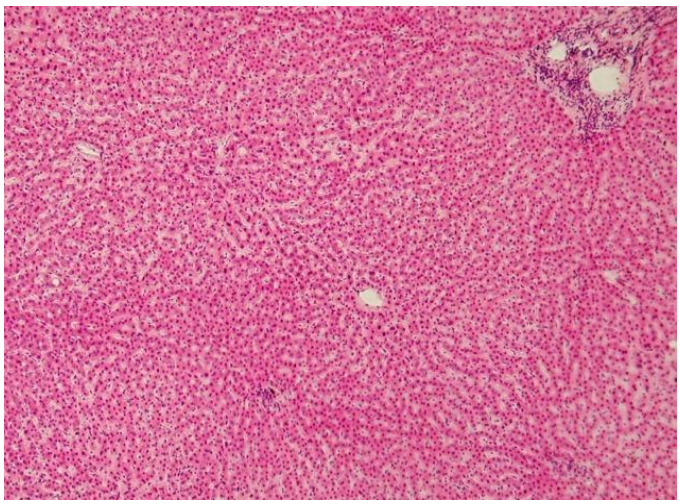

Fig. 1. Histological structure of the liver in control animals. (8x10)

A review of the microscopic specimens of the liver of experimental rats showed that the toxic dose of molybdenum causes a multilateral lesion of the organ. They concern both the parenchyma and the vascular system of the gland. In almost all rats receiving a toxic dose of molybdenum, venous plethora is observed. The walls of the veins and arteries are thinned, and the lumen is enlarged. In some individuals, sinusoidal hemocapillaries are significantly enlarged, filled with blood, microbleeds occur (Figure 2).

When treating with black sudan, in the cytoplasm of hepatocytes small droplets of fat were found. The number of dual-core and cells with a polyploid nucleus is sharply increased, which indicates the functional stress of hepatocytes.

Some hepatocytes have nuclear pycnosis and karyolysis. Along the edge of the hepatic lobules, there were areas with disturbed location of hepatocytes, and sometimes with extensive hemorrhage (Figure 2).

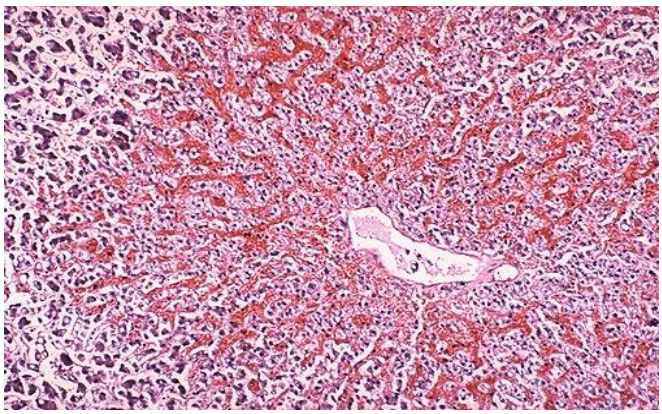

Fig. 2. Histological structure of the liver in animals intoxicated by molybdenum. (8x10)

Figure 3 shows the histological structure of the hepatic lobule of a rat of the same experimental group.

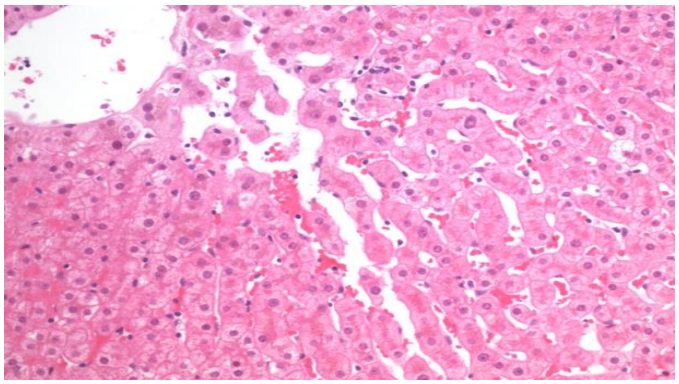

Fig. 3. The histological structure of the hepatic lobule of rats subject to a toxic dose of molybdenum (8x40)

In the left corner of Figure 3, there is a segment of the lobule with hepatic beams with normally located hepatocytes, the lumen of sinusoids is expanded. In the central part of the figure, there is a segment of the lobule, where the center of necrosis is clearly visible to trace all the stages of this process: paranecrosis, necrobiosis and autolysis. The structure of the liver gutters, especially close to the central vein, is destroyed. Under pathological conditions of the liver, the central part of the lobule which receives mixed blood where the oxygen concentration is lower, is the first to suffer. In most hepatocytes, the nuclei are characterized by size variability, hepatocytes in karyopicnosis, a large number of nuclear-free cells with karyolysis. Most of the hepatocytes poorly perceive dyes, cell contours are not distinct. Between the liver beams, there are small lymphoid infiltration and microchromosomes.

Structural changes are observed in the parenchyma of the organ. These changes are focal. Figure 2 shows the structure of the liver girders. The nuclei of hepatocytes are shriveled due to chromatin condensation (karyopynosis). In some cells, there is karyorexis (disintegration into clumps). In the area of the central vein, there is a small focus of connective tissue growth.

Lymphoid infiltration indicates the presence of foci of necrosis and connective tissue degeneration of individual sections of the liver. This is a protective reaction of liver tissue in local foci of inflammation. Subsequently, these foci are replaced by connective tissues and cease to perform the functions of hepatocytes. Morphometric measurements showed changes in the ratio of various types of hepatocytes in the parenchyma of the organ.

During molybdenum intoxication, POL processes are intensified, the amount of ROS increases. When the mechanisms of antiradical protection become disrupted, oxidative stress at the cellular, tissue and organ levels develop. At the same time, increased lipid peroxidation and excessive production of organic peroxides cause pathological processes.

IV. Conclusion

Thus, it is clear that molybdenum is directly involved in metabolism of cells and tissues of the intestine, pancreas and liver. Within physiological doses, it has a beneficial effect on the functional state of the organs. The increased content of molybdenum causes various kinds of pathological morphophysiological changes. A decrease in the amount of oxygen up to 70 % from the initial level observed during the experiments indicates significant changes in energy production regimes and energy consumption of cells and tissues.

References

[1] A.P. Avtsyn, A.A. Zhavoronkov, M.A. Rish, L.S. Strochkova, Human trace elements. Moscow, 1991, pp. 231–237.

[2] A.R. Gutnikova, K.O. Makhmudov, B.A. Saidkhanov et al., “On the membranotropic effect of heavy metal salts and main ways of its correction”, Toxicolog. Bull., no. 3, pp. 21–26, 2009.

[3] B.A. Katsnelson, O.G. Makeev, T.D. Degtyarev et al., “Experimental testing of biological defense agents against the carcinogenic action of ecotoxins”, Toxicolog. Bull., no. 3, pp. 15–20, 2007.

[4] L.P. Kuzmina, N.I. Izmerova, T.B. Burmistrova et al., “Pathomorphosis of Modern Forms of Occupational Diseases”, Occupational Med. and Industr. Ecol., no. 6, pp. 18–24, 2008.

[5] Ermakov V.V. “Problems and prospects for the development of the study of biogeochemical provinces”, Trace elements in biology and their application in agriculture and medicine: Abstracts of Reports of the XI All-Union. Conf., Samarkand, pp. 22–25, 1990. [Trace elements in biology and their application in agriculture and medicine: Proc. reports XI All-Union. Conf., Samarkand, 1990. 556 p.].

[6] V.I. Makarova, A.I. Makarov, “The role of cytokines in the implementation of the inflammatory response”, Human Ecology, no. 5, pp. 31–35, 2008.

[7] O.V. Savchenko, P.A. Tyupeleev, “Features of the microelement status in children living in areas of the city with varying degrees of environmental pollution”, Human Ecology, no. 1, pp. 47–50, 2009.

[8] S.A. Syurin, A.A. Derevoedov, A.N. Nikapov, “Bronchopulmonary pathology among workers employed in underground mining of copper-nickel ore”, Hygiene and Sanitation, 2008, no. 3, pp. 27–29.

[9] Kh.I. Sherkhova, Structural and functional changes in the digestive organs under the action of molybdenum. Nalchik, 1999, 157 p.

[10] Report on the implementation of the 1st stage of the State Contract No. P710 of August 12, 2009. project No. NK-124P “Investigation of the effect of molybdenum on the morphofunctional parameters of the life support systems of the human body and animals”. Nalchik, 2009, 210 p.

[11] M. Young, The Technical Writer’s Handbook. Mill Valley: University Science, 1989.