

Development of Drugs for Treatment of Mortellaro's Disease in Cattle

Natalya Belyakova

Department of Infectious and Invasive Pathology Belgorod State Agricultural Academy

pos. Mayskiy, Russia

belyakovanatalya2018@gmail.com

Anatoliy Kovalenko

Department of Infectious and Invasive Pathology Belgorod State Agricultural Academy

pos. Mayskiy, Russia

mycobacteria@rambler.ru

Yuliya Bodrova

Department of Infectious and Invasive Pathology Belgorod State Agricultural Academy

pos. Mayskiy, Russia

bodrova95@mail.ru

Abstract—The root cause of premature culling of animals from the herd as a result of diseases and injuries is a lesion of distal portions of limbs of an infectious etiology, which include Mortellaro's disease. Mortellaro's disease affects up to 60 percent of the cattle in Russia.

BelNano was developed, consisting of liposomal fractions and nanoparticles of silver and copper distributed in its volume. The surface of the nanoparticles has been specially modified to provide high efficiency on the skin and keratinized tissues.

Pathogens that were found in impression smear and *Fusobacterium necrophorum*, *Treponema*, *Borellia* grown on nutrient media, which were sensitive to the active components of the BelNANO, ensuring their inactivation by action on the cell wall were revealed in the studied animals with Mortellaro's disease. In experiments on the study of effectiveness of the BelNANO for the prevention and treatment of skin and skin coverings of the distal portion of limbs in Mortellaro's disease, 89 percent therapeutic efficacy was established, providing not only a high bactericidal and bacteriostatic effect on infectious agents, but also high regenerative properties of the drug, expressed in epithelization and the appearance of granulation tissue.

Keywords—skin and skin lesions, Mortellaro's disease, Cu and Ag nanoparticles, lameness, drug for the treatment of interdigital cleft, cattle

I. INTRODUCTION

Under the conditions of production intensification of dairy farms, the percentage of injuries of the distal portions of limbs increases sharply, which contributes to the emergence of infectious diseases as a result of the appearance of the portal of entry for infection [1].

With modern technologies for keeping dairy cows, this is facilitated by highly concentrated feeding, leading to acidosis, and as a result to an increase in the permeability of the skin, laminitis, a decrease in the overall resistance of the animal organism, which entails the emergence of various diseases, among which the leading place takes Mortellaro's disease, the primary sign of which is lameness[2].

Initially, the behavioral characteristics of animals and the manifestation level of lameness of varying degrees, as well as the affection of the distal portion of limbs in Mortellaro's

disease were studied by Shpreher D. et al.(1997) and Dopfer D. et al. (1997) [3].

Shpreher D. classification (1997) is based on indicators of back bending and position of limbs and allows us to assess the severity of the disease [4].

At the same time, the author evaluated the state (walking score 1) in animals (walking score 1) - the norm - in the absence of a back bending and position of limbs in a standing position and when walking, the steps in these animals are long and sure. In case of mild lameness (walking score 2) in a standing position the cow has a straight back, but when walking there is a slight bend, the gait is slightly impaired. In case of moderate lameness (walking score 3) both in a standing position and when moving the cow appears to have a back bending. The animal makes short, faltering steps with one or more limbs; a descent limb opposite to the sick may be observed. Lameness (score 4) is described when an animal tries not to step on a sick limb, but occasionally makes a step with it, a back bending is always present. The descensus of the ungulate processes of the limb, opposite to the sick, is pronounced. Acute lameness (walking score 5) is determined in animals with a pronounced back bending and complete absence of support on the sick limb when walking and in a standing position.

Dopfer D. classification divides the disease into 4 different stages (M1 – M4) [5]. This classification describes the degree of manifestation of the disease. M1 – small changes with a red or white-red surface, exudation is possible. The epithelium may be retained or damaged. M2 – "classic ulceration", red or white-red lesions with a diameter of more than 1 cm. On the surface of the lesion, granulation or proliferative tissue (in large numbers or filamentously) is observed. M3 – healing lesions with a black squarrous surface. M4 – skin changes causing a suspicion of IDD (infectious digital dermatitis), as well as a proliferative form. Later, DöpferD. adds another stage of IDD – M4.1, which is characterized by the development of a new lesion of M1 in the chronic process of M4. The stages of the disease do not remain unchanged over time. There is a constant transition from stage to stage under the influence of various external factors. The most frequent transition is observed between the stages M2 – M4; there are also less logical transitions: M3 - M0, M0 - M2 and M0 - M3. Different stages of IDD on different limbs may also be observed.

Also, Manske et al. (2002) and Kozii V. (2005) have been worked on the classification of lesions in Mortellaro's disease [6, 7]. This infectious disease accompanied by lesion of the skin and skin covering of the distal portions of limbs is widespread in many countries of Europe and Russia and is may affect a large number of highly productive dairy cattle (Cheli R. E., Mortellaro C., 1974).

When defining Mortellaro's disease, it should be noted that this infectious disease is highly contagious, causing focal lesions on one or both hind limbs in cattle, which are extremely painful, causing lameness in animal, resulting in reduced milk yield and reproductive ability. In most cases, lesions are localized on the arch of the interdigital cleft at the level of the heel of the hooves, as well as on the inner surface of the interdigital cleft [8].

Lesions are ulcerative-necrotic surfaces, with exudate discharge, having a concave appearance, red in color, smooth, sometimes fine-grained, resembling the appearance of strawberries. In most cases, overgrown wool is observed around the damaged area, often glued with exudate. The diameter of the affected areas varies from a few millimeters to 10 cm [9].

According to most researchers, spirochetes of the genus *Treponema* spp. [10-12], *Borrelia* spp. [13], as well as *Fusobacterium necrophorum* play a leading role in the etiology of the disease [14-16].

In addition to the above mentioned microorganisms, staphylococci, streptococci and some conditionally pathogenic microorganisms were isolated by most researchers [1].

Technological, economic and environmental factors play a significant role in the spreading and course of Mortellaro's disease [17-19].

Mortellaro's disease is a factorial infectious disease, the development and course of which depends on the feeding, management and immune status of the animal, which determines the susceptibility of animals to this disease and the nature of the course of the infectious process [20-22].

Various methods and agents are used to treat Mortellaro's disease, including antibiotic therapy both parenterally and topically with localization of the effect on the skin, using aerosols and sprays, as well as antiseptic agents — disinfecting hoof baths using antibiotics, solutions of copper sulfate, formalin, etc. [23,24].

Currently, in dairy cattle breeding of most of the highly developed countries there is no definite opinion on the existence of a commonly accepted methodology and a single agent for the prevention and treatment of Mortellaro's disease, as data on the effectiveness of drugs used by pharmaceutical companies both in Europe and the USA (Solka, hoof skin) are varying [25].

Thus, there is a need to develop a domestic therapeutic and prophylactic agent that can be used to control Mortellaro's disease.

At the same time, with the development of nanotechnology and the use of nanomaterials, a large number of publications appear confirming the high therapeutic

efficacy of metals in the nanocrystalline state (Jose Ruben Morones et al. 2005) [26].

All of the above, as well as the previously developed direction for the design of agents to control Mortellaro's disease, prompted us to develop and test a new innovative highly effective therapeutic and prophylactic agent based on copper (Cu) and silver (Ag) nanoparticles embedded in liposome fractions for treatment and prevention of cows with lesions of skin and skin coverings of the distal portions of limbs developing in Mortellaro's disease.

II. EXPERIMENTAL

The study of the clinical manifestations of lesions of the skin and skin coverings of the distal portions of limbs in Mortellaro's disease was carried out directly in settings of a dysfunctional farming for diseases of the distal portions of limbs of cattle. A clinical assessment of the intensity of lesions in Mortellaro's disease was performed according to the classification proposed by Döpfer D et al.,(1997)[3].

We have studied the antigenic composition of pathogens at the sites of ulcerative lesions of the interdigital cleft and coronet, causing the development of Mortellaro's disease, taking samples of punctate and conducting bacteriological studies.

Stabilized silver and copper nanoparticles were used in combination with liposomal fractions to prepare antiseptic and wound healing agent BelNANO in the settings of M9, LLC (Tolyatti), which can have a high therapeutic effect in treating cows with lesions of the distal portions of limbs inherent in Mortellaro's disease, manifested by lesions of the skin and skin coverings of the distal portions of limbs.

An experimental sample of the BelNano was prepared, consisting of a liposome fraction and silver and copper nanoparticles distributed in its volume. Silver and copper particles were obtained by one of the sol-gel methods, namely the hydrosol method, using universal laboratory equipment. The method consists in preparing an aqueous solution of a reducing agent in an aqueous solution of a stabilizer and introducing a metal salt into the solution of a reducing agent.

Quercetin with a concentration of $1 \cdot 10^{-3}$ to $14 \cdot 10^{-3}$ mol/liter in its deprotonated form with a molar ratio of quercetin to ammonia in the range of 1:3-1:10 was used as a reducing agent, while the oxidized form of quercetin acts as a nanoparticle stabilizer.

The concentrations of the additional stabilizing substance varied from $1 \cdot 10^{-3}$ to $5 \cdot 10^{-3}$ mol/liter; silver and copper nitrates were used as metal salts. The concentration of nanoparticles in the resulting solution ranged from 500 ppm to 2500 ppm.

Following stabilization of the nanoparticles, their surface was specially modified to ensure high efficiency on the skin and keratinized tissues. The final concentration of silver and copper metals in liposome fractions was 15 mg/L.

New approaches to active substances with high bactericidal properties in low concentrations and deep penetration not only into the surface layers of epithelial tissue, but also into the subcutaneous tissue were used to develop a drug for the treatment and prevention of diseases of the distal portions of limbs.

This is due to the fact that the silver and copper nanoparticles included in the drug have a special molecular coating – liposomal fractions, which have adsorbing properties and rapid penetration into the deep layers of the epidermis and subcutaneous tissue, which can remain for a long time in the tissues and provide a long-term prolonged therapeutic effect.¹

A new dosage form of an antiseptic wound healing drug for external use in diseases of the distal portions of limbs (Mortellaro's disease) has been developed, which has not previously been used in veterinary medicine, based on nanotechnology. Copper and silver nanoparticles were embedded in the liposome fractions of the finished dosage form.

To isolate pathogens from sick animals with Mortellaro's disease, punctate was taken from the skin and skin coverings of the interdigital cleft and microscopic studies of impression smears were carried out with further plating of homogenates on BSK-II, MIB (meat infusion broth), MIA (meat infusion agar) culture media.

Cultural-morphological, biological studies of isolated cultures of microorganisms were carried out. The resulting cultures were applied to a glass slide and stained according to Romanovsky-Giemsa and Gram methods.

Silver and copper nanoparticles were obtained using a chemical reactor (M-9, LLC, Samara), followed by the preparation of a liposomal oil form.

Solutions of various concentrations with silver and copper nanoparticles were used to conduct studies. The total concentration of metals was 15.0 mg/kg.

Experimental and control groups of animals with Mortellaro's disease were formed (Table I).

As a pure control, 20 animals were taken in which lesions of the interdigital cleft characteristic of Mortellaro's disease

were found, for which no treatment was used after hygienic treatment of the hooves.

Animals of control group 1 in the amount of 20 animals, also having lesions of skin and skin coverings of the interdigital cleft and coronet, characteristic of Mortellaro's disease, were run through hooved baths containing 10% copper sulfate, with a frequency of 2 times a day throughout the study period.

For experimental group of cows No. 1 (n = 40), with M1 lesions according to the classification of DöpferD.e (1997) [3], a sample of the drug with a concentration of 15 mg/L of silver and copper metals in the gel was applied once after clearing and hygienic treatment of the hooves.

On the affected areas of the skin and skin coverings of the lactating cows of experimental group No. 2 (n = 29) - with M2 lesions, the experimental sample of the BelNano was applied twice with an interval of 3 days.

The drug was also applied twice to animals of experimental group No. 3 (n = 59) with M3 lesions.

On cows of experimental group No. 4 (n = 21) with M4 lesions, the BelNano sample was used once after orthopedic clearing and hygienic treatment of hooves.

For cows of all experimental groups, a standard gauze bandage with preliminary application of parchment paper to the gel surface was used to fix the used drug.

Following 3rd and 7th days, the affected areas of the skin and skin coverings were examined and the therapeutic effectiveness of the BelNano was evaluated according to the degree of healing.

III. RESULTS AND DISCUSSION

Dimensionality of silver and copper nanoparticles, which were in the finished solution with liposome fractions, ranged from 12 to 30 nm (Fig. 1, 2).

TABLE I. METHODS OF FORMING EXPERIMENTAL GROUPS OF ANIMALS FOR RESEARCH

Group of animals	Number of animal units (n/ level of prevalence according to DopferD.e.)	Clearing the hooves	Single use of the NanoBel	NanoBelwas used twice
Pure control	20/ M1 - 7, M2 - 6, M3-4, M4 - 3	+	-	-
Control 1	20 /M1 - 14, M2-4, M3-2, M4 - 0	+	- baths of a 10% aqueous solution of copper sulfate	
Experimental No.1	40	+	+	-
Experimental No.2	29	+	+	+
Experimental No.3	59	+	+	+
Experimental No.4	21	+	+	-

^a. Experimental group No. 1 - animals with lesions M1, experimental group No. 2 - M2, experimental

^b. group No. 3 - M3, experimental group No. 4 - M4, according to the classification of DöpferD.e (1997)

¹ The work was performed on the basis of the Department of Infectious and Invasive Pathology, the Laboratory of Infectious and Invasive Pathologies and Approbation of Veterinary Drug Products of Belgorod State Agricultural University named after V.Ya. Gorin and M9, LLC (Tolyatti). Scientific

and production experiments were carried out on the basis of livestock farming Butovo-Agro, LLC of Yakovlevsky district of Belgorod region.




Fig. 1. The sizes of Ag nanoparticles obtained by the method of hydrosols, according to the results of TEM (transmission electron microscopy).

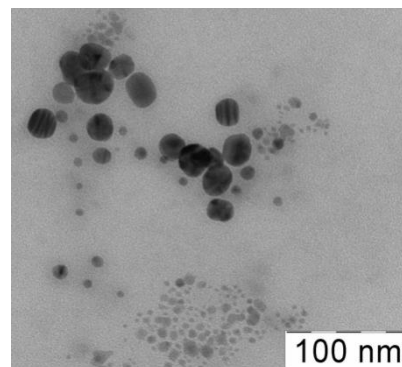


Fig. 2. The sizes of Cu nanoparticles obtained by the method of hydrosols, according to the results of TEM (transmission electron microscopy).

The main difference between the developed drug and existing analogues is the presence of metals in crystalline form, included in the liposomal substance. These extremely small crystals penetrate effectively into the deep layers of the skin and subcutaneous tissue, acting in the focus of inflammation and effectively inactivating conditionally pathogenic and pathogenic microorganisms, including infection pathogens.

The effectiveness of the experimental sample of the Bel-NANO was studied in Butovo-Agro, LLC of Yakovlevsky District, Belgorod Region, on cattle imported from the Netherlands.

As a result of microscopic studies of impression smears obtained from the affected areas of the interdigital cleft of cows with Mortellar's disease, it was found that in most samples stained according to Gram and Romanovsky - Giemsa, rods of different thickness and length were observed in the field of view in the form of thin long threads corresponding to those of *Fusobacterium necrophorum* (Fig. 3), also the spiral-shaped forms of *Treponema* spp., stained in a pale pink color (Fig. 4), and twisted spiral-shaped threads of *Borrelia* spp. of purple color.

On the MIB medium, the culture of *Fusobacterium necrophorum* showed visible growth after 24-48 hours, causing intense turbidity of the lower layer firstly, and of the entire medium later. Very weak gas formation was noted during the first hours of the observed growth. After 5-8 days,

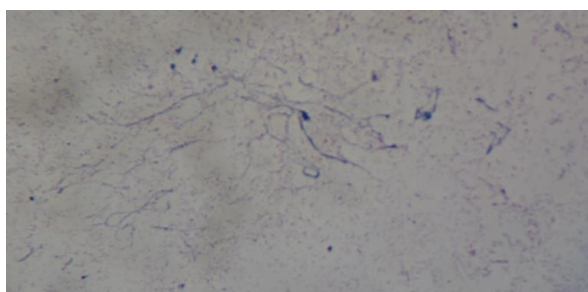


Fig. 3. Appearance of *Fusobacterium necrophorum* in an impression smear under a light microscope.

broth bleaching was observed with the appearance of powdery cloud-like sediments.

When homogenate obtained from the punctate of the interdigital cleft was plated on BSK-II medium, a change in the color of the medium to yellow and its turbidity was observed for 12 days, which indicated bacterial contamination of *Borrelia* spp., the culture formed aggregates in the form of loose white lumps at the bottom of the tube, which over time were evenly distributed in the medium. (Fig. 5).

During the conduct of microscopic studies of cultures of microorganisms isolated from BSK-II, MIB and MIA media, after staining according to Gram and Romanovsky-Giemsa, the presence of Mortellar's disease pathogens was established: *Fusobacterium necrophorum*, *Treponema* spp., *Borrelia* spp.

During the experiments, the investigations were conducted to study the overall incidence of Mortellar's disease throughout the herd of lactating cows before the 3rd lactation. The incidence of animals with Mortellar's disease in cows of 1st lactation was 3%, in cows of 2nd lactation – 10%, and in cows of 3rd lactation – 39%. (Table II)

Treponema spp. platings were cultured under anaerobic conditions for 7 days. After 72 hours, an irregularly shaped region of 3-4 mm developed in the test tube, in the center of which small transparent colonies or a delicate film with traces of erosion were rarely found on the MIA surface (Fig. 6)

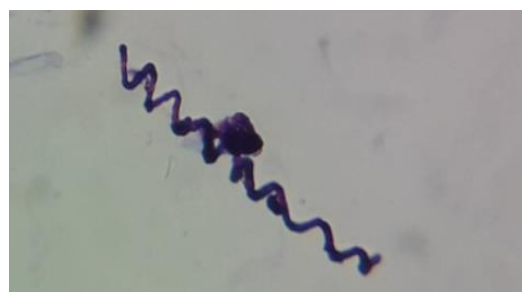

Fig. 4. Appearance of *Treponema* spp. in an impression smear under a light microscope.



Fig. 5 Appearance of the growth of Borrelia spp. on the MIB medium.

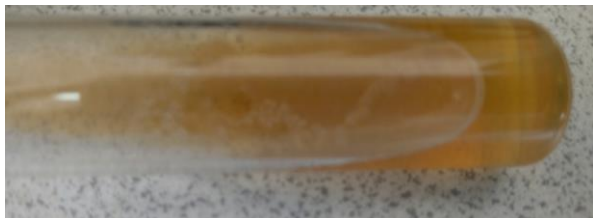

Fig. 6 Appearance of the growth of Treponema spp. on the MIB medium.

TABLE II. THE DYNAMICS OF THE INCIDENCE OF CATTLE WITH MORTELLARO'S DISEASE IN BUTOVO-AGRO, LLC

Livestock (n) of cows	Reported lesions of the distal portions of limbs characteristic of Mortellaro's disease	
	Total	MD
Lactation 1	2504	75/3%
Lactation 2	694	70/10%
Lactation 3	722	282/39%
Grand total	3920	427/11%

Analyzing the data from the table, we can conclude that, with the imported livestock, the sources of the causative agents of Mortellaro's disease were brought into the farm, and with intensive exploitation in 2018, 427 animal units (11%) were detected with lesions of the distal portions of limbs, manifesting by lesions of hooves, of which 75 animal units (3%) - cows of the 1st lactation, 70 animals (10%) - of the 2nd lactation and 282 animal units (39%) - of the 3rd lactation.

Bybacteriological studies of impression smears of taken punctates prior to treatment during the conduct of microscopical investigation was revealed the presence of pathogens Fusobacteria necrophorum (Fig. 3), Borrelia spp (Fig. 5), Tpeponema spp. (Fig. 4) from all animals of the control and experimental groups (Fig. 7).

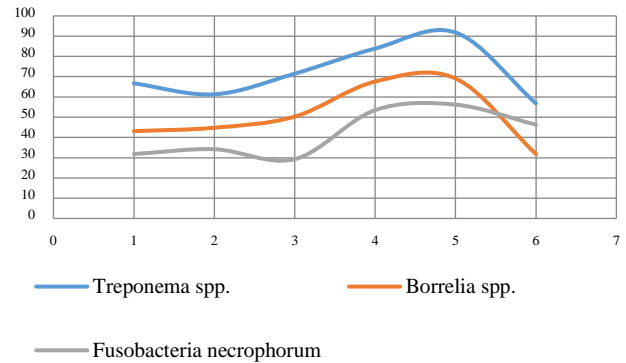


Fig. 7. Dynamics of changes in the specific gravity of the pathogens of Mortellaro's disease

When studying the specific gravity in relation to the total number of isolated cultures of the above pathogens after conducting cultural studies, it was found that in the punctates taken from animals of pure control, the proportion of Fusobacteria necrophorum was 31.8%, Borrelia spp. - 43.1% and Tpeponema spp. - 66.7%.

In punctates taken from animals of control group No. 1, these indicators amounted to Fusobacteria necrophorum 34.2%, Borrelia spp. - 44.8% and Tpeponema spp. - 61.3%.

In animals of the first experimental group, the pathogens were identified in the following amounts in punctates from the interdigital cleft: Fusobacteria necrophorum 29,3 %, Borrelia spp. - 50.3% and Tpeponema spp. - 71.5%.

The specific gravity of pathogens in 29 punctate samples of damaged skin and the skin coverings of the interdigital cleft of sick animals of experimental group No. 2 amounted to: Fusobacteria necrophorum 53,5 %, Borrelia spp. - 67.6% and Tpeponema spp. - 83.9%.

In punctates taken from cows of experimental group No. 3, the number of pathogens was determined: Fusobacteria necrophorum in 56,2% of samples, Borrelia spp. - 69.1%, Tpeponema spp. 91.8%.

From animals of the 4th experimental group, pathogens were isolated in the following amounts: Fusobacteria necrophorum 46,3 %, Borrelia spp. - 31.8% and Tpeponema spp. - 56.8%.

On average, in all groups, the isolation rate of Fusobacteria necrophorum was 41.8 ± 14.4 ; Borrelia spp. - 51.1 ± 19.3 ; Tpeponema spp. - 72 ± 19.8 .

After carrying out therapeutic measures, punctate samples were taken from the healing surfaces of the skin with further plating on previously used nutrient media. It was found that in all samples taken from animals of the pure control group, the specific gravity of microorganisms in relation to the previously obtained was: Fusobacteria necrophorum 42%, Borrelia spp. - 51.1% and Tpeponema spp. - 68.8%.

In punctates taken from animals of the control group No. 1, these indicators amounted to Fusobacteria necrophorum 7.2 %, Borrelia spp. - 4.8% and Tpeponema spp. - 5.3%.

In punctatestakenfrom animals of the first and second experimental groups, pathogens of Mortellaro's disease were not detected.

In punctates taken from animals of groups 3 and 4, *Fusobacterium necrophorum* was found from 1 and 2 animals, respectively. In general, the bactericidal effect of the drug was 99.9%.

After conducting therapeutic measures using the samples of the BelNano that we obtained, it was found that in pure control the state of the skin and skin coverings in animals affected by Mortellaro's disease only worsened, which was manifested by an increase in the number of animals with M4 lesions from 3 to 9, M3 from 4 to 69, and a decrease in M1 from 7 to 1, M2 from 6 to 4.

In cows of control group No. 1, the state of the affected areas of the skin and skin coverings with varying degrees of affection tended to slightly improve among the M1 lesions from 14 to 11 to 21%, in one animal at stage M3 there was a full recovery, in 3 animals the condition of lesions remained unchanged and in cows with M2 lesions the state worsened, with an increase in area to M3 (n = 2).

In experimental group No. 1 (M1), when examining lesions on the 3rd day after application of the drug, treatment of the interdigital cleft had a positive trend with the results: full recovery - 11 animals, and the formation of granulation tissue with a smooth surface of bright pink color - 29 animals. On day 7, the number of fully recovered animals reached 37, which amounted to 92.5%, and in the remaining 3 animal units, complete replacement of the affected areas with granulation tissue was not observed.

Among the animals of experimental group No. 2 (M2), the dynamics of improving the state of the skin and skin coverings was as follows: examination on day 3 showed that the acute phase of the lesions was replaced by healing in all cows, and in several animals (n = 6) the healing reached the granulation phase. On day 7, a full recovery of the skin and skin coverings was achieved in 25 animals, which amounted to 86%, in the rest of animals (n = 4) stage M2 transferred to M1 without exudation.

When examining the dynamics of treatment of lesions of skin and skin coverings in cows of experimental group No. 3 (M3), softening and dropping of squarrous necrotic surfaces and pale pink epithelial tissue were observed already on day 3

when removing gauze dressings, which characterizes the picture of full recovery for 20 animal units of cows, in the remaining animals (n = 39) lesions of skin and skin coverings were transformed into the granulation stage. On day 7, 52 animals had secondary intention healing, the skin in previously affected areas had no visible changes, in 7 animals the process was at stage M1.

According to the study in experimental group No. 4 it was found that out of 21 animals in 18 animal units the lesion passed to the granulation stage on day 7, and in 2 animals – to stage M1, the secondary intention healing was noted in 1 animal later. (Table III)

IV. CONCLUSION

The effectiveness of the therapeutic effect of the Bel-NANO sample containing silver and copper nanoparticles in comparative aspect with 10% aqueous solution of copper sulfate for the prevention and treatment of skin and skin coverings of the distal portions of limbs in Mortellaro's disease was studied. Research showed 89% efficiency providing a high bactericidal effect on pathogens of infections, expressed in the appearance of epithelial and granulation tissues in the affected areas of the skin and skin coverings already on the 3rd day of treatment. Positive bactericidal and bacteriostatic effects were noted to the value of 99.9%, which contributes to the purification of the wound surface from purulent exudate, which entailed the resorption of infiltrates, the appearance and growth of granulation tissue in the absence of pathogenic microflora, and, accordingly, the activation of metabolic and regenerative recovery processes.

This is due to the fact that the composition of the drug includes, in addition to silver and copper nanoparticles, liposome fractions with adsorbing properties and rapid penetration into the deeper layers of the epidermis and subcutaneous tissue, resulting in a detrimental effect on both pathogenic and saprophytic microflora, while maintaining a long time in tissues and providing long-term prolonged therapeutic effect.

A new dosage form of an antiseptic wound healing drug for topical use in diseases of the distal portions of limbs

TABLE III. THE RESULTS OF THE STUDY OF THE THERAPEUTIC EFFECTIVENESS OF THE EXPERIMENTAL SAMPLE OF THE BEL-NANO

Group	Number of animal units (n/ level of prevalence according to DopferD.e.) before treatment	The number of remaining affected animals after treatment using Bel-NANO	Therapeutic efficacy,%
Pure control	20/ M1 - 7, M2 - 6, M3-4, M4 - 3	20/ M1 - 1, M2 - 4, M3-6, M4 - 9	0
Control I	20 /M1 - 14, M2- 2, M3-4, M4 - 0	20/ M1 - 11, M2-0, M3-5, M4 - 0	20
Experimental No.1	40	3 (7.5%)	92.5
Experimental No.2	29	4 (14%)	86
Experimental No.3	59	7 (12%)	88
Experimental No.4	21	3 (14%)	86
Total in experimental groups	149	17 (11%)	89

(Mortellaro's disease) has been developed, which has not previously been used in veterinary medicine, based on nanotechnology. Copper and silver nanoparticles were embedded in the liposome fractions of the finished dosage form.

REFERENCES

- [1] A.V. Ivanov, H.N. Makaev, D.A. Khuzin, S.V. Shabunin, Yu.N. Alekhin, Diagnosis, treatment and prevention of finger diseases and necrobacteriosis of highly productive cows. Voronezh: Istoki Publishing House, 2013, 132p.
- [2] R. Cheli, C.M. "Mortellaro, La dermatitedigitale del bovino", Proc. 8th International Conference on Diseases of Cattle, P. 208-213.
- [3] D. Döpfer, "Dermatitis digitalis: Klauen-krankheit mit vielen Gesichtern", Milchpur das Magazi n des Milchprüfing Bayern E.V., vol. 3, pp. 12-17, 2012.
- [4] D.J. Sprecher, D.E. Hostetler, J.B. Kaneene, "Locomotion Scoring of Dairy Cattle", Theriogenology, vol. 47, pp. 1178-1187, 1997.
- [5] D. Döpfer, M. Holzhauser, M. van Boven, "The dynamics of digital dermatitis in populations of dairy cattle: Model-based estimates of transition rates and implications for control", The Veterinary Journal, vol. 193, pp. 648-653, 2012.
- [6] T. Manske, J. Hultgren, C. Bergsten, "Topical treatment of digital dermatitis associated with severe heel-horn erosion in a Swedish dairy herd", Prev. Vet. Med., vol. 53, pp. 215-231, 2002.
- [7] V.I. Koziy, "Etiology and course of endemic papillomatous digital dermatitis in high-yielding dairy cows", Vet. Medicine of Ukraine, № 26-28, 2005.
- [8] A.M. Kovalenko, S.A. Khomutovskaya, N.A. Belyakova, V.A. Kuzmin, A.V. Tsyganov, N.P. Ponomarenko, "Mortellaro's disease – approaches to the design of products containing nanoparticles for treating cows", Hippology and Veterinary Medicine - St. Petersburg, № 1 (27), pp. 53-61, 2018.
- [9] A.A. Samolovov, S.V. Lopatin, Diseases of the hooves and finger of cattle. Ros. akad. s.-kh. sciences. Sib. region Institute of Experiment. Veterinary medicine of Siberia and the Far East: Novosibirsk, 2010, pp. 80 - 95.
- [10] T.M.A. Santos, R.V. Pereira, L.S. Caixeta, C.L. Guard R.C. Bicalho, "Microbial diversity in bovine papillomatous digital dermatitis in Holstein dairy cows from upstate New York", FEMS Microbiol. Ecol., vol. 79, pp. 518-529, 2012.
- [11] G. Sayers, P.X. Marques, N.J. Evans, L. O'Grady, M.L. Doherty, S.D. Carter, J.E. Nally, "Identification of spirochetes associated with contagious ovine digital dermatitis", J. Clin. Microbiol., vol. 47, pp. 1199-1201, 2009
- [12] . Moter, G. Leist, R. Rudolph, K. Schrank, B.K. Choi, M. Wagner U.B. Göbel." Fluorescence in situ hybridization shows spatial distribution of as yet uncultured treponemes in biopsies from digital dermatitis lesions", Microbiol. vol. 144, pp. 2459-2467, 1998.
- [13] I. Demirkan, S.D. Carter, R.D. Murray, R.W. Blowey, M.J. Woodward, "The frequent detection of a treponeme in bovine digital dermatitis by immunocytochemistry and polymerase chain reaction", Veterinary Microbiology, vol. 60, pp. 285-292, 1998.
- [14] R.J. Collighan, M.J. Woodward, "Spirochaetes and other bacterial species associated with bovine digital dermatitis", FEMS Mic. Lett., vol. 156, pp. 37-41, 1997.
- [15] K.K. Moe, T. Yano, K. Misumi, C. Kubota, W. Yamazaki, M. Muguruma, N. Misawa, "Analysis of the IgG Immune Response to Treponema phagedenis-Like Spirochetes in Individual Dairy Cattle with Papillomatous Digital Dermatitis", Clinical and vaccine immunology, vol. 17 (3), P. 376-383, 2010.
- [16] K. Klitgaard, M. Boye, N. Capion, T.K. Jensen, "Evidence of Multiple Treponema Phylotypes Involved in Bovine Digital Dermatitis as Shown by 16S rRNA Gene Analysis and Fluorescence In Situ Hybridization", Journal of clinical microbiology, vol. 46 (9), pp. 3012-3020. 2008.
- [17] J.G.C.J. Somers, K. Frankena, E.N. Noordhuizen-Stassen, J.H.M. Metz, "Risk factors for digital dermatitis in dairy cows kept in cubicle houses in The Netherlands", Preventive Veterinary Medicine, vol. 71, pp. 11-21, 2005.
- [18] S.J. Wells, L.P. Garber, B.A. Wagner, "Papillomatous digital dermatitis and associated risk factors in US dairy herds", Prev. Vet. Med., vol. 38, pp. 11-24, 1999.
- [19] M. Metzner, D. Döpfer, R. Pijl W. Kehler, "Dermatitis digitalis des Rindes: klinisches Bild, Epidemiologie und Maßnahmen", Prakt. Tierarzt., Sondernummer collegium veterinarium XXV. vol. 76, pp. 46-50, 1995.
- [20] J.E. Nocek., A.B. Johnson, M.T. Socha, "Digital characteristics in commercial dairy herds fed metal-specific amino acid complexes", J Dairy Sci, vol. 83(7). pp. 1553-1572, 2000.
- [21] M. Holzhauser, C.J.M. Bartels, D. Döpfer, G. van Schaik, "Clinical course of digital dermatitis lesions in an endemically infected herd without preventive herd strategies", The Veterinary Journal, vol. 177, pp. 222-230, 2008.
- [22] Olmos, L. Boyle, B. Horan, D.P. Berry, P. O'Connor, J.F. Mee, A. Hanlon, "Effect of genetic group and feed system on locomotion score, clinical lameness and hoof disorders of pasture-based Holstein-Friesian cows G.", The Animal Consortium Animal, vol. 3 (1), pp. 96-107, 2009.
- [23] R.A. Laven, D.N., "Logue Treatment strategies for digital dermatitis for the UK", The Veterinary Journal, vol. 171, pp. 79-88, 2006.
- [24] RF patent for invention No. 2601120 C1 A method for the treatment of infectious diseases of the distal portions of limbs in cattle, published on 10.27.2016, Authors: Kovalenko A.M., Dorofeev A.F., Spirina A.S. et al.
- [25] M. Shahabaddin, I. Nowrouzian, M. Nouri, S.M.K.S. Javad, "Clinical Assessment of Four Individual Treatment for Digital Dermatitis in Dairy Cows", Iranian journal of veterinary surgery, vol. 2, pp. 56-60, 2007.
- [26] J.R. Morones, J.L. Elechiguerra, A. Camacho, K. Holt, J.B. Kouri, J.T. Ramirez et al., "The bactericidal effect of silver nanoparticles", Nanotechnology, vol. 16(10), pp. 2346-2353, 2005.