



Artery Research

ISSN (Online): 1876-4401

ISSN (Print): 1872-9312

Journal Home Page: <https://www.atlantispress.com/journals/artres>

P6.02: SIMULTANEOUS MEASUREMENTS OF THE AORTIC AND COMMON CAROTID DISTENSION WAVEFORMS BY MEANS OF ULTRASOUND

K.G. van den Hengel, P.J. Brands, E.M.H. Bosboom, F.N. van de Vosse

To cite this article: K.G. van den Hengel, P.J. Brands, E.M.H. Bosboom, F.N. van de Vosse (2009) P6.02: SIMULTANEOUS MEASUREMENTS OF THE AORTIC AND COMMON CAROTID DISTENSION WAVEFORMS BY MEANS OF ULTRASOUND, Artery Research 3:4, 164–164, DOI: <https://doi.org/10.1016/j.artres.2009.10.069>

To link to this article: <https://doi.org/10.1016/j.artres.2009.10.069>

Published online: 14 December 2019

Methodological Aspects 2

P6.01

ULTRASOUND EVALUATION OF LOCAL ARTERIAL STIFFNESS: FEASIBILITY STUDY IN AN ANIMAL MODEL OF ADVANCED ATHEROSCLEROSIS

E. Bianchini¹, C. Giannarelli², F. Fata¹, G. Cimmino², V. Gemignani¹, J. J. Badimon²

¹Institute of Clinical Physiology - CNR, Pisa, Italy

²Atherothrombosis Research Unit, Cardiovascular Institute - Mount Sinai School of Medicine, New York, USA

Atherosclerosis is a pathological process affecting arterial elasticity. The rabbit is one of the most widely used animal models for atherosclerosis research. The aim of this study was to evaluate the feasibility of a method for the automatic assessment of local vascular stiffness in rabbits.

An off-line algorithm for the evaluation of arterial diameter (D) and distension (ΔD) from ultrasound image sequences was developed in Matlab and tested in 3 atherosclerotic and 2 control rabbits. Longitudinal scans of the aortic and carotid arteries of the rabbits were recorded in DICOM format. High frame-rate (330 Hz) image sequences (3 seconds) were acquired to track the rapid movement of the vessel (heart rate ~ 240 bpm) using iE33 Philips ultrasound system. The probe was held by a clamp. The measurement variability was assessed by performing two scans for each subject.

The high frame-rate provided a temporal resolution of 3 msec allowing the instantaneous tracking of the diameter curve for both carotid and aorta. As regards the variability, the coefficients of variation were: $3\% \pm 2\%$ (D) and $7\% \pm 3\%$ (ΔD) for the aorta (mean D = 3.2 mm) and $3\% \pm 2\%$ (D) and $5\% \pm 4\%$ (ΔD) for the carotid (mean D = 1.99 mm).

Our data demonstrate that the implemented ultrasound image processing algorithm is able to non-invasively assess the vascular instantaneous diameter both in control and atherosclerotic rabbits. The method, together with intra-central ear artery blood pressure measurement, could evaluate the effects of new therapeutic interventions on vascular stiffness in those pathological conditions characterized by arterial dysfunction, such as atherosclerosis.

P6.02

SIMULTANEOUS MEASUREMENTS OF THE AORTIC AND COMMON CAROTID DISTENSION WAVEFORMS BY MEANS OF ULTRASOUND

K. G. van den Hengel³, P. J. Brands¹, E. M. H. Bosboom², F. N. van de Vosse³

¹Esaote Europe, Maastricht, Netherlands

²Maastricht University Medical Centre, Maastricht, Netherlands

³Eindhoven University of Technology, Maastricht, Netherlands

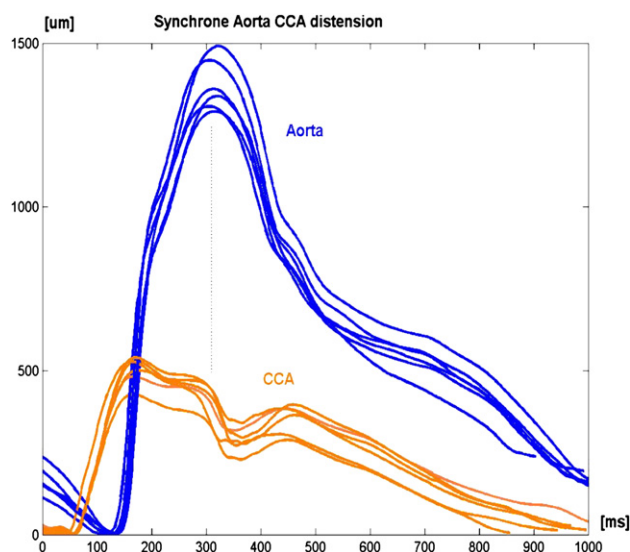


Figure 1 AA and CCA pulse waveform measured during 6 heartbeats in 1 volunteer.

Cardiac and arterial function is reflected in the distension (change in diameter) waveforms of central arteries.

For analyses, commonly the distension waveform of the common carotid artery (CCA) is used, as the CCA is superficial and easily accessible with ultrasound (US). However, the abdominal aorta (AA) is directly connected to the aortic root and a more pronounced influence of cardiovascular diseases on the AA pulse waveform is expected. The aim of this study is to compare the pulse waveforms in AA and CCA.

For this purpose, simultaneous assessment of the distension waveforms in the AA and CCA are performed on three healthy volunteers using two ultrasound scanners with ART.LAB functionality (Picus, Esaote Europe). The two systems are synchronised using ECG triggering. In addition, radial blood pressure is recorded continuously (Colin, USA).

Results show, that AA and CCA distension could reproducibly be measured. The ejection periods of the heart assessed from these pulse waves are equal. The maximum wall velocity is about 2.5 times higher in AA than in CCA. Approximated local blood pressure pulse is higher in AA than in CCA (58 mmHg and 44 mmHg respectively). Local pulse wave velocities, based on the distensibility coefficient, only slightly differ.

Future research will focus on analyzing the differences between both pulse waveforms with a 1D wave propagation model.

P6.03

SIMULTANEOUS UPPER ARM AND THIGH CUFF PULSE VOLUME RECORDING FOR RAPID ESTIMATION OF CENTRAL PULSE WAVE VELOCITY: COMPARISON WITH CAROTID-FEMORAL TONOMETRY

A. Donald, Z. Maniou, K. Connell, K. McNeill, T. Sanders, P. Chowiecnyk King's College, London, United Kingdom

Objectives: Aortic pulse wave velocity (PWV) is usually estimated by sequential (ECG referenced) carotid-femoral tonometry using the Sphygmocor system (Atcor, Australia). This can be technically challenging and operator dependant. Here we evaluate a simple, operator independent method of estimating central PWV based upon simultaneous recording from upper arm and thigh cuffs (Vicorder, Skidmore Medical, UK).

Methods: PWV was measured using the Vicorder and Sphygmocor systems (each measurement in triplicate) in 133 adults (mean age 53, range 21-70 years). Sphygmocor PWV was calculated using the suprasternal notch (sn) to femoral distance. Two distances were used to calculate PWV from the Vicorder: cuff to cuff measured with arm at the side (cc) and sn to thigh cuff minus sn to arm cuff (notch to cuff difference, ncd). Reproducibility of the Vicorder was further assessed by repeat measures in 9 subjects.

Results: Mean values of PWV obtained by Sphygmocor, Vicorder (cc) and Vicorder (ncd) were 9.0 ± 1.6 , 12.0 ± 2.8 and 8.7 ± 1.9 m/s respectively. Both Vicorder (cc) and Vicorder (ncd) were closely correlated with Sphygmocor PWV (each $r = 0.7$). The mean difference between Sphygmocor and Vicorder (ncd) was 0.2 ± 1.4 m/s. The within subject standard deviation for repeated measures for Vicorder (ncd) was 0.54 m/s.

Conclusion: There is a high correlation between values obtained using the Vicorder and Sphygmocor and good reproducibility for Vicorder measurements. Differences between the methods are likely due to errors in the estimation of path length. Vicorder PWV is quick and easy to perform with minimal training and offers a simple alternative to applanation tonometry.

P6.04

COMPARISON BETWEEN PULSE WAVE VELOCITY ASSESSMENT IN THE OBESE BY TRANSCUTANEOUS DEVICES COMPARED TO PHASE CONTRAST MAGNETIC RESONANCE IMAGING

L. Joly¹, A. Kearney-Schwartz¹, P. Salvi¹, D. Mandry⁴, G. Karcher², P. Rossignol³, P. Y. Marie², F. Zannad³, A. Benetos¹

¹Service de Geriatrie, CHU Nancy, Nancy, France

²Service de Medecine Nucleaire, CHU Nancy, Nancy, France

³Centre d'Investigations Clinique et Therapeutique, CHU Nancy, Nancy, France

⁴Service de radiologie, CHU Nancy, Nancy, France

Background: Abdominal obesity is a clinical setting recognized as a difficult situation to assess transcutaneous pulse wave velocity (PWV). PWV measurement between carotid and femoral sites is considered as the gold standard measurement of aortic stiffness. Arterial stiffness is an important parameter to assess in obese patient to improve physiopathological knowledge about the link between abdominal adiposity and aortic elastic properties.

Method: We included prospectively 32 patients mean age of 55.7 ± 5.1 years, presenting abdominal obesity defined by a waist circumference >102 cm in men and >88 cm in women ($27 < \text{BMI} < 35$). Regional aortic