

Artery Research

ISSN (Online): 1876-4401 **ISSN (Print): 1872-9312**
Journal Home Page: https://www.atlantis-press.com/journals/artres

P3.16: EFFECTS OF SYMPATHETIC BLOCKADE ON PRESSURE DEPENDENT ABDOMINAL AORTIC STIFFNESS IN THE SPONTANEOUSLY HYPERTENSIVE RAT

G. Lindesay, M. Butlin, A. Avolio

To cite this article: G. Lindesay, M. Butlin, A. Avolio (2012) P3.16: EFFECTS OF SYMPATHETIC BLOCKADE ON PRESSURE DEPENDENT ABDOMINAL AORTIC STIFFNESS IN THE SPONTANEOUSLY HYPERTENSIVE RAT, Artery Research6:4, 181–181, DOI: https://doi.org/10.1016/j.artres.2012.09.142

To link to this article: https://doi.org/10.1016/j.artres.2012.09.142

Published online: 21 December 2019

levels of TKE are undesirable, as the increased fluctuations removes energy from the mean flow.
Surgery was performed to widen the coarctation and catheter measurements showed a decrease in pressure drop, which resulted in an increased flow rate. As a consequence of the increased flow, the local Reynolds number also increased. The results from the CFD-simulations confirmed the pressure drop, but also showed that for the post-surgery model TKE levels increased at peak systole in the immediate downstream region of the coarctation.
The relationship between pressure drop, flow rate, coarctation diameter and Reynolds number is non-linear, and if both the flow rate and coarctation diameter increase as an outcome of surgery, the local Reynolds number may also increase. This, in turn, can result in an elevation of TKE levels after surgery.

Figure 1 Volume rendering of TKE in pre- and post-surgery models

P3.16
EFFECTS OF SYMPATHETIC BLOCKADE ON PRESSURE DEPENDENT ABDOMINAL AORTIC STIFFNESS IN THE SPONTANEOUSLY HYPERTENSIVE RAT

G. Lindesay, M. Butlin, A. Avolio
Macquarie University, Sydney, Australia

Background: Increased sympathetic nerve activity (SNA) is associated with development of hypertension in spontaneously hypertensive rats (SHR). Elevated SNA increases arteriolar smooth muscle tone affecting peripheral resistance, however, the effect on large arteries is not well established. This study aimed to assesses the effect of SNA on aortic stiffness in SHR using sympathetic blockade at different values of mean arterial pressure (MAP).
Methods: SHR of 10-15 weeks (n=15) were anaesthetized (urethane 1.3g/kg/ml) and ventilated. Aortic blood pressure and pulse wave velocity (PWV) were measured by two high fidelity catheter-tip pressure transducers in the abdominal aorta via the carotid and femoral arteries. Aortic diameters were measured using ultrasound (6.2 MHz) with vessel tracking software (ArtLab, Esaote). Aortic compliance was calculated from diameter and pressure signals. Measurements were taken at low (70 mmHg), intermediate (140 mmHg) and high (170 mmHg) values of basal MAP and following sympathetic blockade with hexamathonium (i.v 20mg/kg). Arterial pressure was varied by bolus injection of phenylephrine (i.v 30μg/kg).
Results: Increase in MAP was associated with increase in arterial stiffness indices. Following sympathetic blockade, there was a trend for reduction in compliance associated with a significant increase in pulse pressure at low MAP. There was no significant difference in parameters at other values of MAP.

MAP (mmHg)	Parameter	Control	Hex.	Difference %	P-value
70	C (ml/mmHg)	7.1 ± 1.6	6.2 ± 1.7	14.5	0.07
	PP (mmHg)	38.1 ± 5.6	42.3 ± 7.6	-9.9	0.03 *
	PWV (m/s)	2.9 ± 1.2	2.8 ± 1.1	3.6	0.14
140	C (ml/mmHg)	3.4 ± 1.0	3.3 ± 0.7	3.0	0.55
	PP (mmHg)	53.8 ± 4.8	54.8 ± 6.5	-1.8	0.43
	PWV (m/s)	5.3 ± 1.0	5.5 ± 1.0	-3.6	0.08
170	C (ml/mmHg)	2.0 ± 0.5	2.2 ± 0.4	-9.1	0.16
	PP (mmHg)	72.4±10.9	71.7±11.5	1.0	0.88
	PWV (m/s)	6.5 ± 1.3	7.0 ± 1.5	-7.14	0.13

C: compliance; PP: pulse pressure; PWV: pulse wave velocity; Hex: hexamathomium;

Conclusions: These data suggest that sympathetic blockade can potentiate a stiffening effect in the abdominal aorta at low MAP in the SHR. This may be due to reduction of smooth muscle tone transferring the load from elastin to collagen in the vessel wall.

P3.17
WALL TRACKING FOR THE ASSESSMENT OF AORTIC DISTENSIBILITY DURING A FOLLOW UP OF 49 DAYS IN ANGIOTENSIN II-INFUSED APOE-/- MICE

F. J. Londono, A. Swillens, B. Trachet, P. Segers
IBitech-bioMMeda (Ghent University), Ghent, Belgium

Introduction: Ultrasound wall tracking allows assessing the distension of superficial arteries. While the technique is well established in humans, wall tracking is challenging in mice due to the smaller size of the arteries. The aim of this study was to assess the feasibility of sequential distension measurements on the aorta of an aortic aneurysm mouse model.
Methods: In-house bred male ApoE -/- mice were implanted an osmotic pump filled with Angiotensin II. Ultrasound data were obtained with a high-frequency ultrasound apparatus equipped with a linear array probe. All measurements were performed by a single operator. M-mode images of proximal and distal abdominal aorta were obtained in 5 animals on day 1, 6, 14, 30 and 49. Dedicated software was employed for wall tracking using stored demodulated Radio Frequency (RF) data. Resulting curves were processed to calculate the diastolic diameter and the relative *(*DeltaD/D*)* arterial diameter distension.
Results: Proximal abdominal aorta diastolic diameter presented higher values than distal abdominal aorta, as expected. However, diameter values in both locations decreased through time, reaching a minimum at day 30. DeltaD/D progressively decreased from baseline until day 14 in both locations, after which values increased to near baseline levels at day 49.
Conclusion: RF-based Vessel wall tracking of the abdominal aorta in an aneurysmatic mouse model is feasible. Our data suggest an initial narrowing and stiffening of the abdominal aorta up to day 14, followed by an increase in diameter and distensibility, a phenomenon that is possibly due to Angiotensin II-induced smooth muscle contraction.

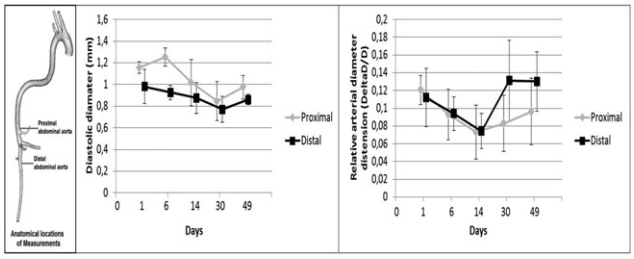

P3.18
SHEAR WAVE ELASTOGRAPHY ASSESSMENT OF CAROTID ARTERY PLAQUE — HISTOLOGY FINDINGS

S. Nduwayo [1], R. B. Panerai [1], K. V. Ramnarine [1], A. R. Naylor [2], T. G. Robinson [1], K. West [3]
[1]*Department of Cardiovascular Sciences, University of Leicester, Leicester, United Kingdom*
[2]*Department of Vascular and Endovascular Surgery, University Hospital Leicester, Leicester, United Kingdom*
[3]*Department of Histopathology, University Hospital Leicester, Leicester, United Kingdom*

Introduction: Carotid atherosclerosis is a risk factor for ischaemic stroke. There is increasing interest in identifying and characterising high-risk unstable carotid plaques. Shear wave elastography (SWE) imaging is a new method of quantifying tissue stiffness with potential to provide additional information to help identify the unstable plaque and improve patient selection for surgical treatment. We evaluate this technique in assessing stiffness of carotid artery plaques by correlating histology findings to Young's modulus (YM) measured using SWE.
Method: 5 symptomatic patients undergoing carotid endarterectomy were recruited into the study. Prior to surgery, each patient underwent carotid ultrasound scan using SWE and B-mode. A longitudinal section of the carotid plaque was imaged. The YM of the plaques was compared to echogenicity and histological classification based on stability of the excised plaque.