



Artery Research

ISSN (Online): 1876-4401

ISSN (Print): 1872-9312

Journal Home Page: <https://www.atlantis-press.com/journals/artres>

P138: INFLUENCE OF ULTRASOUND SETTINGS ON CAROTID BIOMARKER ASSESSMENT BY B-MODE IMAGE PROCESSING

Martina Francesconi, Vincenzo Gemignani, Rachele Gherardini, Nicole Di Lascio, Francesco Faita, Lorenzo Ghiadoni, Rosa Maria Bruno, Elisabetta Bianchini

To cite this article: Martina Francesconi, Vincenzo Gemignani, Rachele Gherardini, Nicole Di Lascio, Francesco Faita, Lorenzo Ghiadoni, Rosa Maria Bruno, Elisabetta Bianchini (2018) P138: INFLUENCE OF ULTRASOUND SETTINGS ON CAROTID BIOMARKER ASSESSMENT BY B-MODE IMAGE PROCESSING, Artery Research 24:C, 119–119, DOI: <https://doi.org/10.1016/j.artres.2018.10.191>

To link to this article: <https://doi.org/10.1016/j.artres.2018.10.191>

Published online: 7 December 2019

alteration. The noninvasive derivation of Ees remains thus challenging. Here, we present a novel method to estimate the LV pressure-volume loop and elastance in humans from given aortic flow waveforms, LV ejection fraction and brachial pressure using a 1-D model of the cardiovascular system (1).

Methods: Initially, the measured aortic flow waveform is used as the input to the default 1-D model and the output brachial systolic and diastolic pressure are compared with the 'real' values. Subsequently, arterial compliance and peripheral resistance are modified accordingly until peripheral pressure is accurately predicted. In a second step, this person-specific model is used to estimate the elastance parameters that produce the 'real' aortic flow waveform. Additional knowledge of the LV ejection fraction can allow us to derive the entire pressure-volume loop, including end-diastolic elastance. The method was tested on a database of 50 different in silico hemodynamic cases generated after varying cardiac and arterial model parameters.

Results: Implementation of the method yielded good agreement ($r = 0.99$) and accuracy ($n\text{-RMSE} = 4\%$) between 'real' and estimated values of Ees (Figure 1). Furthermore, a sensitivity analysis revealed that errors due to poor arterial adjustment and measurements are small ($\leq 8\%$ for Ees).

Conclusion: The insilico validation of the proposed method gave promising results and we are currently planning its testing against in vivo data.

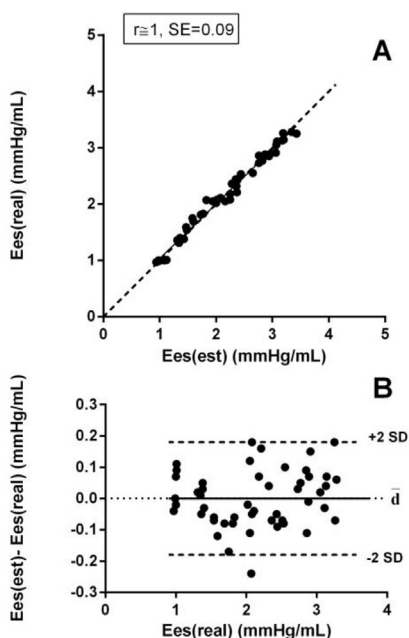


Figure 1. A. Scatter plot of the method-derived Ees (Ees(est)) vs the 'real' values (Ees(real)) for the 50 simulated cases. B. the respective Bland-Altman plot

References

1. Reymond P, Merenda F, Perren F, Rufenacht D, Stergiopoulos N. Validation of a one-dimensional model of the systemic arterial tree. *Am J Physiol - Heart Circ Physiol.* 2009 Jul 1;297(1):H208–22.

P138

INFLUENCE OF ULTRASOUND SETTINGS ON CAROTID BIOMARKER ASSESSMENT BY B-MODE IMAGE PROCESSING

Martina Francesconi ^{1,2}, Vincenzo Gemignani ¹, Rachele Gherardini ², Nicole Di Lascio ¹, Francesco Faita ¹, Lorenzo Ghiadoni ², Rosa Maria Bruno ², Elisabetta Bianchini ¹

¹Institute of Clinical Physiology, National Research Council, Pisa, Italy
²Department of Clinical and Experimental Medicine, University of Pisa, Pisa, Italy

Purpose/Background/Objectives: This study aims to investigate how image settings affect carotid Intima-Media-Thickness (IMT) and diameter estimation performed with CarotidStudio (Quipu Srl).

Methods: 14 healthy volunteers (24.4 ± 4.4 years; 8 men) were recruited. Longitudinal scans 3cm deep of common-carotid-arteries with the same region-of-interest were obtained by expert operator, starting from a "default" setup (central Time Gain Compensation-TGC; gain:50 dB; no persistence filter) and adjusting one parameter at a time (oblique TGC; gain:10 dB increments from 30 to 70 dB; persistence filter). The acquisition was performed twice and repeatability was expressed for each setup as coefficient of variation (CV). Significant changes ($p < 0.05$) with respect to the "default" setup were analysed by paired Student-t-test.

Results: A 70 dB gain results in overestimating IMT (from $0.46 \text{ mm} \pm 0.01 \text{ mm}$ to $0.54 \text{ mm} \pm 0.01 \text{ mm}$), underestimating diameter (from $6.04 \text{ mm} \pm 0.04 \text{ mm}$ to $5.70 \text{ mm} \pm 0.23 \text{ mm}$), increasing their CVs (from $2.14\% \pm 1.92\%$ to $6.85\% \pm 5.23\%$ for IMT, from $1.79\% \pm 1.22\%$ to $4.77\% \pm 4.71\%$ for diameter) and in 4/14 cases the estimation wasn't possible. Distension CV increases also with 60 dB (from $5.71\% \pm 4.31\%$ to $10.84\% \pm 5.91\%$ and to $12.59\% \pm 7.97\%$). Persistence and TGC do not affect repeatability, whereas diameter ($5.96 \text{ mm} \pm 0.03 \text{ mm}$) and distension (from $0.82 \text{ mm} \pm 0.02 \text{ mm}$ to $0.66 \text{ mm} \pm 0.02 \text{ mm}$) values are influenced by persistence.

Conclusions: CarotidStudio precision does not show significant alterations except from 70 dB gain, which, due to the image grey-level saturation, results in poor image quality and modified values. Persistence does not affect precision but leads to reduced diameter and distension, possibly for the intrinsic behaviour of mathematical operator and image temporal filtering. Gain and persistence influence ultrasound biomarker estimation; the chosen setup should be documented and replicated in follow-up scans.

P139

AUTOMATIC CLASSIFICATION OF ARTERIAL AND VENULAR TREES IN COLOUR FUNDUS IMAGES

M. E.ena Martinez-Perez ¹, Kim Parker ², Nick Witt ², S. A. McG. Thom ³, Alun Hughes ⁴

¹Department of Computer Science, Institute of Research in Applied Mathematics and Systems, National Autonomous University of Mexico, UK

²Department of Bioengineering, Imperial College, London, UK

³Faculty of Medicine, National Heart & Lung Institute, Imperial College, London, UK

⁴Institute of Cardiovascular Science, University College London, London, UK

Background: Quantitative imaging of retinal arterioles and venules offers unique insights into cardiovascular and microvascular diseases but is laborious. We developed and tested a method to automatically identify Arterial/Venular (A/V) vessels in digital retinal images in conjunction with a semi-automatic segmentation technique.

Methods: Segmentation of blood vessels and the Optic Disc (OD) was performed as previously described [1] using a dataset of X colour fundus images. Using the OD as a reference point a graph representation was constructed using the vessel skeletons. Vessel bifurcations and crossings were identified based on direction and local geometry, and A/V classification was carried out by fuzzy logic classification using colour information. Results were compared with expert classification.

Results: 157 arterial and 150 venular segments were classified. Preliminary Results showed sensitivity, specificity and accuracy of 42.20%, 99.21% and 97.73% for arteries and 50.89%, 98.70% and 97.54% for veins. An example is shown in Figure 1.

Conclusions: Computer-based systems can assess local and global aspects of the retinal microvascular architecture, geometry and topology. Automated A/V classification will facilitate efficient cost-effective assessment of clinical images at scale.

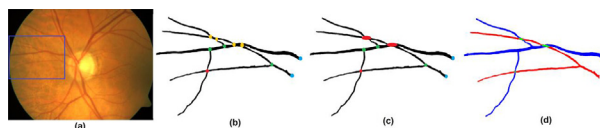


Figure 1 (a) Colour image, rectangle crop area in (b)-(d), (b) segmented blood vessels, red crossing, green bifurcations, blue root and yellow ambiguous points, (c) ambiguous points corrected, and (d) classified vessels, red artery and blue vein.

Reference

1. Martinez-Perez et al. *Med Image Anal* 2007; 11(1):47-61.