

Detection of Rickettsial Infection Among Febrile Patients in Semarang City

Dyah Widiastuti

Banjarnegara Health Research and Development Unit
Banjarnegara, Central Java, Indonesia
umi.azki@gmail.com

Nova Pramestuti

Banjarnegara Health Research and Development Unit
Banjarnegara, Central Java, Indonesia
nova.pramestuti87@gmail.com

Siwi Pramata Mars Wijayanti

Public Health Department
Faculty of Health Sciences, Jenderal Soedirman University
Banyumas, Central Java, Indonesia
siwimars@gmail.com

Jastal

Banjarnegara Health Research and Development Unit
Banjarnegara, Central Java, Indonesia
jastal70@gmail.com

Abstract—Rickettsial infection is a critical public health problem caused by *Rickettsia sp* and is distributed worldwide, mainly transmitted by the fleas of rodent. Semarang City has abundant rodent population but the report of Rickettsial infection cases was very limited. The aim of this study is to identify Rickettsial infections among febrile patients at Primary Health Centre in Semarang City. Blood samples were collected from patients at twenty Primary health centres in Semarang City and laboratory tests were performed at the Banjarnegara Research and Development of Zoonosis Control Unit. In this study, the detection of Rickettsial infection in febrile patients was carried out using an IgM Enzyme-linked Immunosorbent Assay (ELISA) Test using 17 kDa protein antigen of *Rickettsia*. Out of 142 enrolled patients, 40 (28.2%) had a positive result for IgM against *Rickettsia* with 18 (45%) male patients and 22 (55%) female patients. The predominant symptoms were fatigue, nausea, and headache. There was no mortality observed among the patients. Most of those tested with a positive result were over 20 years old. *Rickettsia* infection was a frequent case yet still an under-recognized cause of febrile illness in Semarang. This infection should be considered by clinicians in the differential diagnoses of febrile diseases so that local clinicians can provide appropriate drug treatment.

Keywords: *Rickettsia, febrile patient, ELISA, Semarang City*

I. INTRODUCTION

Rickettsial infection is an acute febrile illness caused by *Rickettsia sp.* and distributed worldwide by the role of rodent–flea cycles. Transmission to humans can occur when *Rickettsia*-infected feces contaminate flea bite or wound on the skin for other reasons. *Rickettsia sp.* is a gram-negative and obligate intracellular bacillus [1,2]. The main clinical characteristic of this disease is non-specific fever. Other symptoms that may arise are headache, arthralgia, abdominal pain, and confusion. The incubation period of this disease can last for 6–14 days. The appearance of rash on the body is another symptom that is quite typical. Macular or maculopapular rash can spread to the palms and soles of the feet. In general, rash starts to appear 1 week after onset and will disappear within 1-4 days. Proper and effective treatment for Rickettsial infection will result in a good prognosis and is

actually easy to treat when administered in the initial phase of the infection. However, if the patient is not properly diagnosed and gets inappropriate treatment, it will cause severity or even death. Delay in treatment due to misdiagnosis can trigger a severe infection in patients with Rickettsial infection [2]. Infection of *Rickettsia* can lead to vasculitis which will cause damage to various organs, including the brain. Vasculitis will occur when *Rickettsia* bacteria proliferate and spread to the bloodstream to cause injury to endothelial tissue and smooth vascular muscle cells. *Rickettsia* bacterial infections may also cause cerebral artery damage that will result in brain damage [3].

Across its worldwide distribution, *Rickettsia* has been observed in coastal urban areas. Previous study stated that this disease is endemic in certain area and is preserved among rats (*Rattus spp.*) and rat fleas (*Xenopsylla cheopis*) [4]. Semarang City has abundant rodent population but the report of Rickettsial infection cases was limited. Recent study in Semarang reported that among sequent outpatients at 2 primary healthcare centers and hospitalized patients at Dr. Kariadi University Hospital, Department of Internal Medicine, Semarang, Murine typhus was detected in 6 (9%) of 67 hospitalized patients and 3 (4%) of 70 outpatients had acute murine typhus. Inconclusive *R. typhi* serologic results were shown in other 9 (7%) patients. One patient showed evidence of past infection with *R. typhi* [5]. Another study indicated that the infection of *R. typhi* in rodent flea was also found in this city [6]. The comprehensive information about the causes of febrile illnesses in Semarang is still very limited. There is still a lack of study examining this phenomenon. This study is aimed to identify the potential contribution of Rickettsial infections and illness severity among febrile patients present at primary health centre in Semarang City. Early detection of Rickettsial infection is very important to be carried out by clinicians so that treatment for patients can be given as early as possible. Antibacterial therapy will be more effective if given in the initial phase of the infection. In addition, the health authorities should ensure that health services are well-equipped for proper case management.

II. MATERIAL AND METHODS

A. Clinical Investigation

In this study, we detected cases of Rickettsial infection and observed clinical symptoms. Blood samples were collected from patients at 20 primary health centres in Semarang City. Laboratory tests were performed at the Banjarnegara Research and Development of Zoonosis Control Unit.

B. Serologic Analysis

The serologic analysis was conducted to the samples by using indirect Enzyme-linked immunosorbent assay (ELISA) test for 17 kDa *R. typhi* antigenic protein which was fixed onto microplate wells. In this study, antibodies specific to *Rickettsia* were detected by using anti-human IgM specific Horse Radish Peroxidase (HRP)-labeled conjugates. We used HRP conjugates (Sigma) against human immunoglobulin human IgM produced in goats (μ -chain-specific) at a final dilution of 1:5000. The assay procedure, buffers, and other chemicals were used in accordance with the method described by Abcam [7].

III. RESULTS

Forty of 142 (28.2%) patients with suspected cases were confirmed to have Rickettsial infection. All 40 were laboratory confirmed by ELISA assay. Illness onset among the patients ranged from May through September 2017. Most patients with confirmed cases (62.5%) were over 20 years old (Figure 2) and most of them (55%) were male (Figure 1).

No mortality and severity were correlated to murine typhus among these patients. The most commonly reported symptoms observed in our study were fatigue (92.5%), headache (87.5%), nausea (75%), chills (67.5%), myalgia (65%), vomit (65%) and loss of appetite (65%). Abdominal pain (60%), cough (45%), and diarrhea (32.5%) were also reported by many case-patients. Only 7.5% case-patients had a skin rash (Figure 3). We also built map of case distribution. The results showed that 19 (47.5%) of confirmed case-patients clustered geographically in West Semarang Sub-district (Figure 4).

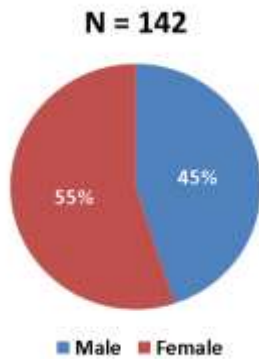


Fig. 1. Positive case distribution based on sex

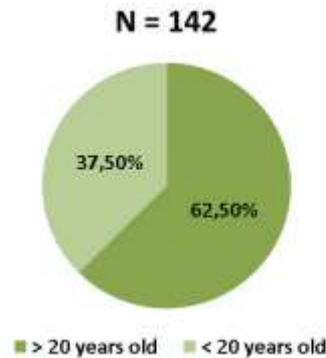


Fig. 2. Positive case distribution based on age

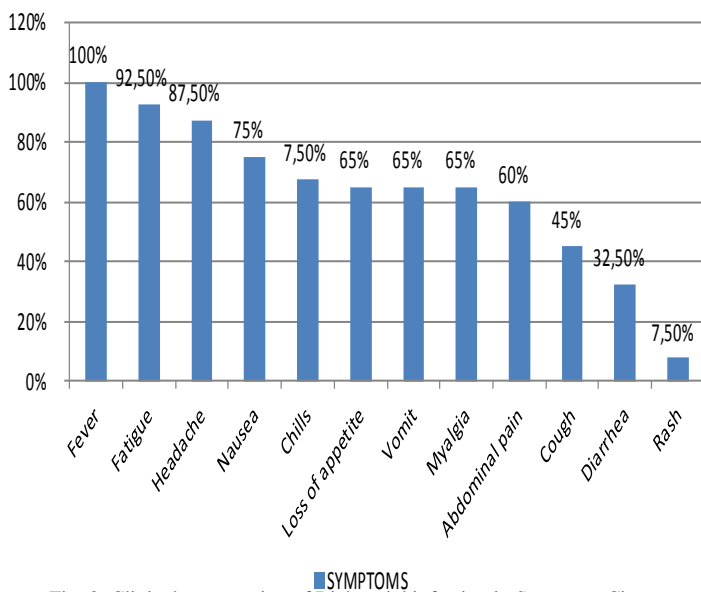


Fig. 3. Clinical presentation of Rickettsial infection in Semarang City

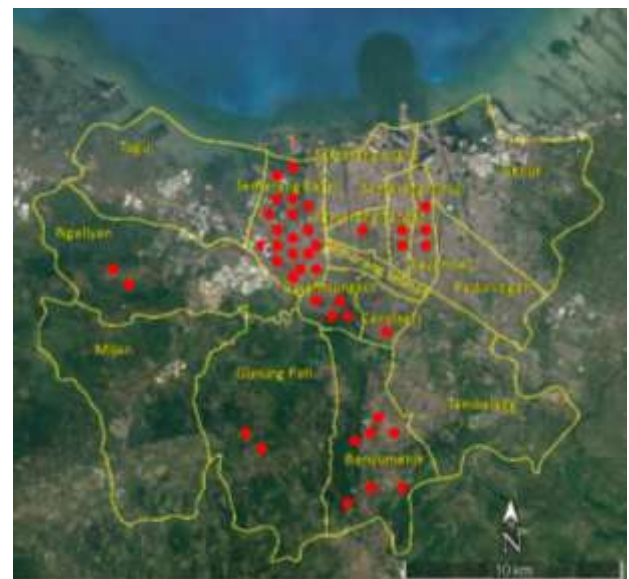

Fig. 4. Mapping of Rickettsial infection cases in Semarang City

IV. DISCUSSION

Although antibacterial therapy for Rickettsial infection is easily available and low-cost, this disease still causes severity and also death in various age groups. The main challenge in the diagnosis of Rickettsial infection is the initial symptoms that are not specific and are similar to the symptoms of other diseases so that Rickettsial infections are often under diagnosed [8]. Before this research study, murine typhus detection was very limited to be reported in Semarang City, and less than 25 cases were identified in 2009 [5]. This investigation indicated that a total of 40 patients had Rickettsial infection with acute fever. These findings represented the first semi large-scale case detected in Semarang City.

Detection of *Rickettsial* infection in this study was conducted using 17 kDa protein-based ELISA. The antigen gene of 17 Kda is a common antigen gene (htrA) found in both Typhus Group and Spotted Fever Group members of the *Rickettsia* [9]. This protein is a surface lipoprotein which is genus-specific for *Rickettsia* [10]. Therefore, in this study, the infection could not be distinguished whether it came from SFG (Spotted Fever Group) or TG (Typhus Group). The clinical characteristic and age distribution of patients reported in this study were similar to those found in previous murine typhus studies [2]. Previous research observed that the main clinical manifestations of the disease (observed in 80% of cases) included the usual triad: fever, headache, and rash [11]. This is consistent with our findings, but the rash was only 7.5%. Rickettsial infections are difficult to diagnose in the early phase because the non-specific symptoms caused by this infection affect the vasculature and present nonspecific signs and symptoms [12]. Most of those with a positive result were over 20 years old. Previous research reported that male-to-female ratio of Rickettsial infection patients in men and women was 0.67–2.12 [13], but was 1–1.2 in our study. The sex disparity may be related to men having more opportunities for outdoor activities [13].

Rickettsial infection is more commonly found in coastal areas because, in general, the conditions in the area support rodent habitat. Semarang City has abundant rodent population. Wahyuni and Yuliadi reported that rat density in Semarang City was quite high (24%) [14]. The result showed that 47.5% of confirmed case-patients clustered geographically in West Semarang Sub-district (Figure 4). This sub-district is located in the coastal area which directly adjacent to North Java Beach. From the findings of the study, a high risk of Rickettsial infection was revealed in this city. No deaths and complications were reported during the incidence in 2017. However, the findings could not fully describe the situation in Semarang, since the taken sample only included acute febrile patients without severity. Delay of treatment for murine typhus could increase the risk of complications and severity of disease [2]. The case management of Rickettsial infection should be initiated on the basis of clinical and epidemiologic considerations, while waiting for a laboratory confirmation of the diagnosis [2].

The limitation of this study is the small sample size which may have prevented a vigorous comparison of the data. Further studies with a larger number of samples is required

to have better comprehensive information about the dynamic relationship of human-animal disease. In this study, we can conclude that Rickettsial infection may now have been established in Semarang City area and this should be considered an ongoing public health threat. Continued public health education efforts are needed in Semarang City area regarding the emergence of Rickettsial infection with an emphasis on preventing contact with wild animals and controlling fleas on pets and around the house with appropriate methods. It is also important for Physicians to maintain an awareness in detecting and diagnosing suspected Rickettsial infection cases because timely treatment with the appropriate antimicrobial drug therapy is critical for limiting severe outcomes. Rickettsial infection may now have been established in Semarang City area and should be considered an ongoing public health threat.

ACKNOWLEDGMENT

This research was funded by the National Institute of Health Research and Development-Indonesian Ministry of Health. The author also would like to thank Dewi Marbawati for her guidance during the research process.

REFERENCES

- [1] G. P. Lara, K. R. Dzul-Rosado, J. E. Z. Velazquez, and J. Zavala-Castro, "Murine typhus: Clinical and epidemiological aspects Tifo Murino: Aspectos clinicos y epidemiologicos," *Colomb. Med.*, vol. 43(June), pp. 176–181, 2012.
- [2] J. Adjemian *et al.*, "Murine typhus in Austin, Texas, USA, 2008," *Emerg. Infect. Dis.*, vol. 16(3), pp. 412–417, 2010.
- [3] Z. Xu, X. Zhu, Q. Lu, X. Li, and Y. Hu, "Misdiagnosed murine typhus in a patient with multiple cerebral infarctions and hemorrhage: A case report," *BMC Neurol.*, vol. 15(1), pp. 1–5, 2015.
- [4] A. F. Azad, "Epidemiology of murine typhus," *Annu Rev Entomol*, vol. 35, pp. 553–569, 1990.
- [5] M. H. Gasem *et al.*, "Murine typhus and leptospirosis as causes of acute undifferentiated fever, Indonesia," *Emerg. Infect. Dis.*, vol. 15(6), pp. 975–977, 2009.
- [6] A. S. Joharina *et al.*, "*Rickettsia* pada pinjal tikus (*Xenopsylla Cheopis*) di Daerah Pelabuhan Semarang, Kupang dan Maumere," *Bul. Penelit. Kesehat.*, vol. 44(4), 2016.
- [7] Abcam, "General procedure and tips for ELISA assay requiring a secondary conjugated antibody." [Online]. Available: <http://www.abcam.com/protocols/indirect-elisa-protocol>.
- [8] Departement of Health and Human Services-CDC, "Diagnosis and management of tickborne *Rickettsial* diseases: Rocky Mountain Spotted Fever, Ehrlichioses, and Anaplosmosis-United States." [Online]. Available: <https://www.cdc.gov/mmwr/pdf/tr/rr5504.pdf>.
- [9] P. J. Blair *et al.*, "Characterization of spotted fever group *Rickettsiae* in flea and tick specimens from northern Peru," *J. Clin. Microbiol.*, vol. 42(11), pp. 4961–4967, 2004.
- [10] P. F. Policastro and T. Hackstadt, "Differential activity of *Rickettsia rickettsii* ompA and ompB promoter regions in a heterologous reporter gene system," *Microbiology*, vol. 140(11), pp. 2941–2949, 1994.
- [11] S. Wahyuni and Yuliadi, "Spot survey reservoir leptospirosis di beberapa kabupaten kota Di Jawa Tengah," *Vektora*, vol. 2(2), pp. 140–148, 2014.
- [12] D. H. Paris and J. S. Dumler, "State of the art of diagnosis of *Rickettsial* diseases," *Curr. Opin. Infect. Dis.*, vol. 29(5), pp. 433–439, 2016.
- [13] A. Aouam *et al.*, "Epidemiological, clinical and laboratory features of murine typhus in central Tunisia," *Med. Mal. Infect.*, vol. 45(4), pp. 124–127, 2015.
- [14] K. Chang *et al.*, "Murine typhus in Southern Taiwan during 1992–2009," *Am. J. Trop. Med. Hyg.*, vol. 87(1), pp. 141–147, 2012.