



Artery Research

ISSN (Online): 1876-4401

ISSN (Print): 1872-9312

Journal Home Page: <https://www.atlantis-press.com/journals/artres>

P2.01: HIGH RESOLUTION IMAGING OF SMALL ARTERIES IN THE HUMAN RETINA DURING HYPERTENSIVE RETINOPATHY

M. Paques, E. Koch, X. Girerd, F. Rossant, D. Rosenbaum, J. Benesty, J. Sahel, P. Chaumet-Riffaud

To cite this article: M. Paques, E. Koch, X. Girerd, F. Rossant, D. Rosenbaum, J. Benesty, J. Sahel, P. Chaumet-Riffaud (2013) P2.01: HIGH RESOLUTION IMAGING OF SMALL ARTERIES IN THE HUMAN RETINA DURING HYPERTENSIVE RETINOPATHY, Artery Research 7:3_4, 119–119, DOI: <https://doi.org/10.1016/j.artres.2013.10.063>

To link to this article: <https://doi.org/10.1016/j.artres.2013.10.063>

Published online: 14 December 2019

Aix for the junction ($p=0.001$), tube ($p=0.011$) and aortic arch ($p=0.016$) after adjustment to age sex and BSA. No independent relationship other functional parameters except for Pi and SCBP at the level of the descending aorta ($p<0.05$). **Conclusion:** Aortic diameters were found to be related strongly to age, BSA, sex, and weakly to Zci, Aix and DCBP.

P2 Methods 1

P2.01

HIGH RESOLUTION IMAGING OF SMALL ARTERIES IN THE HUMAN RETINA DURING HYPERTENSIVE RETINOPATHY

M. Paques², E. Koch², X. Girerd¹, F. Rossant³, D. Rosenbaum¹, J. Benesty², J. Sahel², P. Chauvet-Riffaud²

¹Cardiovascular Prevention Unit, Pitié Salpêtrière Hospital, Paris, France

²Clinical Investigation Center 503, Paris, France

³SEP, Paris, France

Objective: Morphological changes affecting small arteries are recognized surrogates of end-organ damage due to aging and/or hypertension. However, the corresponding structural modifications of the wall of microvessels are poorly known. Here, using adaptive optics (AO) infrared imaging, we analyzed the vascular microstructures in subjects with various degree of hypertensive retinopathy.

Methods: The wall-to-lumen ratio (WLR) of the superotemporal artery was measured in 40 normotensive or treatment-naïve hypertensive subjects using a semi-automated procedure. Areas of focal vascular damage were also analyzed.

Results: Intra- and interobserver reproducibility was high (ICC over 0.8 for all parameters measured). In treatment-naïve subjects, the WLR of the superotemporal artery (mean \pm SD 0.31 ± 0.08) was independently correlated with diastolic blood pressure ($p<0.01$), and lumen diameter ($p<0.01$). Neither focal arteriolar narrowing (FANs; ($n=10$) or arteriovenous nicking (AVNs; $n=12$) showed parietal thickening. Instead, at sites of FANs, a reduction of the outer diameter was consistently found, while at sites of AVNs venous narrowing and retinal opacification were observed distal to the arteriovenous interface. In addition, in four cases of AVNs the absence of arteriovenous contact could be unequivocally demonstrated.

Interpretation: AO imaging allows a reproducible analysis of the lumen diameter and parietal thickness of retinal vessels. Parietal thickness of retinal arterioles was correlated to blood pressure, but not focal lesions which appeared to involve either focal vasoconstriction and/or periarteriolar changes. AO imaging may thus contribute to a better understanding of end-organ damage linked to microvasculopathy.

P2.02

IN VIVO VISUALISATION AND RECONSTRUCTION OF THE MOUSE CEREBRAL VASCULATURE USING CONTRAST ENHANCED MICRO-CT

D. De Wilde¹, B. Trachet¹, C. Van der Donckt², B. Vandeghinste³, B. Descamps³, R. Van Hoven³, C. Vanhove³, G. R. Y. De Meyer², P. Segers¹

¹BioMMeda, Ghent University - IBItech, Ghent, Belgium

²Division of Physiopharmacology, University of Antwerp, Antwerp, Belgium

³MEDISIP-Infinity, Ghent University - iMinds - IBItech, Ghent, Belgium

Introduction: Recently, a mouse model was developed showing spontaneous plaque rupture leading to stroke (ApoE^{-/-}Fbn1^{C1039G+/-} mouse). However, a longitudinal follow-up of these mice was hampered by the lack of an accurate in vivo method to visualize the cerebral vasculature.

Methods: In this feasibility study, a female ApoE^{-/-}Fbn1^{C1039G+/-} and an ApoE^{-/-} (control) mouse (stable plaques) were fed a western-type diet for up to 20 weeks. At week 10, 15 and 20 after the start of the diet CT-scans were performed before and after injection of a gold-nanoparticle contrast agent (Aurovist[®], Nanoprobes, New York, USA). Image reconstruction was based on the iterative maximum-likelihood polychromatic algorithm, to reconstruct high quality images at 50- μ m. Post- and pre- contrast injection images were co-registered and subtracted, using 3D slicer, resulting in angiographic images. These images were segmented by executing a Frangi vesselness filtering, an isosurface extraction and a geodesic evolution step in VMTK.

Results: It was feasible to obtain a 3D-visualisation of the mouse cerebral vasculature (see figures for the ApoE^{-/-}Fbn1^{C1039G+/-} mouse) up to vessels of 0.15 mm diameter. Interestingly, at week 15 and 20 contrast agent from previous injections was still present in plaques (presumably taken up by macrophages), allowing us to determine plaque position and progression over time. More severe stenosis was observed in the ApoE^{-/-}Fbn1^{C1039G+/-} mouse compared to the control mouse.

Conclusions: The described in vivo method enabled us to generate detailed 3D reconstructions of the mouse cerebral vasculature, including presence of atherosclerotic plaques. Future work will include numerical models of the blood flow.

P2.03

AORTIC, BUT NOT RADIAL PRESSURE GIVES A MODEL INDEPENDENT ESTIMATE OF CEREBRAL ARTERY CRITICAL CLOSING PRESSURE

M. O. Kim¹, M. Butlin¹, Y. Li², F. Wei², J. Wang², M. O'Rourke^{1,2}, A. P. Avolio¹

¹Australian School of Advanced, Macquarie University Sydney Australia

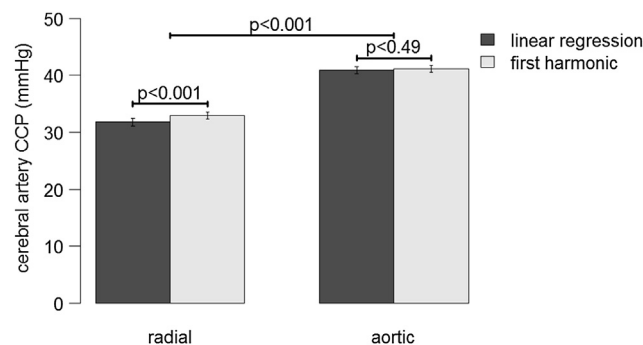
²Ruijin Hospital, Shanghai, St. Vincent's Clinic, Sydney

Objectives: Cerebral artery critical closing pressure (CCP) is an estimated parameter with no single accepted method of calculation. Variation between methods could be significant. This study investigates two models to estimate CCP using arterial blood pressure (BP) and middle cerebral artery flow velocity (FV) waveforms, quantifying the difference between radial and aortic BP as the BP input signal.

Methods: Suspected and untreated hypertensive subjects ($n=445$, 203 female, 50 ± 10 years, range 21 to 73 years old), referred to Ruijin Hospital in Shanghai, China, for 24-hours BP monitoring, were recruited. Radial BP and FV waveforms were acquired by applanation tonometry and transcranial Doppler respectively. Aortic BP waveforms were synthesised from the radial waveform using a validated transfer function (SphygmoCor[®]). CCP was estimated using the relationship between BP and FV waveforms by both linear regression (LR), and the first harmonic (H1) in Fourier decomposition. The difference between the two models was quantified if the BP waveform input signal was radial or aortic and compared by Student's paired t-test.

Results: Use of aortic instead of radial BP resulted in a 29% increase in estimated CCP using the LR model, and 25% increase using the H1 model (Figure, $p<0.001$). Radial BP resulted in variation between the models (4%, $p<0.001$). Aortic BP did not cause this variation (0.6%, $p=0.49$).

Conclusions: Aortic, but not radial pressure gave a model independent estimate of CCP. However, estimated CCP within a model was significantly different depending on whether radial or aortic pressure was used.



P2.04

ASSESSMENT OF BRACHIAL ARTERY REACTIVITY USING THE ENDOCHECK: REPEATABILITY, REPRODUCIBILITY AND PRELIMINARY COMPARISON WITH ULTRASOUND

L. M. Day, K. M. Maki-Petaja, I. B. Wilkinson, C. M. McEniery
University of Cambridge, Cambridge, United Kingdom

Objective: The Endocheck, embedded within the Vicorder device, uses cuff-based, pulse volume (PV) displacement to record brachial PV waveforms at baseline, and during reactive hyperaemia. The aim of this study was to assess the utility of the Endocheck method.

Methods: The study consisted of two parts. Part 1: Healthy volunteers ($n=9$) were studied twice, separated by 24hours. Each visit consisted of two studies, 30min apart, where, after 10min supine rest, brachial BP was assessed and PV waveforms recorded for 10sec (baseline). A cuff placed distally around the forearm was then inflated to 200mmHg for 5min. Following cuff-release, PV waveforms were recorded for 3min. The square root of the ratio of peak:baseline PV during hyperaemia ($\sqrt{V2/V1}$) was calculated. Part 2: Healthy volunteers ($n=16$) were studied once. Brachial artery responses were assessed simultaneously in both arms, using ultrasound (right arm) and Endocheck (left arm), following a similar protocol as above.