ATLANTIS PRESS

Advances in Health Sciences Research, volume 33

Proceedings of the 4th International Conference on Sustainable Innovation 2020–Health Science and Nursing (ICoSIHSN 2020)

Complex Esthetics and Endodontic Treatment With Porcelain Fused to Metal Crown Supported by Fiber Post and Smart Dentin Replacement as a Core for Anterior Upper Maxilla

Erma Sofiani[1,*]

[1] *Department of Dentistry, Faculty of Medicine and Health Sciences, Universitas Muhammadiyah Yogyakarta*
[*]*Corresponding author. Email: e_sofiani@yahoo.com/ermasofiani@umy.ac.id*

ABSTRACT

Background. Restoration of endodontically treated tooth may bring more risks of fracture than a vital tooth. The decision making should be taken based on clinical appearance and consideration. This case report informed crown restoration with fiber post and Smart Dentin Replacement after root canal treatment for anterior upper maxilla teeth. Case report. A 24-year-old female visits the dental hospital complaining of pain in the anterior upper teeth. The pain arose spontaneously and got worse when chewing something ever since three days ago. Clinical examination showed central right incisor, temporary bridge central left and missing left lateral incisor. The patient felt pain during the percussion and vitality test. Radiograph examination revealed diffuse lesion 4 mm around apical upper right incisor a upper left incisor. Pulpectomy had been made on the first visit to reduce the pain. After that, root canal treatment had made by multiple visits. The biomechanical preparation was conducted with a stepback technique followed by the root canal medication was scheduled in the next visit. Obturation after the root canal had been sterilized. Root canal restoration planned to be achieved using fiber post and porcelain fused to metal crown. Conclusion, endodontic treated teeth in the anterior region should consider being restored with esthetics materials. Fiber post could be used to restore endodontically tooth followed by porcelain fused to the metal crown to improve the function of mastication as well as esthetics. One month of evaluation revealed good condition without any complaints, pain, and clinical abnormalities.

Keywords: *fiber post, root canal treatment, smart dentin replacement introduction*

1. INTRODUCTION

Caries in the anterior tooth region should be treated with a proper treatment plan. Restoration material has been developed to treat root canal and crown restoration. The decision making should be taken based on clinical appearance and consideration. Endodontically treated tooth may bring more risks of fracture than vital tooth[1]. Direct restoration can be used as the restoration choice for small cavities. However, indirect ceramic crowns give more natural esthetic results while preventing discoloration that might appear in direct restoration[2]. This case report aims to discuss root canal treatment and post endodontic restoration to replace acrylic resin restoration.

A female patient of 24 years old visited the dental hospital complaining of severe pain in the anterior upper jaw. The pain arose spontaneously and got worse when chewing. Clinical examination showed central right incisor had an acrylic restoration, temporary restoration found in the right lateral incisor, temporary bridge central left incisor and missing left lateral incisor. The patient felt a long period of pain during the percussion test. The patient reported that she had made many visits to the street dentist since she was kids for extraction and filling. Radiograph examination revealed a diffuse lesion 8mm around the upper right incisor and upper left incisor. There was no past medical history reported.

The purpose of the treatment was to remove the pain and improve the aesthetic for anterior upper teeth. Pulpectomy has been made on the first visit to reduce the pain. Biomechanical preparation followed by medication of root canal was scheduled for the next visit. Obturation after a root canal had been sterilized. Root canal restoration planned to be achieved using fiber post and porcelain fuse to metal crown.

Figure 1 Radiograph view of upper incisor

Figure 2 Clinical view of pre treatment

Figure 3 Pulpectomy

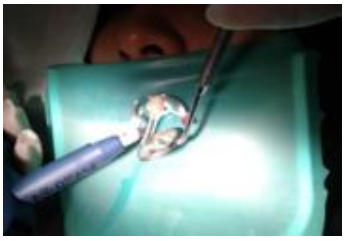

Figure 4 Rewalling of remaining tooth structure

2. CASE MANAGEMENT

2.1. Pulpectomy

The patient was anesthetized using 2% Lidocaine 1:100 (2ml), and a pulpectomy performed. Rewalling in the cervical area was achieved using SDR to support the remaining sound tooth. Chresopen was applied in a pulp chamber for medication. The patient was scheduled to have another visit for a root canal treatment

2.2. Root Canal Treatment

Root canal treatment had made by multiple visits. The working length of three teeth was measured using Propex (Dentsply) and confirmed by radiograph imaging. Biomechanical preparation was conducted using a niti file with the step-back technique. NaOCl 0,5% and chlorhexidine were performed for root canal dressing. The medication was made using chresophen for three days and replaced with CaOH paste for one week. Bacterial test made using hydrogen peroxide, when it showed negative obturation made with lateral condensation using gutta-percha and sealing material endhometason. The temporary restoration used Fuji IX (GC, Japan) capsule mixing. Follow-up was done for 2 months, and the patient was scheduled for the final restoration.



Figure 5 Initial apical file

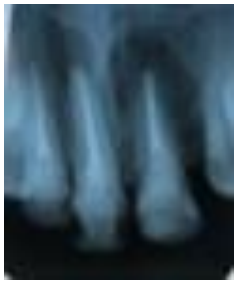

Figure 6 Final endodontic treatment

Figure 7 Temporary filling Fuji IX capsule

Figure 8 Core build up

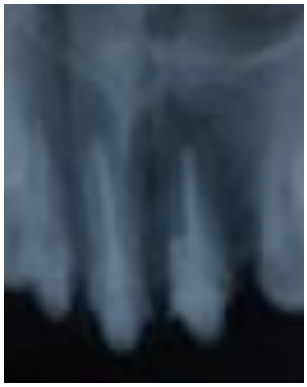

Figure 9 Radiograph examination

Figure 10 Final restoration

2.3. Post and Crown Restoration

The temporary restoration was removed using round burs and start x (Dentsply) until it reached gutta-percha. Gates Glidden drill was performed with measured working length. Precision peaso reamer from Dentsply was used for finishing the preparation of the root canal. The red ribbon was used for tooth 11, the yellow ribbon for tooth 12, and peaso reamer #3 for tooth 21 planned to be filled with Smart Dentine Replacement. Restoration of the root canal was made using esthetics fiber for tooth 11 and 12 with red and yellow size consecutively. Tooth 21 was restored with Smart Dentine Replacement. The root canal was disinfected using chlorhexidine, etched with 35% phosphoric acid for 15 seconds, washed with distilled water and dried with a paper point. A two-step and rinse adhesive system (Optibond S, Kerr) was applied for the root canal according to instructions and cured for 20 seconds, while priming was applied in the root canal wall and the surface of the post. Dual cured resin cement (Rely X, 3M ESPE) was applied in the root canal wall, and the fiber post was inserted then cured for 20 seconds. Smart Dentine Replacement was used to build the core. The prepared tooth was impressed using elastomer (polyvinilxiloxane) heavy body and light body impression. Porcelain fused to metal restoration was made for final restoration with Fuji I glass ionomer cement as a luting agent. The patient had not visited crown insertion.

3. DISCUSSION

Caries that affect the anterior tooth may bring psychological problems, especially in young people. When caries reached the pulp, there would be many considerations to treat the tooth. Extraction might be one of the choices; then it can be continued with a fixed prosthesis or implant[3]. However, a fixed prosthesis would harm the abutment teeth pulp since it had a great pulp chamber in young patients. An unidentification to previous treatment of this case made it more challenging to treat the tooth. Otherwise, the clinical examination had already shown a great lesion in the periapical area that had to be removed or reduced to improve the teeth' function. A root canal should be made to improve the esthetics and surrounding damaged tissue. Failure in endodontic treatment could be caused by bacterial recontamination from the oral cavity due to the loss of temporary restoration[4]. This failure may result in extraction. Dentists should make prompt and effective permanent restoration when endodontic treatment is completed to avoid bacterial recontamination. Filling into the whole pulp chamber suggested temporary restoration such as zinc oxide eugenol, calcium sulfate cement, and resin-modified glass ionomer. Glass ionomer was used for temporary restoration after obturation; it sealed coronal to 1mm below cement enamel junction to assure the root canal from bacterial recontamination. The temporary filling was found in complete sealing after 2 months. Furthermore, root canal preparation was made for the final restoration.

Restoring root canal using posts was reported to have a good result to improve esthetics, especially in the anterior region[5]. Elif reported that endodontically treated anterior tooth could be restored using fiber-reinforced composite followed by a full ceramic crown. 3 years of follow-up revealed function preservation in surrounding tissue and excellent esthetics result[6]. This study on fiber-reinforced composite had been chosen as its mechanical properties

similar to dentine and simple treatment rather than custom dowel core. Smart Dentine replacement was also used for core built up since it could replace the dentin and support the remaining sound tooth structure. Morgano et al. stated that even though many new materials had already been discovered for root canal restoration, the prognosis might depend on the sound tooth's biomechanical principles rather than the material itself1. Core restoration was needed for endodontically treated tooth to replace dentine structure loss, provide internal support, and against tooth fracture. The remaining sound tooth structure had an important role in the crowned endodontically treated tooth's long success to provide adequate support[7]. Endodontic treated roots in the anterior region should consider being restored with esthetics materials. Fiber post can be used to restore endodontically root canals followed by porcelain fused to the metal crown to improve anterior tooth function of mastication and esthetics[8].

4. CONCLUSION

Endodontic treated teeth in the anterior region should consider being restored with esthetics materials. Fiber post could be used to restore endodontically tooth followed by porcelain fused to the metal crown to improve the function of mastication as well as esthetics. One month of evaluation revealed good condition without any complaints, pain, and clinical abnormalities.

ACKNOWLEDGMENTS

We would like to thank our female patient for allowing us to share her details and Academic Dental Hospital, Universitas Muhammadiyah Yogyakarta, for supporting our research.

REFERENCES

[1] S. M. Morgano, A. H. C. Rodrigues, and C. E. Sabrosa, Restoration of endodontically treated teeth. Dent Clin N Am 48 (2004) 397-416.

[2] G.Cavalli, Restoration of Endodontically treated teeth. Elsevier Mosby, St Louis, Missouri, 2009, pp. 490-528.

[3] A. Savi, M. Manfredi, M. Tamani, M. Fazzi, S. Pizzi, Use of customized fiber posts for the aesthetic treatment of severely compromised teeth: a case report. Dental Traumatology 24 (2008) 671-675.

[4] E. Sornkul, J. G. Stannard, Strength of roots before and after endodontic treatment and restoration, J Endod 18 (1992) 440-443.

[5] A. Signore, S. Benedicenti, V. Kaitsas, M. Barone, Simplified technique for rebuilding a post and core foundation with a preexisting crown: a case report. Quintessence Int, 41 (2010) 205-207.

[6] O. Elif, B. Sukran, Esthetics restoration procedures for endodontically treated anterior root. Clin Dent and Research, 35(2) (2011) 28-34.

[7] S. Cohen, Cohen’s pathways of the pulp. Eleventh edition. Hargreaves KM, Berman LH, Rotstein I, editors. Elsevier, St. Louis, Missouri, 2016, pp. 907.

[8] F. Mannocci, J. Cowie, Restoration of endodontically treated teeth. British dental journal., 216(6) (2014) 341-346.