

# Biochemical Changes of Liver and Kidney After Bone Graft Implant from Black Devil Snail (*Faunus ater*) Shell Material

Erwin Erwin<sup>1\*</sup>, T. Fadrial Karmil<sup>1</sup>, Teuku Zahrial Helmi<sup>1</sup>, Nuzul Asmilia<sup>1</sup>,  
Muhammad Isa<sup>1</sup>, Wahyu Eka Sari<sup>1</sup>, Budiando Panjaitan<sup>1</sup>, Sugito<sup>1</sup>, Hathalia Y. Utari<sup>2</sup>,  
Azzalia N. Diva<sup>2</sup>, Astri Wulandari<sup>3</sup>

<sup>1</sup>Faculty of Veterinary Medicine, Universitas Syiah Kuala, Aceh, Indonesia

<sup>2</sup>Students of Faculty of Veterinary Medicine, Universitas Syiah Kuala, Aceh, Indonesia

<sup>3</sup>Post graduate student of Faculty of Veterinary Medicine, Universitas Syiah Kuala, Aceh, Indonesia

\*Corresponding author. Email: erwin2102@unsyiah.ac.id

## ABSTRACT

Biochemical changes in blood can be used as an indicator in liver and kidney disorder. This study aims to discover the changes of serum glutamic oxaloacetic transaminase (SGOT), serum glutamic pyruvic transaminase (SGPT), creatinine and blood urea nitrogen (BUN) levels after the implant of black devil snail shell powder in rabbits. This study used 6 male rabbits, aged 6-8 months and weighted 1.5-2 kg which were divided into 2 groups. Surgical procedure was done sterile and aseptically by creating defect in the left area of femur diaphysis with the size of 0.5 mm<sup>2</sup> and depth reached to canalis medullaris. Group 1 (G1) was not implanted and left to heal on its own, while group 2 (G2) was implanted with 0.25 g of black devil snail shell powder. Blood sample was withdrawn from auricular vein in day 0 before surgery, and day 7, 14, 28, 56 after surgery. The SGOT and SGPT level increased in day 7 after surgery and were significantly different between groups. The BUN level increased in day 14 after surgery, while creatinine increased in day 7 with no significant differences found between groups. The biochemical changes of liver and kidney is still in its normal range, so cue shell powder has the potential to be developed as natural hydroxyapatite.

**Keywords:** SGOT, SGPT, creatinine, *Faunus ater*

## 1. INTRODUCTION

Bone fracture is damage to the bone that occurs due to a pressure on the bone [1]. One method to help bone healing process after fracture is the use of a bone replacement material in the form of bone graft [2]. Limited procurement of implant materials has triggered developmental research in biomaterials, especially bone graft biomaterial such as hydroxyapatite (HA). The HA can be produced from natural ingredients that contains calcium carbonate (CaCO<sub>3</sub>) [3] such as mammalian bones, shells, coral reefs and egg shells [4]. the shell of Mollusc (especially gastropods) such as *Faunus ater* usually contains CaCO<sub>3</sub> [5].

Black devil snail (*Faunus ater*), that in Aceh known as cue, is a brackish water snail that has a long, black shell. The snail is used as a food by local

populations. The processed shells, however, were discarded so that they can cause environmental pollution. The use of shells for other purposes, such as a natural source for HA, will increase their environmental safety and economic value [6]. The bone graft created from any type of materials must be biocompatible (can be accepted by body) to avoid potential failure from toxic effects, host cells rejection and biologic malfunction [7]. The implant of incompatible materials into the body might trigger toxicity reactions that lead to tissue damage in the liver and kidney [8,9].

When liver cells are damaged, the nucleus and cytoplasm are swollen so that all cell contents come out into the extracellular area of the liver cells, resulted in increased GOT/GPT levels in the blood [10]. In the kidney, the parts that are vulnerable to toxicity exposure is glomerulus. The decreasing

glomerular function is characterized by a decrease in the glomerular filtration rate, so that metabolic waste substances in the form of creatinine and BUN increase in blood [11]. This study aims to determine the change in the SGOT, SGPT, creatinine, and BUN levels after the implant of black devil snail powder. The results of this study are expected to provide information about the biocompatibility of *Faunus ater* powder as a candidate for natural HA source for biomaterial.

## 2. MATERIALS AND METHODS

### 2.1. Ethical Approval

All methods used in this study has been approved by the Ethical Committee of Experimental Animals of Veterinary Faculty of Universitas Syiah Kuala No. 48/KEPH/X/2019.

### 2.2. Preparation of Black Devil Snail Powder

The shells of black devil snail collected from the waste were washed, cleaned, and oven-dried at 200 °C for 48 hours, and for another 24 hours at 180°C until completely dried. The dried shells were mashed using a mortar and sieved with the size of 100-mesh. The mineral content of the powder was determined using the Atomic Absorption Spectrometry (AAS) method. Shell powder aliquots, 0.25 g, were prepared and sterilized in the oven.

### 2.3. Research Procedure

This study used 6 male rabbits, with body weight (BW) of 1.5-2 kg and aged 6-8 months. All rabbits were acclimatized for 2 weeks, given ciprofloxacin (Ciprofloxacin®, Hexpharm Jaya, Indonesia) of 15 mg/kg BW per oral twice a day for 6 consecutive days and single subcutaneous (SC) injection of the antiparasite Ivermectin (Intermectin®, Interchemie, Holland) of 0.2 mg/kg BW [12]. Feed and water were given *ad libitum* [13]. All rabbits were kept in individual cages with a size of 50 cm x 50 cm.

All rabbits were fasted for 8 hours, given 0.05 mg/kg BW SC of atropine sulphate (Atropine®, Ethica, Indonesia) as pre-medication and a combination of 10% ketamine (Ketamil®, Troy Laboratories PTY Limited, Australia) of 35 mg/kgBW IM and 2% xylazine (Xyla®, Interchemie, Holland) of 5 mg/kg IM as general anaesthesia [13]. The lateral femur area was shaved, disinfected with 70% alcohol and iodine circularly. The skin of femur area over the musculus vastus lateralis was incised. The muscles were prepared and retracted until the femur bone is found. The diaphysis area of the femur bone was perforated with a drill until reaching the bone marrow with a diameter of 0.5 mm. The perforated area were then implanted with 0.25 g of the powder of black

devil snail shell (G2) or just cleaned with sterile NaCl (G1, control). Musculus vastus lateralis and fascia were reattached with a simple continuous suture using a polyglactin 3.0 USP thread (Hinglact®, Hicare, India). The skin was sutured with simple interrupted sutures using USP 3.0 silk thread (Silkam®, Romed Medical, Indonesia). Post-surgery treatment was done with doxycycline antibiotics (TY-Doxy-10®, Tianyuan, China) of 10 mg/kg BW twice a day for 5 consecutive days. Whole blood, 2 ml, was withdrawn from the auricular vein of each rabbit using a syringe and plain vacuum collection tube. Blood sampling was done on before (day 0) and after surgery (day 7, 14, 28, and 56). All collection tubes were tilted until the serum was formed. The serum was used for the GOT, GPT, creatinine and BUN examination using a biochemical analyser (Yuesen Med®, Guangzhou Yueshen Medical Equipment Co., Ltd., China).

### 2.4. Data Analysis

Data obtained were analysed with multivariate analysis continued with Duncan test using SPSS 25 for Windows.

## 3. RESULTS AND DISCUSSION

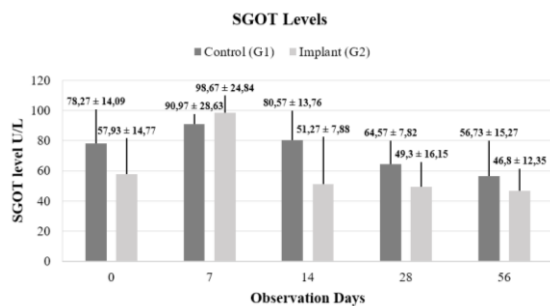
The results of AAS analysis showed that the powder of black devil snail powder contains calcium (Ca) 541.30 mg/25 g powder and iron (Fe) 6.35 mg/25 g powder.

### a. Liver Biochemical Serum Levels

The SGOT levels before and after treatments showed significant differences ( $P < 0.05$ ) between treatment groups and observation time. Average SGOT in G1 increased ( $90.97 \pm 28.63$  U/L) in day 7 and slowly decreased until the end of observation with no significant differences ( $P < 0.05$ ) observed between observation times. Average SGOT in G2 started to increase in day 7 ( $98.67 \pm 24.84$  U/L) with significant differences with day 14, 28 and 56 after implant. According to Fielder [14], the normal SGOT level in rabbit is 35-130 U/L. The changes in SGOT levels found in both G1 and G2 groups were still in the normal range. The average SGOT levels in G1 and G2 shown in Figure 1.

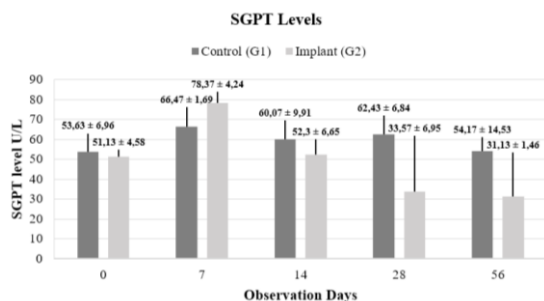
In normal circumstances, SGOT can exist in the plasma due to increased cell membrane permeability. The change in cell membrane permeability in implant group tended to be higher than those in the non-implant group. The changes in cell membrane permeability and integrity might cause cell damage, triggering intracellular enzymes such as SGOT exit into the extracellular space and then enter bloodstream, resulted in increased serum SGOT level [15]. The increasing level of SGOT in day 7 (first week) is

thought related to cell inflammation, resulting in the changes of cell membrane permeability which triggers the release of SGOT into the bloodstream. In day 14 (second week) SGOT began to decrease, presumably because the inflammatory process had been replaced by the bone repair phase. At the stage of new bone formation, inflammatory process (inflammation) occurs between the first week and second week which will cause the formation of blood clots. The entry of foreign bodies will trigger inflammation reacts from the infiltration of inflammatory cells such as neutrophils, macrophages and phagocytes [16].



**Figure 1** Average SGOT level (±SD) of rabbits in G1 (control) and G2 (implanted with the powder of black devil snail).

Fielder [14] stated normal SGPT levels in rabbit ranges from 45-80 U/L. The SGPT levels in both groups are shown in Figure 2.



**Figure 2** Rabbit's SGPT level (average±SD) in G1 (control) and G2 (black devil snail shell powder implant) every observation time.

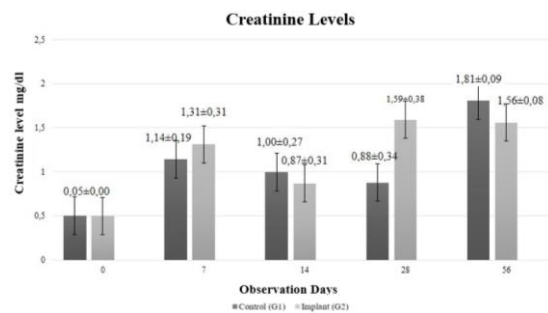
Total SGPT levels between treatment groups and observation times showed significant differences ( $P < 0.05$ ). The fluctuation of SGPT levels in G1 was still within the normal range and insignificant ( $P > 0.05$ ) according to observation. The average SGPT levels of G2 after implant, on the other hand, increased in day 7 ( $78.37 \pm 4.24$  U/L) and was significantly different ( $P < 0.05$ ) from those in day 14, 28 and 56. Increased SGPT level the implant of black devil snail powder might related to the presence of the implant material as a foreign object, causing causes the changes in the permeability of the cell membrane that in turn increase the SGPT level. This is in

agreement with Ardhiyanto [16], the increase of SGPT level in the first week is due to changes in cell membrane permeability caused by cell inflammation in the inflammatory phase of bone formation. The SGOT decreases again in the second week because the bone repair phase begins to form.

Disorders in liver begin with changes of cell membrane permeability which then result in cell death. As for the causes of increasing SGPT level in the blood include liver cell disorders. Disorders of the liver cells cause the nucleus and cytoplasm to swell, so the enzymes will exit the liver cells to the extracellular area [17].

**b. Kidney Biochemical Serum Levels**

The creatinine levels in G1 and G2 did not show a significant difference ( $P > 0.05$ ). G1 creatinine level increased in day 56 which was significantly different ( $P < 0.05$ ) from that in day 7 and 28, whereas G2 creatinine level increased in day 28 which was significantly different ( $P < 0.05$ ) from those in day 7 and 14. The increased creatinine levels between G1 and G2, however, was still within normal ranges. Normal rabbit creatinine values range from 0.5-2.5 mg/dl [14]. The changes in creatinine levels between treatment groups are presented in Figure 3.

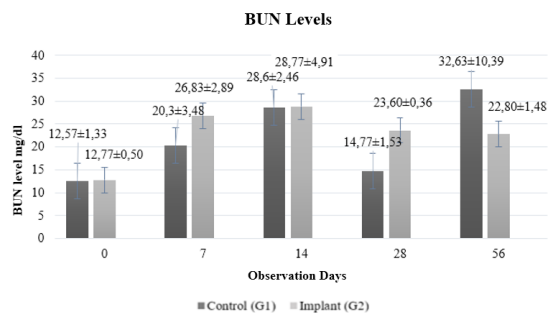


**Figure 3** Rabbit's creatinine level (average±SD) in G1 (control) and G2 (cue shell powder implant) every observation times..

Price and Wilson [18] stated that bone healing begins to occur at 5-6 weeks after fracture. Healing is initiated by ossification process. Osteoblast cells build bone by actively producing osteocytes which act as bone matrix. The increase of creatinine in day 56 (G1) was triggered by increasing osteoblast activity in the ossification process, resulting in an increase in muscle mass metabolism. Increased muscle metabolism causes creatinine levels to increase [19]. Kaewloet [20] stated the bone healing process in the first two weeks is inflammatory phase and the implant material will work after going through the inflammatory phase. The implanted black devil snail shell powder begins to work in the repair phase by stimulating growth from inducing stem cells and osteoblasts to adhere, live and develop in the bone defect so that the defect will be stabilized with callus which will become bone [21].

Callus formation was faster in G2 compared to in G1. This occurred because the powder of black devil snail shell replaced the lost bone substance. The increased creatinine levels in day 28 were caused by the powder started to work after going through the inflammatory phase. The content of black devil snail shells such as protein, iron and phosphate when metabolized in the body will produce waste in the form of creatinine. Phosphate content of black devil snail shell powder will bind to creatine while iron will bind to bone myoglobin. At week 3-4 bone healing turn into calcification process that characterized by increased osteoblasts and fibrous tissue [22].

Normal BUN levels in rabbits are 12.1-34.1 mg/dl [14]. The BUN levels between G1 and G2 did not show a significant difference ( $P>0.05$ ). BUN level in G1 increased in day 56 which was significantly different ( $P<0.05$ ) from that in day 28, while in G2 the increase of BUN occurred in day 14 which was significantly different ( $P<0.05$ ) from those in day 28 and 56. The changes in BUN levels occurred in both groups (Figure 4) were still within the normal range.



**Figure 4** Rabbit's BUN level (average±SD) in G1 (control) and G2 (cue shell powder implant) every observation time.

The increased BUN level of G1 in day 56 is probably caused by natural healing process of bone defect. Physiological NaCl were used only to clean bone powder after bone drilling. Healing bone defects requires a lot of energy by carrying out protein catabolism and muscle mass metabolism as a form of cell degeneration. Increased protein catabolism and muscle mass metabolism produce BUN as a waste product and caused higher levels in the blood [23]. Cell degeneration is a condition when the body is damaged due to loss of normal cell structure [24].

Kaewloet [20] stated, inflammatory phase can last 1-2 weeks post-surgery. In the inflammatory phase, inflammatory cells such as macrophages, lymphocytes and neutrophils will increase and cause muscle mass metabolism to increase. Implant materials will work in the body after passing the inflammatory phase. Vetlearn [25] stated that BUN levels in the body are influenced by the amount of protein that enters the body, damage to the kidney, toxic effects in kidney, dehydration and shock.

The use of black devil snail shell powder as an implant basically because of potential as hydroxyapatite. It contains calcium carbonate, a mineral similar to bone mineral so it can be accepted in the body and chemically binding to body tissues. Changes of creatinine levels after cue powder implants were still within normal ranges. Based on the observation of creatinine levels, the use of black devil snail shell powder as implant material did not cause kidney function problems.

#### 4. CONCLUSION

Biochemical changes of liver and kidney after implant of black devil snail shell powder are within the normal range so that powder has the potential to be used as natural source of hydroxyapatite.

#### AUTHORS' CONTRIBUTIONS

EE, TFK and TZH are responsible for the study concept, NA MI, and WES are responsible for the laboratory work, BP, SS, HYU, AND and AW are responsible for field work and data analysis. The manuscript was written by EE, TFK and WES.

#### ACKNOWLEDGMENTS

The authors are highly thankful to the Rector of Universitas Syiah Kuala for Associate Professor Research Grant No. 53/UN11.2.1/PT.01.03/DRPM/2020.

#### REFERENCES

- [1] P.A. Grace, N.R. Borley, At a glance ilmu bedah, Erlangga, Indonesia, Surabaya, 2006.
- [2] H. B. Ardhiyanto, Peran hidroksiapatit sebagai *bone graft* dalam proses penyembuhan tulang. Stomatognathic, Jurnal Kedokteran Gigi 8(2) (2011) 118-121.
- [3] M. Fitriawan, S.R. Amalia, B.A. Saputra, *et al.*, Sintesis hidroksiapatit berbasah dasar tulang sapi dengan metode presipitasi sebagai kandidat pengganti *graft* berdasarkan compressive strength. Prosiding Seminar Nasional Mahasiswa Fisika (SNMF), FMIPA, Universitas Negeri Semarang, Indonesia, Semarang. 2014 318-322.
- [4] S. Syamsuddin, Sintesis dan karakterisasi biokeramik tulang sebagai bahan implant dengan metode sintering. INTEK: Jurnal Penelitian. 4(2) (2017) 84-86 DOI: <http://dx.doi.org/10.31963/intek.v4i2.147>.
- [5] C. Soido, M.C. Vasconcellos, A.G. Diniz, J. Pinheiro, An improvement of calcium determination technique in the shell of molluscs.

- Brazilian Arch. Biol.Technol. 52(1) (2009) 93-98  
DOI: <https://doi.org/10.1590/S1516-89132009000100012>.
- [6] M.F. Alif, S. Arief, Yunita, Penjernihan air gambut dengan hidroksiapatit yang disintesis dari limbah cangkang langkitang (*Faunus ater*). Jurnal Kimia Unand 6 (2017) 40-44.
- [7] G.S. Kartono, Widyastuti, H.W. Setiawan, Biokompatibilitas hidroksiapatit *graft* dari cangkang kerang darah (*Anadara granosa*) terhadap kultur sel fibroblas. Jurnal Kedokteran Gigi 8(1) (2014) 1-8.
- [8] T. Agustina, Kontaminasi logam berat pada makanan dan dampaknya pada kesehatan. Jurnal Teknoba 1(1) (2014) 53-65  
DOI: <https://doi.org/10.15294/teknoba.v1i1.6405>.
- [9] R.G.P. Panjaitan, E. Handharyani, Chairul, Masrani, Z. Zakiah, W. Manalu, Pengaruh pemberian karbon tetraklorida terhadap fungsi hati dan ginjal tikus. Makara Kesehatan 11(1) (2007) 11-16.
- [10] H. Kudo, S. Suzuki, A. Watanabe, H. Kikuchi, S. Sassa, S. Sakamoto, Effects of colloidal iron overload on renal and hepatic siderosis and the femur in male rats. Toxicology 246(2-3) (2008) 143-147.  
DOI: <https://doi.org/10.1016/j.tox.2008.01.004>
- [11] I. Wijaya, I.P. Miranti, Patologi Ginjal dan Saluran Kemih, Badan Penerbit Universitas Diponegoro, Indonesia, Semarang, 2005.
- [12] D.C. Plumb, Plumbs veterinary drug handbook. 6<sup>th</sup> Ed. Blackwell publishing Professional, Iowa, USA, 2008.
- [13] E. Ivey, J. Morrisey, Therapeutics for rabbits. Veterinary Clinics of North America, Exotic Animal Practice 3 (2000) 183-220.
- [14] S.E. Fielder, Serum biochemical reference ranges. MSD Veterinary Manual. Merck Sharp & Dohme Corp., A subsidiary of Merck & Co. Inc. USA, Konilworth NJ, 2019.
- [15] A.D. Apriana, Pengaruh lama paparan CO terhadap kadar ALT (Alanine aminotransferase). Jurnal Majority. 4 (2015) 139-142.
- [16] H.B. Ardhiyanto, Peran hidroksiapatit sebagai *bone graft* dalam proses penyembuhan tulang. Jurnal Kedokteran Gigi. 8 (2011) 118-121.
- [17] E. Erwin, R. Rusli, A. Amiruddin, E. Etriwati, M. Isa, A. Harris, Y. Astuti, Biokimia darah hati dan ginjal setelah implan *wire* SS316L dan *wire* alternative. J. Vet. 21 (2020) 31-37.
- [18] S.A. Price, L.M. Wilson, Patofisiologi Konsep Klinis Proses-proses Penyakit, Edisi 6, Penerbit Buku Kedokteran EGC, Indonesia, Jakarta, 2005.
- [19] D.C. Dugdale, Creatinine blood test, National Library of Medicine, USA, 2013  
<https://medlineplus.gov/ency/article/003475.htm>
- [20] L.N. Kaewloet, The correlation between affecting factors and wound healing rate in diabetic foot ulcer. India, Faculty of Graduate Studies. Mahidot University, 2008.
- [21] F. Mahyudin, D.N. Utomo, H. Suroto, T.W. Martanto, M. Edward, I.L. Gaol, Comparative effectiveness of bone grafting using xenograft freeze-dried cortical bovine, allograft freeze-dried cortical New Zealand white rabbit, xenograft hydroxyapatite bovine, and xenograft demineralized bone matrix bovine in bone defect of femoral diaphysis of white rabbit: Experimental study in vivo. Int. J. Biomater. 7 (2017) 15-23  
DOI: <https://doi.org/10.1155/2017/7571523>.
- [22] E.J. Mackie, Y.A. Ahmed, L. Tatarczuch, K-S. Chen, S. Mirams, Endochondral ossification: How cartilage is converted into bone in the developing skeleton, Int. Jurnal. Biochem. Cell Biol. 40 (2008) 46-62  
DOI: <https://doi.org/10.1016/j.biocel.2007.06.009>.
- [23] Y. Siagian, Status nutrisi pasien *hemodialisa* di rumah sakit umum daerah. Jurnal Keperawatan Silampari 2 (2018) 300-314  
DOI: <https://doi.org/10.31539/jks.v2i1.320>.
- [24] N. Lindseth, Pathophysiology Tulang *dalam*; Konsep Klinis Proses-Proses Penyakit, Volume I. Edisi 6, Jakarta, Indonesia, Penerbit Buku Kedokteran. EGC, 2006.
- [25] Vetlearn, Test and procedures: BUN and Creatine Levels. Vetstreet. 1-2. 2011.
- [26] C. Özkan, A. Kaya, Y. Akgül, Normal values of haematological and some biochemical parameters in serum and urine of New Zealand white rabbits. World Rabbit Sci. 20 (2012) 253-259.
- [27] B.S. McAllister, K. Haghightat, Bone augmentation techniques, J. Periodont. 78 (2007) 377-396.
- [28] M.P. Ramirez-Fernandez, J.L. Calvo-Guirado, R.A. Delgado-Ruiz, Experimental model of bone response to xenografts of bovine origin (Endobon®): A radiological and

- histomorphometric study. *J. Clin. Oral Imp. Res.* 22 (2011) 717-734.
- [29] M. Morthaza, Hidroksiapatit dan aplikasinya di bidang kedokteran gigi. *Cakradonya Dent. J.* 7 (2015) 807-868.