ATLANTIS PRESS

Advances in Health Sciences Research, volume 37

Proceedings of the 12th Annual Scientific Meeting, Medical Faculty, Universitas Jenderal Achmad Yani, International Symposium on "Emergency Preparedness and Disaster Response during COVID 19 Pandemic" (ASMC 2021)

Cutaneous Manifestation of Coronavirus Disease 2019 (COVID-19)

Lina Damayanti[1,2,*]

[1]Department of Dermatovenereology, [2]Department of Dermatovenereology
[1]Universitas Jenderal Achmad Yani, [2]Dustira Hospital
Cimahi, Indonesia
*lina.damayanti@fk.unjani.ac.id

***Abstract*—Patients with COVID-19 most commonly present with respiratory symptoms, but multiorgan involvement can occur, including skin manifestations. Dermatologic findings may include a maculopapular eruption (morbiliform rash), urticarial, vesicular rash (varicella-like), petechiae, purpura, pseudochilblains, livedo racemosa, and distal ischemia. Most of these skin rashes are not any correlation with disease's severity and fully recovered without any treatment. But some eruptions can be a marker of poor prognosis and should be treated intensively.**

Keywords—COVID-19, cutaneous manifestations

I. INTRODUCTION

Coronavirus disease (COVID-19) is an infectious disease caused by severe acute respiratory syndrome coronavirus-2 (SARS-CoV-2). This disease was first discovered in December 2019 in China [1-4], currently COVID-19 has spread throughout the world and was declared as a pandemic by the World Health Organization (WHO) on March 11, 2020 [1,2]. In Indonesia, until now (28 February 2021) there were 1,334,634 new cases found, 36,166 people died, and 1.142,703 people recovered [5].

Symptoms in COVID-19 are usually mild and appear gradually. Some people who are infected do not show any symptoms and still feel well [1]. The most common symptoms are fever, tiredness, and a dry cough [1,2]. Some patients may experience soreness and pain, nasal congestion, headache, conjunctivitis, sore throat [1], rhinorrhea, anosmia, ageusia [1,2], and the presence of skin rashes [1,3,6,7]. In vital signs there is an increase in temperature, decreased oxygen saturation [2], the chest X-ray shows pneumonia [3], and a ground glass appearance on chest CT scan [2,3]. Results of laboratory tests in COVID-19 patients found normal leukocyte count or leukocytosis [3]. often found lymphopenia, and increased lactate dehydrogenase (LDH). Nasopharyngeal and oropharyngeal swabs followed by virus isolation will confirm the diagnosis of COVID-19 infection [2].

Cutaneous manifestations in COVID-19 were first reported by Recalcati at the Alessandro Manzoni Hospital, Italy in March 2020 [3,8]. The study was conducted on 148 positive COVID-19 patients, 60 people were excluded because there was a history of taking new drugs in the last 15 days. Of the 88 patients who were included in the inclusion criteria, there were 18 patients (20.4%) who developed cutaneous manifestation in the form of erythematous rash (14 patients), widespread urticaria (3 patients), and chickenpox-like vesicles (1 patient). Cutaneous manifestations occurred at the time of onset in 8 patients and after hospitalization in 10 patients [2,6,7,9,10].

The skin disorder in COVID-19 can occur before respiratory symptoms [11], or several days after the onset of other symptoms [8,11]. Truncal is the area of the largest lesion. The itching is minimal or no itching and clears up within a few days. The skin manifestations that arise are not related to the severity of the disease. The data analysis carried out showed that the skin manifestations that appeared were similar to the skin manifestations that occurred in viral infections in general [2] (Table 1).

A. *Pathophysiology*

SARS CoV-2 is an RNA virus that can enter cells through the angiotensin-converting enzyme 2 (ACE2) receptor which is mostly found in alveolar epithelial cells [3,4,11], small intestinal enterocytes [4,11], vascular, nerves, and heart [11]. After the virus attaches to the target cell, the virions release RNA into the cell, replicate and cause various abnormalities in the host [3]. Recent literature states that ACE2 is also present in the skin so that it can cause dermatological manifestations of COVID- 19 infection [3,11].

TABLE I. THE CLINICAL MANIFESTATIONS OF SKIN DISORDERS IN COVID-19 BASED ON MORPHOLOGICAL, STAGE OF THE DISEASES AND HISTOPATHOLOGY [3]

Classification	Clinical manifestations	
Morphological	Morbilliform or maculopapular	
	Vesicular	
	Urticarial	
	Pseudo – chilblain	
	Necrotic - acral ischaemia, haemorrhagic macules and cutaneous necrosis	
	Livedo reticularis	
	Miscellaneous maculopapular - pityriasis rosea like, erythema multiforme, erythema elevatum diutinum, enanthem, flexural rash	
Stage of disease and cutaneous manifestation		
Asymptomatic Stage		Vesicular
Symptomatic Stage	In mild to moderate severity	Pseudo – chilblain
	In severe/ critical disease	Necrotic - acral ischaemia, haemorrhagic macules and cutaneous necrosis
		Urticarial
		Livedo reticularis
Histophatological feature	Mainly lymphocytic vasculitis	Morbilliform or maculopapular
		Pseudo – chilblain
		Urticarial
		Vesicular
	Lesions because of microthrombi/hypercoagul ability	Acral ischemia
		Cutaneous necrosis
		Livedo reticularis
		Haemorrhagic macules

B. *Morbiliform or Maculopapular*

Maculopapular or morbilliform rash is a disorder that is often found in COVID-19 [3], which amounted to 36.1% [3,12] (Fig. 1 and Fig. 2). A multicenter study in Spain reported 47% cases of maculopapular eruptions [3,6]. This maculopapular rash is an erythematous macule with a papule on top or a large plaque. The rash can also be perifollicular and scaly and confluent so that it can resemble pityriasis rosea. This type of rash generally has an average duration of 9 days [6,11].

The rash can be diffuse [9], it is most common on the extremities and trunk. Other studies have shown it can occur on the face and heels bilaterally. The spread of the rash can be centrifugal, starting from the periumbilical area or trunk before spreading distally [11,13]. In some patients, there is a petechiae over the erythematous macula, this lesion can be itchy and / or painful [3,9].

Histopathological examination revealed an edematous dermis with multiple eosinophils. Lymphocyte clusters are found around blood vessels in lymphocytic vasculitis [3,9].

Fig. 1. Maculopapular lesion, a few of which present with a perifollicular distribution [6].

Fig. 2. A diffuse morbilliform, maculopapular rash [14].

C. *Urticarial*

Urticaria lesions are often found in the elderly patients and appear simultaneously with other symptoms of COVID- 19, marked by a rash in the form of acute urticaria, and generally

pruritus [3,6] (Fig. 3). Urticaria can also be found in young patients and appears before the onset of symptomps [3,15]. Urticaria can occur in various regions of the body including the trunk, extremities, and head. However, it is not found on the palms of the hands and feet [11].

The prevalence of urticaria varies from 9.7% to 19%. Urticaria lesions in COVID-19 have been associated with a severe form of the disease with a mortality of 2% [3,6]. Biopsy revealed perivascular infiltrate of lymphocytes, eosinophils, and upper dermal edema [3,16].

Fig. 3. Urticarial lesion [6].

D. Vesicular eruption

Marzano et al reported in their study the presence of vesicular eruptions similar to varicella lesions in patients with COVID-19 [17]. In different studies, 34, 7% and 9% of papulovesicular lesions were found [6,12]. These lesions are shaped blister filled with fluid, small size, with an erythematous base, with discrete or diffuse distribution of the cash found in us moderate to severe disease [17] (Fig. 4).

Casas et al's study stated that vesicles can also appear on the face and extremities [6]. The mean duration of the rash was 10.4 days, with vesicles appearing most frequently on the trunk and extremities. The vesicle rash is generally small and monomorphic so that it resembles chickenpox with a hemorrhagic content [6,17,18].

Histopathologic examination of the vesicular lesions showed dyskeratosis, ballooning multi nucleated cells, slightly necrotic keratinocytes with lymphocyte satellitosis. Spongiotic dermatitis was found with the accumulation of Langerhans cells. The dermis and blood vessel walls are edematous, there is perivascular lymphocyte infection and extravasation of red blood cell [3].

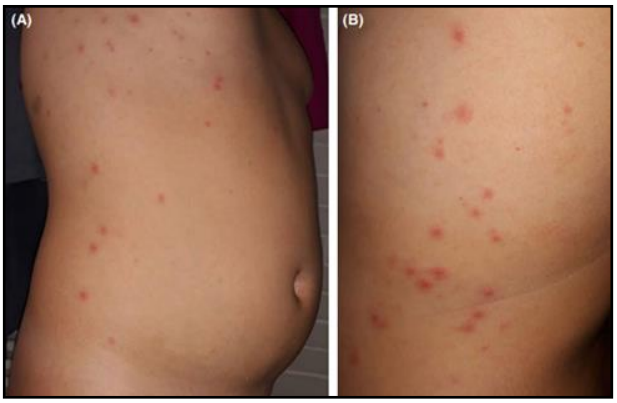

Fig. 4. A and B, Scattered erythematous papulovesicles on the trunk in a suspected COVID-19 patient [18].

E. Petechiae and Purpura

Petechiae represents a small subdermal hemorrhage, while purpura has a larger size (Fig. 5). These two rashes are found less frequently than other types of rash. All cases reported by Joob et al mentioned the presence of petechiae in patients who were misdiagnosed as dengue fever (in endemic areas) but were diagnosed as COVID-19 [11,19,20]. In these cases, the patient also had significant thrombocytopenia [11,20].

Another case reported extensive purpura which was only in the flexural area [21]. Thrombocytopenia is uncommon complication in COVID-19 so rash petechiae and purpura may not be the result of complications from COVID-19 but due to other etiologies such as vasculitis [11].

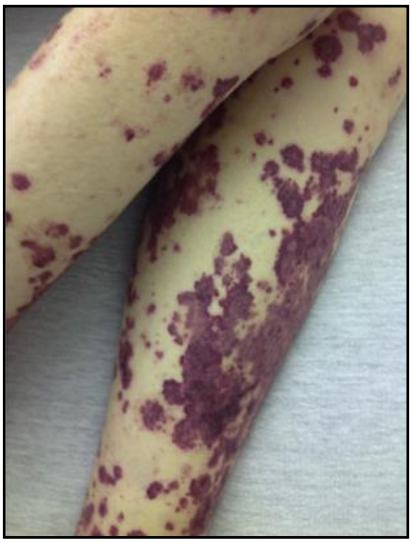

Fig. 5. Petechiae lesion [4].

F. Pseudochilblains

Chillblains are painful inflammation of small blood vessels in the skin that occur in response to repeated exposure to cold [3] (Fig. 6). Due to similar appearance, these lesions have been termed as ‘pseudochilblains’ [3,6] or ‘pernio like lesion’ or

'COVID toes' as there is no association to cold exposure with their appearance. The incidence has been reported to be 19% have been seen with less severe disease and appear late in the disease course. These are mostly seen in younger patients. The lesions are painful and itchy [6]. They appear as patches of erythematous papules and edema [21]. Vesicles and pustules with purpuric areas have also been seen [8]. These lesions fully recovered within 2 weeks without any treatment [10]. Histology of these lesions have shown either vasculitis or thrombi or both [3,6].

Fig. 6. The patients shown had confirmed COVID-19. (a & b) Acral areas of erythema–oedema with vesicles or pustules (pseudo-chilblain) [6].

G. Livedo Racemosa

Livedo racemosa is a violaceous web or net-like patterning of the skin similar to livedo reticularis; however, this is found diffusely, compared to livedo reticularis that is found in gravity-dependent areas [11] (Fig. 7). Reports have described livedo racemosa or retiform purpura (branching grouping of purpura) in 3 patients in one series [22]. One series of 21 cases found livedo reticularis of the lower extremity that the rash had a mean duration of 9,4 days [6]. Livedo racemosa was more common in older patients, with a mean age of 63 years and was also associated with more severe disease (10% mortality rate) [6,11].

In severe COVID-19 patients, it can cause hypercoagulation and Disseminated Intravascular Coagulation (DIC) with laboratory test results in the form of increased D-dimers, fibrinogen and fibrinogen degradation products, and prolonged prothrombin time. This can cause acro-ischemia with cyanosis of the fingers and toes, cutaneous bullae and dry gangrene [23]. These lesions are important because they can be secondary COVID-19 induced thrombotic vasculopathy. Livedoid lesions can occur in COVID- 19 patients with systemic thrombotic vasculopathy, it is important to be able to recognize the signs, besides these lesions have prognostic value for the patient [24].

Fig. 7. Livedo racemose.

(Obtained from: https://en.wikipedia.org/wiki/Livedo_reticularis#/media/File:Livedo_ reticularis_of_left_leg.jpg.)

H. Distal Ischemia and Necrosis

One of the most severe complications includes distal ischemia resulting in tissue necrosis. One case series described seven patients with acro-ischemia including finger and toe cyanosis, skin bullae, and dry gangrene [23] (Fig. 8). Another report of two patients described the appearance of red and purple papules on the distal fingers due to distal ischemia, which occurred before the appearance of other symptoms [7]. Other case reports describe a 13-year-old with distal toe ischemia presenting with blistering and necrosis. Given the coagulopathic impact of SARS-CoV-2, these findings necessitate discussion with vascular surgery specialists and consideration of intravenous thrombolytics [11].

Fig. 8. Progressive worsening of ischemia in both legs: plaque (A), bullae (B), and dry gangrene [23].

II. Conclusions

Skin disorders that have been reported in COVID-19 patients are not specific and can be found in other dermatological disorders, such as drug eruptions, acute urticaria, and other viral exanthema, so in cases with these clinical manifestations, more vigilance is needed when carrying out the examination. A careful history, along with other supporting examination data, can determine whether the skin condition is related to COVID-19. The manifestations of skin abnormalities that appear in COVID-19 patients are generally due to lymphocytic vasculitis and an imbalance of coagulation, which can occur before or after the diagnosis of COVID-19. The most common manifestations include maculopapular eruptions (morbilliform rash), urticaria, vesicular (varicella-

like) eruptions, petechiae, purpura, pseudo-chilblains, livedo racemose, and distal ischemia. The most common areas of predilection are the hands, feet, and trunk. Most of these skin disorders are not related to disease severity and can heal on their own, however, some eruptions can be a marker of poor prognois in COVID-19 patients, such as livedoid eruption and distal ischemia, so they should be treated intensively.

REFERENCES

[1] KMK_No._HK.01.07-Menkes-413-2020. Pedoman Pencegahan dan Pengendalian Coronavirus Diseases 2019 (Covid-19), 2020.

[2] Tim Satgas Covid-19 Perdoski. Pandemi Covid-19 dan Implikasinya terhadap Praktek Dermatologi dan Venereology di Indonesia. Pengurus Pusat Perdoski, 2020.

[3] S. Gupta, N. Gupta, and N. Gupta, "Classification and pathophysiology of cutaneous manifestations of COVID-19," Int J Res Dermatol, vol. 6, no. 4, pp. 1-5, 2020.

[4] H. Zhang J.M. Penninger, Y. Li, N. Zhong, and A.S. Slutsky, "Angiotensin-converting enzyme 2 (ACE2) as a SARS-CoV-2 receptor: molecular mechanisms and potential therapeutic target," Intensive Care Med, no. 46, pp. 586–90, 2020.

[5] Gugus Tugas Percepatan Penanganan COVID-19. Data Sebaran

[6] C.G. Casas, A. Catala, G.C. Hernandez, P.R. Jimenez, D.F. Nieto, and A.R. Villa Lario, "Classification of the cutaneous manifestations of COVID-19: a rapid prospective nationwide consensus study in Spain with 375 cases," Br J Dermatol, no. 183, pp. 71–7, 2020.

[7] A. Alramthan and W. Aldaraji, A case of COVID-19 presenting in clinical picture resembling chilblains disease. First report from the Middle East. Clin Exp Dermatol. 2020.

[8] S. Recalcati, "Cutaneous manifestations in COVID-19: a first perspective," J Eur Acad Dermatol Venereol, vol. 34, no. 5, 2020.

[9] R. Gianotti, S. Veraldi, S. Recalcati, M. Cusini, M. Ghislanzoni, and F. Boggio F, "Cutaneous clinico-pathological findings in three COVID-19-positive patients observed in the metropolitan area of Milan Italy," Acta Derm Venereol, no. 100, 2020.

[10] M. Hanif, M.J. Ali, Q. Xi, M.A. Haider, M.U. Ahme, and F.N.U. Sundas, "Cutaneous Manifestations in Patients with COVID-19: A Review," Arch Intern Med Res, vol. 3, no. 3, pp. 162-7, 2020.

[11] M. Gottlieb and B. Long, "Dermatologic manifestations and complications of COVID-19" Am J Emerg Med, no. 38, pp. 1715–21, 2020.

[12] M. Sachdeva, R. Gianotti, M. Shaha, L. Bradanini, D. Tosi, and S. Veraldi, "Cutaneous manifestations of COVID-19: Report of three cases and a review of literature," J Dermatol Sci., no. 98, pp. 75–81, 2020.

[13] A. Sanchez, P. Sohier, S. Benghanem, A.S. L'Honneur, F. Rozenberg, and N. Dupin, "Digitate Papulosquamous Eruption Associated With Severe Acute Respiratory Syndrome Coronavirus 2 Infection In December 2019 in Wuhan," JAMA Dermatol., vol. 156, no. 7, pp. 819-20, 2020.

[14] M. Hunt and C. Koziatek, "A Case of COVID-19 Pneumonia in a Young Male with Full Body Rash as a Presenting Symptom," Clin. Pract. cases Emerg. Med., vol. 4, no. 2, 2020.

[15] D. Henry, M. Ackerman, E. Sancelme, A. Finon, and E. Esteve, "Urticarial Eruption in COVID-19 Infection," J. Eur. Acad. Dermatology Venereol., 2020.

[16] D. Fernandez-Nieto, D. Ortega-Quijano, G. Segurado-Miravalles, C. Pindado-Ortega, M. Prieto-Barrios, and J. Jimenez-Cauhe, "Comment on: Cutaneous Manifestations in COVID-19: A First Perspective. Safety Concerns of Clinical Images and Skin Biopsies," J Eur Acad Dermatol Venereol, vol. 34, no. 6, pp. e252–e254, 2020.

[17] A.V. Marzano, G. Genovese, G. Fabbrocini, P. Pigatto, G. Monfrecola, B.M. Piraccini, S. Veraldi, P. Rubegni, M. Cusini, and V. Caputo, "Varicella-like Exanthem as a Specific COVID-19–Associated Skin Manifestation: Multicenter Case Series of 22 Patients," J. Am. Acad. Dermatol., vol. 83, no. 1, pp. 280–285, 2020.

[18] G. Genovese, C. Colonna, and A. V Marzano, "Varicella-like Exanthem Associated with COVID-19 in an 8-year-old Girl: A Diagnostic Clue?," Pediatr. Dermatol., vol. 37, no. 3, pp. 435–436, 2020.

[19] J. Jimenez-Cauhe, D. Ortega-Quijano, M. Prieto-Barrios, O.M. Moreno-Arrones, and D. Fernandez-Nieto, "Reply to 'COVID-19 Can Present with a Rash and Be Mistaken for Dengue': Petechial Rash in a Patient with COVID-19 Infection," J. Am. Acad. Dermatol., vol. 83, no. 2, p. e141, 2020.

[20] B. Joob and V. Wiwanitkit, "COVID-19 Can Present with a Rash and Be Mistaken for Dengue," J. Am. Acad. Dermatol., vol. 82, no. 5, p. e177, 2020.

[21] B. Ahouach, S. Harant, A. Ullmer, P. Martres, E. Bégon, L. Blum, O. Tess, and C. Bachmeyer, "Cutaneous Lesions in a Patient with COVID-19: Are They Related?," Br. J. Dermatol., 2020.

[22] C. Magro, J.J. Mulvey, D. Berlin, G. Nuovo, S. Salvatore, J. Harp, A. Baxter-Stoltzfus, and J. Laurence, "Complement Associated Microvascular Injury and Thrombosis in the Pathogenesis of Severe COVID-19 Infection: A Report of Five Cases," Transl. Res., vol. 220, pp. 1–13, 2020.

[23] Y. Zhang, W. Cao, M. Xiao, Y.J. Li, Y. Yang, J. Zhao, X. Zhou, W. Jiang, Y.Q. Zhao, and S.Y. Zhang, "Clinical and Coagulation Characteristics in 7 Patients with Critical COVID-2019 Pneumonia and Acro-Ischemia," Zhonghua xue ye xue za zhi= Zhonghua xueyexue zazhi, vol. 41, no. 4, pp. 302–307, 2020.

[24] N. Zhu, D. Zhang, W. Wang, X. Li, B. Yang, J. Song, X. Zhao, B. Huang, W. Shi, and R. Lu, "A Novel Coronavirus from Patients with Pneumonia in China, 2019," N. Engl. J. Med., 2020.