ATLANTIS PRESS
Advances in Health Sciences Research, volume 37
Proceedings of the 12th Annual Scientific Meeting, Medical Faculty, Universitas Jenderal Achmad Yani, International Symposium on "Emergency Preparedness and Disaster Response during COVID 19 Pandemic" (ASMC 2021)

Suitability of Head Examination Image with CT Scan and Electrical Capacitance Volume Tomography (ECVT) in Normal Patients

Hindun Saadah*
Department of Anatomy, Faculty of Medicine
University of Jenderal Achmad Yani
Cimahi, Indonesia
*hindun.saadah@gmail .com

Ilma Fiddianti
Department of Radiology, Faculty of Medicine
University of Jenderal Achmad Yani
Cimahi, Indonesia

Omat Rahmat H.
Department of Orthopedy
University of Sultan Agung Tirtayasa
Banten, Indonesia

***Abstract*—CT scan (Computerized Tomography) is a diagnostic tool using radiographic techniques with absorption of x-rays. The results of the picture are in the form of hypodensity or hyper density. CT scan is one of the gold standards supporting examination tools for diagnosing stroke in the presence of hypodense (stroke infarction) and the presence of hyper density (haemorrhagic stroke). ECVT (Electrical capacitance volume tomography) is a static electric field-based scanning system capable of scanning from inside the wall to the outside of the wall. ECVT can describe the electrical conditions of the brain. Early detection of the incidence of stroke is needed, especially in Puskesmas facilities as the leading health service in Indonesia. This study aims to see the suitability of the CT scan and ECVT results in normal patients. This study is a cross-sectional prospective diagnostic test with analytic data analysis to assess sensitivity and specificity. This study was conducted on 20 normal patients by performing a CT scan. and ECVT. CT scan results in 20 normal patients showed no hypodense lesions and abnormal positions. In the ECVT results, there is a difference in the distribution of brain electrical activity between normal patients. In normal patients, the value of the quantification range of the brain electrical activity index between normal patients relatively was not different.**

Keywords—CT scan, ECVT, stroke

I. INTRODUCTION

According to WHO (World Health Organization) stroke is an acute focal and global brain functional disorder accompanied by a neurological deficit that lasts more than 24 hours, this is due to interference with brain blood flow [1,2]. According to research in the last 20 years there has been an increase in the burden of stroke globally [3]. Data from WHO shows that there has been an increase in the number of stroke patients in several European countries by 1.1 million per year in 2000 to 1.5 million per year in 2025 [1,4]. According to the 2007 Riskesdas report, stroke is the highest cause of death in Indonesia compared to other diseases, namely 15.4%. The prevalence of stroke in Indonesia based on interviews was 8.3% in 2007, while according to Riskesdas in 2013 the prevalence of stroke reached 12.1% [5]. In Indonesia, based on research from the Indonesian Ministry of Health in 2007, the prevalence of non-communicable diseases (PTM), especially stroke, reached 8.3% came in fourth. Stroke sufferers who die at a young age are starting to be alarming, namely in the age range of 45-54 years, 15.9% of the causes are due to the slow handling of the patient [6]. In a previous study conducted at Dr. Moewardi obtained data on the prevalence of stroke, namely 53.3% [6]. Treatment, prevention, and prompt and appropriate treatment of stroke patients can reduce the worse impact.

The main procedure for diagnosing stroke as one of the Gold Standards is using Computerized Tomography (CT scan). Diagnosis of stroke requires supporting tools as a gold standard, namely CT (Computerized Tomography) head scan or MRI (Magnetic Resonance Imaging). CT scan is a diagnostic tool using radiographic techniques with x-ray absorption and then displayed on a black and white monitor screen. Brain examination using a head CT scan can be seen by comparing both the left and right sides of the brain and assessing the presence of hypodensity or hyper density so that a cross-sectional view of the body part is important in defining the type of stroke (ischemic or bleeding).

ECVT (Electrical capacitance volume tomography) is a dynamic volume imaging technique developed based on the electrical capacitance tomography (ECT). This tool can be used for applications in the medical field. One that is often used is

the ECTV brain. Brain ECVT is a multimodal imaging which has the advantages of non-radiative, non-invasive, fast, and inexpensive application. This tool is a static electric field-based scanner capable of scanning from inside the wall to the outside of the wall. ECVT has advantages over other similar tools. Among them the main thing is that the device is mobile (can be carried anywhere, and the patient does not have to be in a "locked" position), is able to detect the inside of the brain, not just the surface of the brain, and the results of the examination are real time (the image results are work of the brain at that time). In addition, ECVT also uses a completely new concept in making brain imaging, namely electrical capacitance.

Researchers use ECVT because ECVT can describe the electrical condition of the brain, so far this tool has not been used as a stroke diagnostic tool, so further research is needed whether this tool can be used as a simple diagnostic tool in stroke patients, both infarct stroke and bleeding stroke.

This research has never been carried out and the Cilegon Regional General Hospital is one of the class B referral hospitals that accepts around 3000-9000 stroke patients per month in 2019. Based on this background, researchers are interested in conducting a study regarding the suitability of the picture in the Electrical Capacity Volume. Tomography (ECVT) with Head CT Scan Examination in Stroke Patients at Cilegon Regional Hospital 2020/2021.

II. METHODS

This study is a cross-sectional prospective diagnostic test with data analysis performed analytically to assess sensitivity and specificity. Performed in 20 normal patients with. The patient was examined using a CT scan then an ECVT examination was performed. The data were then analysed for the suitability of the CT scan results with the ECVT results.

III. RESEARCH RESULTS

A. CT Scan Examination Results

In this study, the CT Scan examination was carried out on 20 normal patient respondents. On examination, a CT scan was found within normal limits and no hypodense lesions and abnormal positions were found.

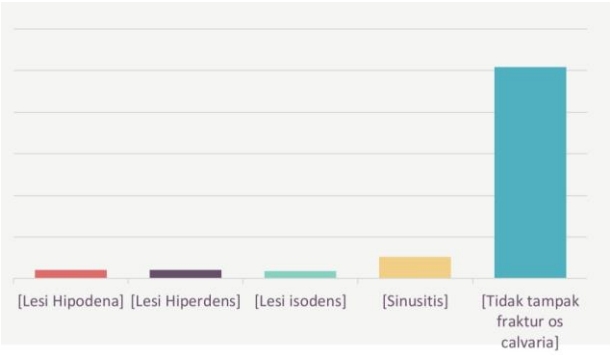

Fig. 1. Evaluation results of Head CT X examination in 20 normal patients.

Figure 1 shows the results of normal head CT scan images, out of 20 patients there is no picture of hypo / iso / hyperdense lesions on the CT photo of the head (O%), about 1 person has a picture of sinusitis (5%) with ethmoid sinusitis and 20 patients are not visible picture of calvaria os fracture (100%).

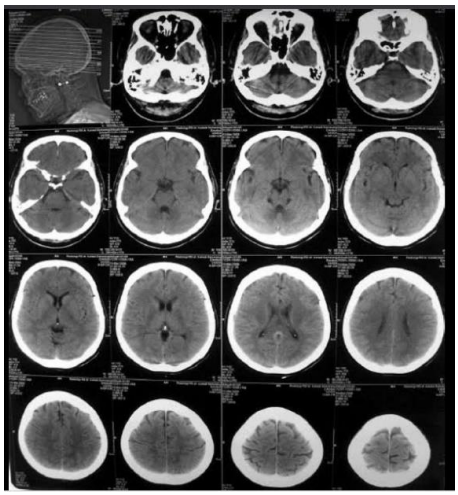

Fig. 2. CT scan result.

Based on the results of the Ct Scan examination in 20 normal patients, not all of them were within normal limits and there was no abnormal position and position of hypodense lesions.

B. ECVT Examination Results

Examination of the patient's head using ECVT produces 3D images that can be processed into 2D images. The image of the examination results of each patient is displayed with axial, sagittal, and coronal slice images. The 3D head ECVT image is analysed for permittivity values based on the range of the brain's electrical activity index to the entire volume of the full 3D view cube to determine the quantification value of the electrical activity of the brain for each patient. The value distribution of the brain electrical activity index of 3D ECVT images of the brain will be obtained as in figure 3.

From figure 3, it can be seen that there are differences in the distribution of brain electrical activity between normal patients. In normal patients, the value of the quantification range of the brain electrical activity index between normal patients was not different.

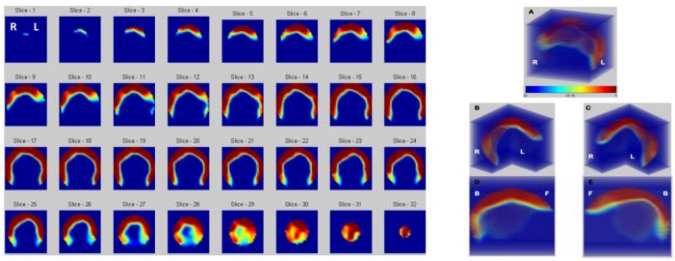

Fig. 3. ECVT image of normal patient's brain I (a) looks 3D intact, (b) front left (c) front right, (d) looks left, and (e) looks right.

Brain image of normal patient I is displayed in various views in Figure 3 respectively for full head 3D images, front left view, front right view, left view, and right-side view.

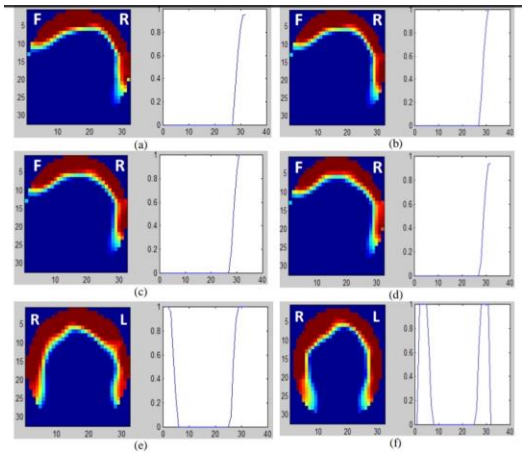

Fig. 4. Patient's Brain Activity Index Profile is normal.

In Figure 4 shows the high electrical activity of the brain which covers almost the entire cortex which is relatively homogeneous and continuous with low electrical activity of the brain which is homogeneous in the regions in it. Figure 4.4 shows the distribution of the high electrical activity index of the brain, namely ε = 0.81 - 1.0 on sagittal slices 15, 16, 17, and 18 and coronal 17 and 22 covering the entire cortex. Profile Figure 4.4 shows no activity in the centroparietal area or the inner frontal and temporal area.

IV. Discussion

In the results of CT scan readings in 20 healthy patients, no abnormalities were found on the CT scan results. In normal patients, there is no hypodense image on the Ct scan because there are no changes or abnormalities in the brain. Abnormalities in the brain are caused by disturbances in the blood vessels of the brain, so that a hypodense picture will be shown in patients during stroke.

The ECVT image of the patient's brain was analysed through a complete 3D image to determine the distribution of the electrical activity index of each patient's brain. Analysis of the front right 3D image is carried out to determine the distribution of the electrical activity index of the brain on the right front and the left side. Likewise, the 3D image appears on the front left. In addition, 3D images are also displayed in the right and left slice views to determine the distribution of the brain's electrical activity index on the right. To determine the electrical activity index of the brain on each slice, analysis was carried out on several slices of the image (sagittal and coronal) by plotting the index value of the brain's electrical activity on the x-axis. Analysis of the sagittal slices at slices 15, 16, 17, and 18 on the y = 17 axis was carried out to determine changes in the brain electrical activity index in the centroparietal (Cz) section of these sections. While the analysis on the coronal slice was carried out at slices 14 and 22. This analysis was carried out to determine the changes in the electrical activity index of the brain in the temporal region by plotting the brain electrical activity index value on the y axis = 17. index of brain electrical activity over the entire area of the slices. This calculation is carried out to determine the comparison of the distribution of the brain's electrical activity index to the area being analysed.

V. Conclusion

Examination of the patient's head using ECVT produces 3D images that can be processed into 2D images. The image of the examination results of each patient is displayed with axial, sagittal, and coronal slice images. Results of all axials, sagittal, and coronal slice images for all patients. The 3D head ECVT image is analysed for permittivity values based on the range of the brain's electrical activity index to the entire volume of the full 3D view cube to determine the quantification value of the electrical activity of the brain for each patient. The value of the distribution of brain electrical activity index in 3D ECVT images of the brain was obtained and there was no difference in the distribution of brain electrical activity between normal patients. In normal patients, the values for quantification of the range of the index of electrical brain activity were not different. This is almost the same as reading a CT scan of the head. In this study we can describe the pattern of electrical flow in the normal patient image according to the CT scan of the head that has been performed.

References

[1] World Health Organization, Stroke, Cerebrovascular Accident [Online]. Retrieved from: http://www.who.int/topics/cerebrovascular_accident/en/, 2014.

[2] American Stroke Association, About stroke [Online]. Retrieved from: http://www.strokeassociation.org., Accessed on: 2014 Jan 28.

[3] D. Mukherjee and C.G. Patil, "Epidemiology and the global burden of stroke," World neurosurgery, vol. 76, no. (6), pp. S85-S90, 2011.

[4] Health Research and Development Agency, Riskesdas 2007. Jakarta: Research and Development Agency for Health, Ministry of Health, 2008.

[5] Health Research and Development Agency, The Main Results of Indonesia's Riskesdas 2013. Jakarta: The Balitbangkes Publishing Agency, 2014.

[6] W. Hacke, M. Kaste, J. Bogousslavsky, M. Brainin, A. Chamorro and K. Lees, Ischemic Stroke Prophylaxis and Treatment-European Stroke Initiative Recommendations, 2003.