ATLANTIS PRESS
Advances in Engineering Research, volume 205
Proceedings of the 3rd Green Development International Conference (GDIC 2020)

The Effects of Human Albumin, Normal Saline and Jambi's Honey as Anti-Adhesive Agent in Laparotomized Rats

Miftahurrahmah[1], Marpaung Willy[2], Tan Reza Ade[3] Anati Purwakanthi[4], Indah Esa[5]

[1 2]*Pediatric surgery division, Jambi University.*
[3]*General surgery division, Jambi University.*
[4]*Farmacology division, Jambi University.*
[5]*Fisiology division Jambi University.*
Corresponding author Email: miftahurrahman_fkik@Unja.ac.id

ABSTRACT
Postoperative peritoneal adhesion formation after surgery is result of peritoneal surface trauma and tissue ischemia. anti-adhesive agent is one of methods to reduce tissue adhesion. Honey has a long history medicine as anti-inflammatory, anti-bacterial and wound healing agent. Thirty-six healthy male wistar rats divide into six group. Control group as group A, normal saline as group B, minimal dose of honey as Group C, maximal dose of honey as group D, minimal dose of human albumin as group E and maximal dose of Human Albumin as Group F. the identification Adhesio in macroscopic based on PAI score. The microscopic based on inflammatory cell and, fibroblast cell was assessed after 10 days. the comparison in two group based on PAI was significant in group Avs C (p value: 0.02), A Vs D (p-value: .04), AVs E (p-value: .04) and AVs F (p-value: .04), but in all groups was not significant in microscopic appearance. Jambi's honey and Human Albumin has an anti-adhesive effect in clean wound without contaminated.

***Keywords**: Adhesion, Human Albumin, Normal Saline, Honey, Laparotomy, Rats.*

1. INTRODUCTION

The inflammatory response to the peritoneum produces peritoneal adhesions. It appears after an intra-abdominal inflammatory process (inflammatory disease), exposure to intestinal contents and previous use of intrauterine contraceptives), radiation and surgical trauma [1][2]. After general surgical abdominal surgery, the incidence of intra-abdominal adhesions ranges from 67% to 93% [1]. After surgery, adhesions may have no symptoms or cause a broad spectrum of clinical problems, including intestinal obstruction, chronic pelvic or abdominal pain and female infertility. This makes the patient have to be hospitalized back to the hospital and if possible there will be additional surgery. at the same time, the procedure will complicate future surgeries. [1][3][4].

in this process, the pathogenesis of adhesion formation is divided into several processes; first, inhibition of fibrinolytic and extracellular matrix degradation systems; second, induction of an inflammatory response; and third, induction of tissue hypoxia after impaired blood delivery to mesothelial cells and sub-mesothelial fibroblasts. [5]. Surgical techniques and adjuncts are intended to prevent the development and reform of postoperative intra-abdominal adhesions. in theory, it can modify the adhesion formation mechanism [1]. albumin is a plasma protein that is useful for the healing process and supports functional and bacteriostatic tissue renovation [6].

PAI is used to assess the macroscopic appearance of adhesions and extensions in the abdomen. The index of peritoneal adhesion ranged from 0 to 30. This study aimed to determine how effective human albumin was in

preventing adhesions due to peritoneal damage on PAI scores, inflammatory cells and fibroblasts.

2. MATERIAL AND METHOD

Animals, a total of 36 healthy male wistar-rats having average weight 200 g were divided into six groups of study. These were the control group, normal saline group, minimal dose in honey, maximal dose of honey, minimal dose albumin, and maximal dose albumin. The honey was frozen in 0 degrees in 1 hour.

General anesthesia was induced with intramuscular ketamine (50 mg/kg) and xylazine (5 mg/kg). The researchers, under strict antiseptic condition, performed all surgical procedures. First operation, a midline laparotomy incision was done in dividing skin and subcutaneous tissues. Group A is as control group, group B was given irrigation with 4 ml normal saline, group C was given 0,27 mg/200 g of Honey, Group D was given 0.54 mg/200g of Honey, group E was given 0.5 g/kg BW (bodyweight) of Honey, and group F was given 1 g/kg BW of Honey. Abdominal walls were closed with PGA 4-0, and the cuts were closed with silk 4-0.

Ten days post-surgery, all rats were seen and observed. They were given Cefotaxime 50mg/Kg BW every 12 hours and paracetamol 20 mg/kg BW every 8 hours. Antibiotic and analgesic were stopped in fifth days post-operative. Rats that survive will be subjected to the second operation. After the scheduled ten days post-operative period, all the survived rats were reopened for a second-look laparotomy to detect PAI score and histopathology examination such as inflammatory cell and fibroblast cell.

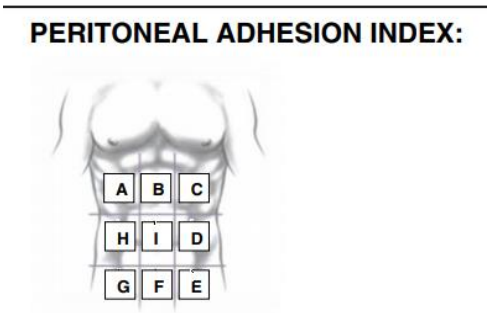

Figure 1. PAI score

Table 1 inflammatory cell and fibroblast cell

Skor	Deskripsi skor
0	no
1	1-20% in full field
2	21-50% in full field
3	51-80% in full field
4	81-100 % in full field

3. RESULT

The median of PAI score in group A is 1.5, in group B is 2.5, in group C is .0 in group D is .0, in group E is 1.0 and in Group F is 1.0. The data were analyzed using Kruskal Wallis technique with p-value= .002 that was significant (p-value < .05). The median of inflammatory cell in group A is 1.5, in group B is 1.5, in group C is 2.0, in group D is 1.5, in group E is 2.0, and in Group F is 2.0. The data was not significant with p-value= .339 (p-value> .05). The median of fibroblast cell in group A is 2.5, in group B is 3.5, in group C is 3.5, in group D is 3.0, in group E is 3.0, and in Group F is 2.0. The data was not significant with p-value= .479 (p-value> .05).

Table 2. Comparison of PAI, Inflammatory Cell and Fibroblast Cell.

	A	B	C	D	E	F	p-value
PAI	3.0	2.0	0	0	1.0	1.0	0.002*
Inflammatory cell	1.5	1.5	2.0	1.5	2.0	2.0	0.339
Fibroblast cell	2.5	3.5	3.5	3.0	3.0	2.0	0.479

Note: the data was analyzed with Kruskal Wallis*, p-value was significant (p-value<0.05)

The p-value's comparison between the group A and B in PAI (p-value=.132), inflammatory cell (p-value=.818), and fibroblast cell (p-value=.699) were not significant (p-value >0.05). The p-value's comparison between the group A and C in PAI (p-value=.02) was significant (p-value<0.05), but in inflammatory cell (p-value=.093) and fibroblast cell (p-value= 0.699) were not significant (p value >0.05). The p-value's comparison between the group A and D in PAI (p-value=.04) was significant (p-value<0.05), but in inflammatory cell (p-value=.818) and fibroblast cell (p-value= .394) were not significant (p value >0.05). The p-value's comparison between the group A and E in PAI (p-value=.04) was significant (p-value<0.05), but in inflammatory cell (p-value=.394) and fibroblast cell (p-value= .818) were not significant (p value >0.05). The p-value's comparison between the group A and F in PAI (p-value=.04) was significant (p-value<0.05), but in inflammatory cell (p-value=.18) and fibroblast cell (p-value= .485) were not significant (p value >0.05).

Table. 3. Comparison 2 group in PAI score, Inflammatory cell and fibroblast cell

Group	PAI score	Inflammatory cell	Fibroblast cell
A vs B	0.132	0.818	0.699
A Vs C	0.002*	0.093	0.699
A Vs D	0.004*	0.818	0.394

A Vs E	0.004*	0.394	0.818
A Vs F	0.004*	0.180	0.485

Note: data was analyzed with mann whytney*,
p-value value < 0.05 was significant

4. DISCUSSION

Another study showed that, honey has a beneficial effect on reducing the rate and severity of intraperitoneal adhesion reformation in our mouse model for colonic anastomosis [5]. In our study, honey has significant in reduction severity of intraperitoneal adhesion in macroscopic features. Mehmet malac et all in their study said that Mitomycin C, Hylan GF-20 and Honey usage in the laparotomized rats decrease adhesion formation, but the combinations of these agents did not show any additional effect to decrease adhesion formation [7]. The PAI score in Honey group was significant to reduce intraabdominal adhesion.

Pectin Honey Hydro gel in recent study is a novel absorbable barrier that is effective in preventing intra-abdominal adhesions in a cecal abrasion model in rats [8]. In this study honey was freeze in 0 degrees Celsius. The result of our study has good effect to reduce intraperitoneal adhesion. Interestingly, by increasing the local albumin concentration in vivo, faster bone healing is achieved, possibly because albumin recruits endogenous stem cells and promotes the growth of new bone [6]. based on PAI score in our study has significant reduction severity intraperitoneal adhesion.

Some risk factors can lead to adhesion, such as trauma surgery, tissue ischemia, infection blood, and foreign body irritating. Another study shows that Intraperitoneal irrigation with sterile water for irrigation is better than the use of normal saline in preventing peritoneal adhesion [4]. The fact in our study, normal saline is not significant to reduction severity of intraperitoneal adhesion based on macroscopic and microscopic feature.

5. CONCLUSION

Jambi's honey and Human Albumin has an anti-adhesive effect in clean wound without contaminated based on Peritoneal Adhesion Index (PAI)

REFERENCES

[1] G. Pados, C. A. Venetis, K. Almaloglou, B. C. Tarlatzi. 2010. Prevention of intra-peritoneal adhesions in gynaecological surgery: theory and evidence. Reproductive biomedicine online. 21(3):290-303.

[2] O. Irkorucu, Z. Ferahköşe, L. Memiş, Ö. Ekinci, M. Akın. 2009. Reduction of postsurgical adhesions in a rat model: a comparative study. Clinics. 64(2):143-8

[3] J. D. Alonso, A. L. Alves, M. J. Watanabe, C. A. Rodrigue, C. A. Hussni. 2014. Peritoneal response to abdominal surgery: the role of equine abdominal adhesions and current prophylactic strategies. Veterinary Medicine International. 2014;2014.

[4] O. Octaviani, A. Rahardjo, U. Alifianto, S. Anton. 2017. Differences in the Effect of Using Sterile Water for Irrigation and Normal Saline Washing to Peritoneal Adhesion Post-Laparotomy on White Rats. The Indonesian Biomedical Journal. 9(1):43-8.

[5] F. Coccolini, L. Ansaloni, R. Manfredi, L. Campanati, E. Poiasina, P. Bertoli, M. G. Capponi, M. Sartelli, S. Di Saverio, M. Cucchi, D. Lazzareschi. 2013. Peritoneal adhesion index (PAI): proposal of a score for the "ignored iceberg" of medicine and surgery. World Journal of Emergency Surgery. 1;8(1):6.

[6] C. M. Schwarz, M. Masteling, G. Vacz, I. Hornyak, Z. Lacza. 2017. Serum albumin as a local therapeutic agent in cell therapy and tissue engineering.

[7] M. Sarac, N. İflazoglu, H. Ergucuk, S. Gursul, C. Camci. 2019. The effects of mythomycin C, hylan Gf20 and honey combinations on adhesion formation in laparotomized rats. Annals of Medical Research. 26(4):565-9.

[8] G. Giusto, C. Vercelli, S. Iussich, A. Audisio, E. Morello, R. Odore, M. Gandini. 2016. A pectin-honey hydrogel prevents postoperative intraperitoneal adhesions in a rat model. BMC veterinary research. 2016 Dec 1;13(1):55.