Extranodal Natural Killer (NK)/T-cell Lymphoma Nasal type
A Case Report

Selvianti Selvianti

Abdul Wahab Sjahranie Samarinda General Hospital, Indonesia
Corresponding author. Email: selviantidr@yahoo.co.id

ABSTRACT
Extranodal Natural Killer (NK) / T-cell Lymphoma, Nasal type (ENKTCL-NT) is a rare type of Non-Hodgkin Lymphoma (NHL), commonly involves midline areas of the nasal cavity, oral cavity, and/or pharynx. ENKTCL-NT has a very strong relationship with Epstein Barr virus (EBV) infection. Treatment of ENKTCL-NT consists of chemotherapy combined with radiotherapy. This report describes a case of ENKTCL-NT in 55 years old female manifesting as unilateral swelling and mass of right nasal cavity. Treatment plans include a chemotherapy regimen with CHOP (cyclophosphamide, doxorubicin, vincristine dan prednisone) and radiotherapy.

Keywords: *Non-Hodgkin Lymphoma, ENKTCL-NT, chemotherapy, radiotherapy.*

1. INTRODUCTION

Extranodal Natural Killer (NK) / T-cell Lymphoma, Nasal type (ENKTCL-NT) is a rare type of Non-Hodgkin Lymphoma (NHL), commonly involves midline areas of the nasal cavity, oral cavity, and/or pharynx. ENKTCL-NT comprises around 4-7% of all lymphoma in Asian countries include Hongkong, Taiwan, Japan, China, and Malaysia [1,2]. The term 'lethal midline granuloma' (LMG) is being used for this disease because of a necrotic granuloma lesion with an aggressive lethal course [3]. LMG is a peripheral T-cell lymphoma with positive expression of NK cells CD 56 [4]. Other terms often used for LMG are angiocentric T cell lymphoma, malignant midline reticulosis, polymorphic reticulosis, and angiocentric immunoproliferative lesion [5]. Research in Indonesia showed differences in ENKTCL-NT incidence according to geographic area. There was a strong association with Epstein Barr virus (EBV) infection [6] NK / T cell lymphoma exclusively present in non-nodal tissues. About 80% occur in the nose, nasopharynx, oropharynx, Waldeyer ring, and upper aerodigestive tract. This whole lymphoma is considered nasal NKTCL [7]. NK/T cell lymphoma has characteristics of angioinvasive, angiodestruction, prominent necrosis, expresses cytotoxic molecule and has a strong association with EBV [8]. Clinical symptoms consist of local and systemic symptoms. ENKTCL-NT was more likely to be local than other lymphoma types [9,10]. Diagnosis confirmed with histopathology result. From histopathologic, there are some coagulative necrosis, variable cells size, neoplastic cells with azurophilic cytoplasmic granule, angiocentric, and angiodestructive, mucosal ulcer or inflammation, pseudoepithelioma hyperplasia, and erythrophagocytocis [11-13]. Treatment of ENKTCL-NT consists of chemotherapy combined with radiotherapy [14-16].

Abbreviations used	
ENKTCL-NT	Extranodal Natural Killer (NK) / T-cell Lymphoma, Nasal type
NHL	Non Hodgkin Lymphoma
EBV	Epstein Barr virus
LMG	Lethal Midline Granuloma
CHOP	cyclophosphamide, doxorubicin,vincristine prednisone
WG	Wegener granulomatosis
PR	Polymorphic reticulosis
MMR	Midline malignant reticulosis

Copyright © 2022 The Authors. Published by Atlantis Press International B.V.
This is an open access article distributed under the CC BY-NC 4.0 license -http://creativecommons.org/licenses/by-nc/4.0/.

2. CASE

A 55-year-old female was referred for evaluation of mass and swelling of her right nasal area. She complained of swelling of her right nose 6 months prior. In the beginning, only small swelling on her right nose, but the mass got bigger and caused the blockage. Since 2 months ago patient has complained of pain in her right cheek and right eye. There was an ulcer on her right nose with no response to any medication. No history of nosebleed, no complaint from visual. Sometimes she felt a headache but was relieved spontaneously. No complaint from ear and throat. She was referred from Kanudjoso General Hospital in Balikpapan.

Upon physical examination, the right nasal vestibule and nasal ala were erythematous, oedematous, and indurated. The right nasal was retracted. The lesion was tender on palpation around 0.5 cm, and there was no cervical lymphadenopathy. There was a narrowing of the right nasal cavity from anterior rhinoscopy, but the mass was submucosal so nasal mucosa was intact. No pain on palpation.

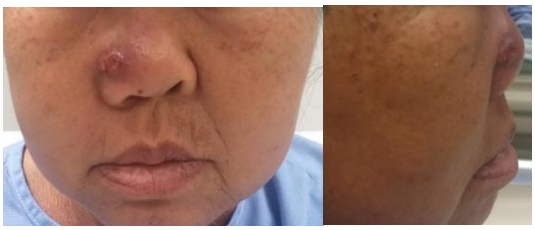

Figure 1 Clinical presentation patient with ENKTCL-NT. Erythematous, oedematous and indurated plaque involving right nose. Right nasal ala are retracted.

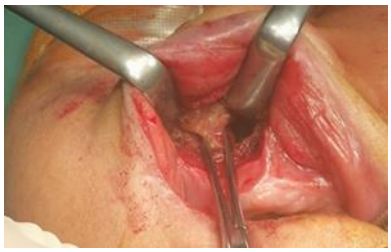

Figure 2 Open biopsy from sublabial incision approach was performed under general anesthesia.

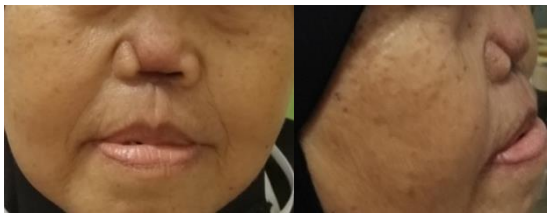

Figure 3 Patient last condition after 5 cycles of CHOP regiment.

We performed an open biopsy via a sublabial incision approach under general anaesthesia since the mass was submucosal. Mass sent for pathological evaluation. Microscopic examination revealed necrotic area with lymphocytes infiltration, plasma cells, epithelioid, atypical cells involving stromal and epithelial. The conclusion was lethal midline granuloma or extranodal NK/T cell non-Hodgkin malignant lymphoma. The patient was treated with chemotherapy cyclophosphamide, doxorubicin, vincristine, and prednisone (CHOP) regiment, planned for 5 cycles and radiotherapy. After 5 cycles of chemotherapy, the patient felt better and refused further treatment, including radiotherapy.

3. DISCUSSION

The differential diagnosis for midline destructive lesions of the face includes a myriad of neoplastic, autoimmune, infectious, and traumatic etiologists. Most commonly considered include NHL (ENKTCL-NT), leprosy, leishmaniasis, syphilis, rhinoscleroma, granulomatosis with polyangiitis, and cocaine use [17].

Lethal midline granuloma term first described and used by McBride in 1897, about progressive destruction of the face and midline nasal region. The macroscopical lesion was necrotic granuloma, and the course was lethal and aggressive. There are 3 different histological types in LMG which are Wegener granulomatosis (WG), polymorphic reticulosis (PR) or midline malignant reticulosis (MMR) and malignant lymphoma. Wegener granulomatosis shows the whole necrotic vasculitis of arteries and veins with glomerulitis. Polymorphic reticulosis shows polymorph proliferation patterns consisting of atypical large cells with mono or multinuclear, small lymphocytes, plasma cells, benign-appearing macrophages, neutrophils, and a small number of eosinophils. Categorized into malignant lymphoma because it often spreads [3]. Based on the phenotypic analysis, it was shown that LMG is a peripheral T cell lymphoma; expression of NK cell markers CD56 was also shown in some tumor cells. Furthermore, it was also shown that cell proliferation in PR has large granular lymphocytes morphology that characterized NK cells or cytotoxic T lymphocytes [3,4]. Some other terms for LMG are angiocentric T cell lymphoma, malignant midline reticulosis, polymorphic reticulosis, angiocentric immunoproliferative lesion [5].

Much of the data regarding ENKTCL-NT is derived from patient populations in Asia, Latin America, and Central America; information on US patients with ENKTCL-NT remains limited. Experts believe that this geographic variation might in part be explained by the increased prevalence of EBV in Asia and Latin and Central America [17]. Epstein-Barr virus resides in the B-cells, T-cells, NK-cells, epithelial cells, and mesenchymal cells of the infected individuals. The mechanism by which B cells are infected has been well-elucidated, but the mode of infections in other cell types is less well-known. During the infective period, EBV

transforms the host cells from a resting state to a malignant activated state and facilitates the oncogenesis of nasopharyngeal carcinoma and lymphomas, such as ENKTCL, Burkitt lymphoma, diffuse large B-cell lymphoma (DLBCL), and classic Hodgkin's lymphoma [18]. The possibility of EBV infection in this patient need further evaluation.

Nasal ENKTCL is considered as a prototype of NK/T cell lymphoma caused by EBV infection, predominantly from NK cell derivatives and less frequently from T cells. Characteristic of midfacial destruction initially known as 'lethal midline granuloma'. NK/T cell lymphoma has some character of angioinvasive, angiodestructive, prominent necrosis, expressed cytotoxic molecules, and is closely related to EBV [8].

Diagnosis of ENKTCL-NT is usually based on a combination of epidemiologic, clinical, and histopathologic features [17]. Clinical features that suggest a diagnosis of ENKTCL-NT include nasal obstruction, epistaxis and concurrent fever, malaise, and weight loss, although these are not specific for this diagnosis [9,10,17]. Along with disease development, necrosis and destruction of the nasal bone, resulting in breathing and olfactory problems. Other local symptoms are ulceration and tissue swelling. ENKTCL-NT can be aggressive because of its nature of angioinvasive angiodestructive and angiocentric [9,10]. Patient only complained of nasal obstruction and necrotic lesion. There were no systemic symptoms. Biopsy was performed under general anesthesia via a sublabial approach because the mass was submucosal to avoid the repetitive procedure. Histopathologic examination revealed necrosis area with infiltration of lymphocytes, plasma cells, histiocytes, epithelia, atypia cells, small vessels, stromal connective tissue and fat. The conclusion was lethal midline granuloma or extranodal NK/T cell non-Hodgkin lymphoma.

The differential diagnosis for ENKTCL nasal type includes Wegener granulomatosis, B cell lymphoma of the upper aerodigestive tract, T cell non-Hodgkin lymphoma, and other infections from fungal, parasitic or bacterial [1,12,13].

Since disease incidence is rare even in prevalent areas, experience is limited, and most consensus-guided treatment protocols. There has been no randomized controlled trial for ENKTL, and all data are derived from retrospective surveys and small prospective series. It carries an intrinsic referral and reporting bias, and treatment protocols may not be standardized. The prognosis has steadily improved for localized nasal disease, but it remains dismal for patients with extra nasal and disseminated lesions [11]. Localized early stages can be treated with radiotherapy, but monotherapy often results in high recurrence (up to 49%), so the combination of radiotherapy and chemotherapy is preferred. Surgical therapy is limited to biopsy, airway stabilization, and debulking surgery if needed [1,15]. ENKTL is both chemosensitive and radiosensitive [11]. Treatment plan for the patient includes a combination of chemotherapy and radiotherapy. Chemotherapy using the CHOP regiment (approved by national health insurance) was given as many as five cycles. Radiotherapy will be carried out by the oncologic radiotherapy team according to the specified schedule.

Based on the Ann Arbor classification, the patient is still in stage one, and the prognosis for stage one disease is pretty good. After five cycles of chemotherapy, the patient felt the tumour disappeared, so she refused any further treatment.

4. CONCLUSION

We report a case of ENKTCL-NT occurring in 55 years old woman with the first complaint of mass and swollen of the right nasal area six months prior. The diagnosis was confirmed by the histopathological finding of lethal midline granuloma or ENKTCL-NT. Treatment plans include chemoradiation. After five cycles of chemotherapy with the CHOP regimen, the patient felt better and refused any further treatment.

CONSENT

The patient has permitted the author to publish her images and case.

REFERENCES

[1] Liess BD. NK-Cell Lymphomas of the Head and Neck (Internet). Emedicine. 2019 (Cited August 30, 2019). Availabe from: https://emedicine.medscape.com/article/871609

[2] Peh SC, Path FRC, Quen QWD. Nasal and Nasal-type Natural Killer (NK)/Y-cell Lymphoma: Immunophenotype and Epstein-Barr Virus (EBV) Association. Med J Malaysia Vol 58 No 2: 196-204. June 2003 (Cited August 30, 2019). Available from: http://www.e-mjm.org/2003/v58n2/T-Cell_Lymphoma.pdf

[3] Aozasa K, Takakuwa T, Hongyo T, Yang WI. Nasal NK/T-cell lymphoma: epidemiology and pathogenesis. Int J Hematol 87:110–117. 2008 (Cited August 30, 2019). Availabe from: https://www.researchgate.net/publication/5594994

[4] Sakata K, Hareyama M, Ohuchi A et al. Treatment of Lethal Midline Granuloma Type Nasal T-Cell Lymphoma. Acta Oncologica, 36:3, 307-311. 1997(Cited August 30, 2019). Available from: https://doi.org/10.3109/02841869709001268

[5] Luca DC. Extranodal NK / T cell lymphoma, nasal type (Internet). PathologyOutlines.com. (Cited

August 30, 2019). Available from: http://www.pathologyoutlines.com/topic/lymphomanonBnasal.html

[6] Hardjolukito E, Kurniawan AN, Kodairiah R, Ham MF, Luo WJ, Nakatsuka S, et al. Sinonasal lymphomas in Indonesia: Immunophenotype and Epstein–Barr virus association. Med J Indonesia, 13:71–6. 2004(Cited August 30, 2019). Available from: https://doi.org/10.13181/mji.v13i2.133

[7] Tse E, Kwong YL. The diagnosis and management of NK/T-cell lymphomas. Journal of Hematology & Oncology, 10:85. 2017 (Cited August 31, 2019). Available from: https://www.researchgate.net/publication/316112861_The_diagnosis_and_management_of_NKT-cell_lymphomas

[8] Dojcinov SD, Fend F, Quintanilla-Martinez L. EBV-Positive Lymphoproliferations of B- T- and NK-Cell Derivation in Non-Immunocompromised Hosts. IPathogens, 7: 28. 2018 (Cited August 31, 2019). Available from: www.mdpi.com/journal/pathogens

[9] Suzuki R, Takeuchi K, Ohshima K, Nakamura S. Extranodal NK/T-cell lymphoma: diagnosis and treatment cues. Hematol. Oncol. 26:66-72. 2008 (Cited August 31, 2019). Available from: https://onlinelibrary.wiley.com/doi/pdf/10.1002/hon.847

[10] Gopalan S, Gendeh BS. A case of nasal NK/T-cell lymphoma. Brunei Int Med J. 9 (4): 270-273. 2013 (Cited August 31, 2019). Available from: http://bimjonline.com/PDF/Bimj%202013%20Volume%209,%20Issue%204/BIMJ201394270.pdf

[11] Au WY. Current Management of Nasal NK/T-cell Lymphoma. Cancer Network, Vol 24 (4). April 2010 (Cited August 31, 2019). Available from: https://www.cancernetwork.com/leukemia-lymphoma/current-management-nasal-nkt-cell-lymphoma

[12] Jeffrey ML, Miranda RN. Extranodal NK-/T-Cell Lymphoma, Nasal Type. In: Diagnostic Pathology : Lymph Nodes and Extranodal Lymphomas. 2nd Ed. Canada: Elsevier, 2017: 644-651

[13] Montone KT. Differential Diagnosis of Necrotizing Sinonasal Lesions. Arch Pathol Lab Med. 139:1508–1514. 2015 (Cited August 31, 2019). Available from: https://www.archivesofpathology.org/doi/full/10.5858/arpa.2015-0165-RA

[14] Harabuchi Y, Takahara M, Kishibe K, Nagato T, Kumai T. Extranodal Natural Killer/T-Cell Lymphoma, Nasal Type: Basic Science and Clinical Progress. Front. Pediatr. 7:141. 2019 (Cited August 31, 2019). Available from: https://www.researchgate.net/publication/332444678_Extranodal_Natural_KillerT-Cell_Lymphoma_Nasal_Type_Basic_Science_and_Clinical_Progress

[15] Tse E, Kwong YL. How I treat NK/T-cell lymphomas. Blood, Vol 121(25): 4995-2005. 2013 (Cited August 31, 2019). Available from: http://www.bloodjournal.org/content/121/25/4997?sso-checked=true

[16] Kim SJ, Yoon SE, Kim WS. Treatment of localized extranodal NK/T cell lymphoma, nasal type: a systematic review. Journal of Hematology & Oncology, 11:140. 2018 (Cited August 31, 2019). Available from: https://doi.org/10.1186/s13045-018-0687-0

[17] Schuler A, Smith E, Lowe L, Helfrich Y. Extranodal natural killer/T-cell lymphoma, nasal type: A rare but critical diagnosis. JAAD Case Reports. 3:225-227.2017 (Cited February 20, 2020). Available from: http://dx.doi.org/10.1016/j.jdcr.2017.02.017

[18] Cai Q, Cai J, Fang Y and Young KH. Epstein-Barr Virus-Positive Natural Killer/T-Cell Lymphoma. Front. Oncol. 9:386. 2019. (Cited August 30, 2019). Available from: https://www.frontiersin.org/articles/10.3389/fonc.2019.00386/full