Quality of Life in a Patient with Total Laryngectomy Without Neck Dissection for Stage III Laryngeal Carcinoma

A Case Report with EORTC QLQ-C30

Tengku Reza Alfisyah[1,2*], Benny Kurnia[1,2], Lily Setiani[1,2], and Marhaban Marhaban[1,2]

[1] [1]*Otorhinolaryngology Head and Neck Surgery Department, Faculty of Medicine, Syiah Kuala University*
[2]*dr. Zainoel Abidin Hospital, Aceh, Indonesia*
[*]*Corresponding author. Email: tengkurezaa@gmail.com*

ABSTRACT
Laryngeal cancer is a malignancy on larynx that may occur in glottis, supraglottic and subglottic. This malignancy is a second most carcinoma in head and neck area Clinical manifestation such as dysphonia, breathing obstruction, dysphagia, odynophagia, and hemoptysis. Reported a laryngeal cancer with total laryngectomy without neck dissection combined with radiotherapy which has promising result with a good quality of life. a 62-year-old male with supraglottic carcinoma stage III T3N1M0 complaining severe shortness of breath accompanied by voice abnormality like hoarseness and dysphagia. History of tobacco smoking for 42 years, about 10-12 tobacco sticks per day. Follow up observation for the first year show a good quality of life according to EORTC QLQ-C30 version 3. On the second year, the quality of life is getting better and there were an improvement in physical activity, independent self-care, and no sign of recurrency. Total laryngectomy without neck dissection followed by radiotherapy give promising result with good quality of life within 30 months of observation according to EORTC QLQ-C30 version 3.

Keywords: *Laryngeal Carcinoma, EORTC QLQ- C30 Version 3, Laryngectomy, Radiotherapy, Neck Dissection.*

1. INTRODUCTION

Laryngeal cancer is one of the most common cancers in head and neck. The incidence of laryngeal cancer in the world reaches 177,422, with a death rate of 94,771 [1]. Previous study report 19 patient in 2 years in West Nusa Tenggara, Indonesia [2].

Smoking habits are most commonly associated with the incidence of laryngeal cancer [2]. One of the other bad habits associated with the incidence of laryngeal cancer is alcohol consumption. When the alcohol metabolized by the body, it will produce reactive oxygen species (ROS). Excessive ROS production will cause oxidative stress and can affect to the gene mutations [3]. Laryngoesophageal reflux is also suspected as a trigger factor for laryngeal cancer. Repeated exposure of gastric reflux to the laryngeal mucosa will cause chronic inflammation and may induces the changes of the laryngeal mucosa [4].

Dietary habits can influence the type of food consumption. The animal food origin and animal fats are associated with the incidence of laryngeal cancer. This may also be accompanied by low consumption of vitamins and fiber [5].

Dyspnea, hoarseness and difficulty of swallowing are symptoms that are often expressed. Another symptom is a lump in the neck. The management of laryngeal cancer depends on the stage of the cancer. It may consist of surgery, radiation, and chemotherapy. There are several types of surgery in cases of laryngeal cancer such as hemilaryngectomy, supraglottic laryngectomy, supracricoid laryngectomy, near total laryngectomy, total laryngectomy [6].

Copyright © 2022 The Authors. Published by Atlantis Press International B.V.
This is an open access article distributed under the CC BY-NC 4.0 license -http://creativecommons.org/licenses/by-nc/4.0/.

The curability of early-stage head and neck cancer (stages I and II) is 60% to 95%. The specific cure rate depends on the size and location of the tumor and the appropriate treatment. Almost all of early-stage tumors are technically resectable. Surgical resection and radiotherapy (RT) are the best treatment options. For some subtypes, surgery may have a higher benefit than radiotherapy. There are several factors should be considered on deciding radiotherapy prior to surgery for stage I and II head and neck cancer. It depending on the tumor site, long-term potential, treatment-related morbidity, expertise of the attending physician, patient preferences, comorbidities, and history of previous radiation or other necessary requirements anticipated for future radiation [7,8].

The five-year survival rate for laryngeal cancer was around 68%. This rate was influenced by the stage of the cancer. If there was a metastasis, the life expectancy will drop to 20% [9]. After surgery, several sequelae my arise and could reduce the patient's quality of life, including sensory complaints, dry mouth, and thicker saliva [7].

In Quality-of-Life analysis, the European Organisation for Research and Treatment of Cancer (EORTC) has developed the generic self-administered questionnaire. The EORTC Quality of Life Questionnaire-Core 30 (QLQ-C30) version 3 (V3) which this group developed has become the most widely used questionnaire in Europe for cancer patients, and is extensively used around the world [10]. This questionnaire is designed to measure cancer patients regarding physical, psychological and social functions whether they are on chemotherapy or operation procedure [11].

2. CASE REPORT

Male patient, 62 years old, came to emergency department with stridor and feeling hard to breath. Patient initially complained that eating and drinking began to be difficult for more than a year. At the first presentation, he felt uncomfortable when swallowing and getting worse. Sometimes this complain accompanied by coughing, especially at night and even make the patient awake. In addition, the patient also complained of hoarseness especially for the last one month. According to the patient, the hoarseness had never improved and conversely getting worse. No history of treatment prior to this medical visit.

In general examination, found a left neck node within level 2 in dimension 1x1x1 cm. On the CT scan larynx with contrast, found a mass in supraglottic, glottic and subglottic (Figure 1). Patient then undergone biopsy and the result was keratinizing squamous cell carcinoma.

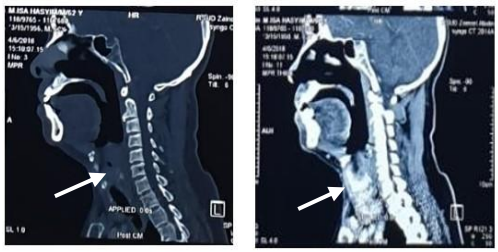

Figure 1. Imaging on laryngeal mass (white arrow)

Patient was diagnosed with laryngeal carcinoma stage III (T3N1M0). The stage was determined through the TNM classification according to the American Joint Committee on Cancer (AJCC) 8th edition 2018. Stage III includes T1, T2, T3 with N1 and M0. The primary tumor in this patient was a tumor confined to the larynx with vocal cord fixation and/or invasion to the following areas: post-cricoid area, pre-epiglottic space, para-glottic space and/or inner cortex of the thyroid cartilage (T3). According to laryngectomy specimen, found that the supraglottic mass was extended to the para-glottic space.

Table 1. Result of EORTC QLQ-C30 for physical activity

Question	Patient answer			
	Not at ALL	A Little	Quite a Bit	Very Much
Do you have any trouble doing strenuous activities, like carrying a heavy shopping bag or a suitcase	1	**2***	3	4
Do you have any trouble taking a long walk?	1	**2***	3	4
Do you have any trouble taking a short walk outside of the house?	**1***	2	3	4
Do you have need to stay in bed or a chair during the day?	**1***	2	3	4
Do you need help with eating, dressing, washing yourself or using the toilet?	**1***	2	3	4

Meanwhile (N1) is defined as metastases in one ipsilateral lymph node with a size of 3 cm or smaller and negative extra nodular extension (ENE). The nodules found in this patient were on the ipsilateral side

or only on the left side with a size 1x1x1 cm. For distant metastases, no distant metastases found (M0).

Table 2. Result of EORTC QLQ-C30 for social activity

Question	Patient answer			
	Not at ALL	A Little	Quite a Bit	Very Much
Were you limited in doing either your work or other daily activities?	1	2*	3	4
Were you limited in pursuing your hobbies or other leisure time activities?	1	2*	3	4
Were you short of breath?	1*	2	3	4
Have you had pain?	1*	2	3	4
Did you need to rest?	1*	2	3	4
Have you had trouble sleeping?	1	2*	3	4
Have you felt weak?	1	2*	3	4
Have you lacked appetite?	1	2*	3	4
Have you felt nauseated?	1*	2	3	4
Have you vomited?	1*	2	3	4
Have you been constipated?	1	2*	3	4
Have you had diarrhea?	1*	2	3	4
Were you tired?	1*	2	3	4
Did pain interfere with your daily activities?	1	2*	3	4
Have you had difficulty in concentrating on things, like reading a newspaper or watching television?	1*	2	3	4
Did you feel tense?	1*	2	3	4
Did you worry?	1	2	3*	4
Did you feel irritable?	1	2*	3	4
Did you feel depressed?	1	2*	3	4
Have you had difficulty remembering things?	1*	2	3	4
Has your physical condition or medical treatment interfered with your family life?	1	2	3*	4
Has your physical condition or medical treatment interfered with your social activities?	1	2	3*	4
Has your physical condition or medical treatment caused you financial difficulties?	1	2	3*	4

This patient is performed a total laryngectomy without neck dissection and continued to undergone radiotherapy. Follow-up in this case is carried out 4 times in the first year and 2 times in 2nd year. The patient's condition was getting better and the patient's quality of life was good. The results of the QLQ C30 - V3 in this patient was very good. According to EORTC QLQ30-V3, there is almost no handicap on physical activity (Table 1). For the social activity, found almost no handicaps (Table 2). Overall, found a very good health condition and quality of life on this patient (Table 3).

Table 3. Overall health and quality of life

How would you rate overall health during the past week?						
1	2	3	4	5	6*	7
← Very Poor - Excellent→						
How would you rate overall quality of life during the past week?						
1	2	3	4	5	6*	7
← Very Poor - Excellent→						

3. DISCUSSION

Management of this patient was total laryngectomy without neck dissection. The reason to decide this method was because of the primary tumor is T3 located in supraglottic area that extended to the paraglottic space. Neck dissection remain as controversy on management of laryngeal cancer. Xio et al (2019) found

no significant different between laryngectomy with and without neck dissection [12]. Furthermore, authors were not done it due to the size of node was very small (about 1 cm) and there was no cervical metastasis. In addition, this patient was highly recommended for radiotherapy.

Finally, with the T3 for primary tumor and N1, a total laryngectomy was performed followed by radiotherapy. If the radiotherapy cannot be done, then the other options were laryngectomy and ipsilateral/central thyroidectomy or bilateral neck dissection.

Based on the previous study, there are several surgical procedures for laryngeal cancer such as hemilaryngectomy, supraglottic laryngectomy, supracricoid laryngectomy, near total laryngectomy and total laryngectomy were accompanied by neck dissection [13]. For T3 laryngeal cancer, laryngectomy and chemoradiation was meet a better overcome compare to radiation alone [14]. Other study among 451 patients with malignant laryngeal tumors from 1985-2002 found a 5-year survival rate at stage I 85%, stage II 77 %, stage III 51% and stage IV 35% [15].

In the present case, the patient survives until 26 months with good quality of life which is measured by EORTC QLQ- C30 version 3. Patient have no any complaints in physical activities except limitations in communication. This result is similar with the study in Iran [9]. The used of this questionnaire on the other cancer, reported an excellent result for assessing quality of life on patients undergoing chemotherapy or other surgery procedures [16]. However, a more comprehensive study should be done to understand better regarding the application of this method on assessing quality of life in patients with laryngeal cancer in Indonesia.

4. CONCLUSIONS

Total laryngectomy is a first line treatment for laryngeal cancer stage III and stage IV and continued with radiotherapy. The quality of life in this patient is good according to EORTC QLQ- C30 version 3.

ETHIC CONSIDERATION

Authors declared that the patient was consented about publishing his case on the scientific journal.

REFERENCES

[1] E Bray F, Ferlay J, Soerjomataram I, Siegel RL, Torre LA, Jemal A. Global cancer statistics 2018: Globocan Estimates Of Incidence And Mortality Worldwide For 36 Cancers In 185 Countries. CA Cancer J Clin. 2018;68(6):394–424.

[2] H. Kadriyan, M. A. Sulaksana, I. G. A. T. Aryani, D. Yudhanto, E. A. Yuliyani, IOP Conf. Ser.: Earth Environ. Sci., 2021, 712 012021

[3] F. Islami, I. Tramacere, M. Rota, V. Bagnardi, V. Fedirko, L. Scotti, Alcohol Drinking And Laryngeal Cancer: Overall And Dose-Risk Relation - A Systematic Review and Meta-Analysis. Oral Oncol [Internet]. 2010; 46(11):80210. Available from:http://dx.doi.org/10.1016/j.oraloncology.2010.07.015.

[4] K. Tae, B. J. Jin, Y. B. Ji, J. H. Jeong, S. H. Cho, The Role of Laryngopharyngeal Reflux as a Risk Factor in Laryngeal Cancer : A Preliminary Report. J Clin Exp Otorhinolaryngol. 2011;4(2):101–4

[5] V. Edefonti, F. Bravi, W. Garavello, C. La Vecchia, M. Parpinel, S. Franceschi, Nutrient-Based Dietary Patterns And Laryngeal Cancer: Evidence From An Exploratory Factor Analysis. Cancer Epidemiol Biomarkers Prev. 2010;19(1):18–27

[6] E. Rudolph, G. Dyckhoff, H. Becher, A. Dietz, H. Ramroth, Effects Of Tumour Stage, Comorbidity And Therapy On Survival Of Laryngeal Cancer Patients: A Systematic Review And A Meta-Analysis. J Eur Arch Otorhinolaryngol. 2011; 268:165–79.

[7] K. J. Lee, Cancer of the Larynx. In: Essential Otolaryngology Head and Neck Surgery. 8 th. Connecticut: McGraw-Hill Companies, Incorporated; 2008

[8] B. Hermani, H. Abdurrachman, Tumor Laring. Dalam: Soepardi EA, Iskandar N, Bashiruddin J, Restuti RD, ed. Buku Ajar Ilmu Kesehatan Telinga Hidung Tenggorok Kepala & Leher. Edisi ke-7. Jakarta: FKUI; 2015, hal 171-5

[9] Y. Liu, Z. Su, G. Li, C. Yu, S. Ren, D. Huang, Increased Expression Of Metadherin Protein Predicts Worse Disease-Free And Overall Survival In Laryngeal Squamous Cell Carcinoma. Int J Cancer. 2013;133(3):671–9.

[10] K. Iravani, P. Jafari, A. Akhlaghi, B. Khademi, Assessing whether EORTC QLQ-30 and FACT-G measure the same constructs of quality of life in patients with total laryngectomy. Health and Quality of Life Outcomes. 2018;16. doi:http://dx.doi.org/10.1186/s12955-018-1012-x

[11] C. F. Snyder, A. L. Blackford, T. Okuyama, Using the EORTC-QLQ-C30 in clinical practice for patient management: identifying scores requiring a clinician's attention. Qual Life Res.

2013;22(10):2685-2691. doi:10.1007/s11136-013-0387-8.

[12] C. C. Xiao, S. A. Imam, S. A. Nguyen, Neck dissection does not add to morbidity or mortality of laryngectomy. World J Otorhinolaryngol - Head and Neck Surgery 2019;5(4): 215-221.

[13] C. Bressler, Post-operative care of the Laryngectomy Patient. Perspectives. 2000; 2(1): 4-7.

[14] D. J. Lin, M. Goodfellow, J. Ong, M. Y. Chin,L. Lazarova, L, and H. C. Cocks, Treatment outcomes of laryngectomy compared to non-surgical management of laryngeal carcinomas: A 10-year multicentre audit of 179 patients in the northeast of england. The Journal of Laryngology and Otology, 2020; 134 (12), 1103-1107. doi:http://dx.doi.org/10.1017/S0022215120002704

[15] C. G. Gourin, B. T. Conger, W. C. Sheils, P.A. Bilodeau, T. A. Coleman, E. S. Porubsky, The effect of treatment on survival in patients with advanced laryngeal carcinoma. Laryngoscope. 2009 Jul;119(7):1312-7. doi: 10.1002/lary.20477.

[16] European Organisation for Research and Treatment for cancer http://www.eortc.org/app/uploads/sites/2/2018/08/specimen-qlq-c30-english.pdf