Acquired Long QT Syndrome (LQTS) Secondary to Electrolyte Imbalance: A Case Report

Yusra Pintaningrum[1,2,*] and Ketut Angga Aditya Putra Pramana[1]

[1]*Faculty of Medicine, University of Mataram, Indonesia*
[2]*Cardiology and Vascular Department of West Nusa Tenggara General Hospital, Indonesia*
[*]*Corresponding author. Email: yusra@unram.ac.id*

ABSTRACT
The long QT syndrome (LQTS) is a one type of severe cardiac arrhythmia syndrome that leading cause to unexpected cardiac death, characterized with impaired ventricular repolarization caused by hereditary disorder in sodium and potassium channels on cardiac myocyte and acquired caused by drugs or electrolyte imbalance, especially hypokalemia, hypomagnesemia, and hypocalcemia. This condition result in abnormality on the electrocardiogram (ECG) examination as QT interval prolongation and may increase risk of syncope, ventricular arrhythmias, seizure, and cardiac death to the patient. We present a case of a 46-year-old woman came to emergency department at hospital with a chief complaint of dizziness. Three days before these complaints, the patient also complaints of epigastric pain and profuse vomitting more than five times. The patient has no history of taking certain any medications before. On physical examination, there is no abnormality in patient's vital signs and only palpable pain on epigastric region. On clinical laboratory examinations showed electrolyte imbalance such as hyponatremia and hypokalemia. From electrocardiography showed prolongation of QTc interval (638 ms) and venticular extrasystole trigeminy. On echocardiography, the patient had diastolic dysfunction grade I and concentric left ventricular hypertrophy with normal ejection fraction. From that examination, the patient diagnoses with acquired long QT syndrome and the focus of therapy in this patient is to restore the electrolyte balance. The diagnostic for LQTS in this patient is based on QTc interval $\geqslant$ 500 ms in electrocardiography examination. This diagnose criteria was based on Heart Rhythm Society guidelines. Electrolyte imbalance, especially hypokalemia, hypomagnesemia, and hypocalcemia is one of the most common indirect mechanisms of QT interval prolongation. The point of management LQTS in this patient includes recognition and discontinuation of any encouraging medication and the forcefull correction of any electrolyte imbalance, such as hypokalemia, hypomagnesemia, and hypocalcemia. Early detection in QTc interval may be helpful to diagnose and treatment LQTS to prevent further complications such as syncope, ventricular arrhythmias, and sudden cardiac death.

Keywords: *Long QT Syndrome, Arrythmia, Electrolyte Imbalance.*

1. INTRODUCTION

The long QT syndrome (LQTS) is serious cardiac arrhythmia disorder that driving reason of unexpected cardiac death, characterized with impaired ventricular repolarization manifest as prolongation of the QT interval on the electrocardiogram (ECG) [1,2]. This condition caused by hereditary disorder in sodium and potassium channels on cardiac myocyte and acquired caused by drugs or electrolyte imbalance, especially hypokalemia, hypomagnesemia, and hypocalcemia result in abnormality on the ECG examination as QT interval prolongation and may increase risk of syncope, ventricular arrhythmias, seizure, and cardiac death to the patient [1,3,4]. Long QT syndrome incidences is approximately about 1 in 10.000 to 15.000 peoples and female is more prevalent [5]. Although there are many patients asymptomatic, the first clinical signs of this disease might be sudden cardiac death [1,2]. The following is a case report of 46-year-old women who came to the cardiology clinic with chief complaint of dizziness and diagnose with acquired LQTS secondary to electrolyte imbalance.

2. CASE REPORT

A 46-year-old woman came to emergency department hospital with a chief complaint of dizziness since yesterday. The complaints last throughout the day and the complaints improve within a few minutes when the patient lies down. Three days before these complaints, the patient also complaints of epigastric pain and profuse vomitting more than five times in one day when the patient drink or eat. She denied any complaints of palpitation and syncope. The patient has no history of cardiac disease, neurological disease and taking certain any medications before. On physical examination, the blood pressure was 120/80 mmHg, heart rate 78 times per minute, and her respiratory rate was 16 times per minute. Patient also complaint tenderness on epigastric region. On clinical laboratory examinations showed sodium 129 mmol/L and potassium 2,3 mmol/L. From the first electrocardiography examination showed prolongation of QTc interval (638 ms using Bazett) and venticular extrasystole trigeminy (Figure 1).

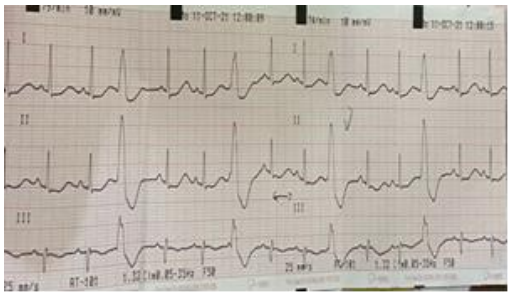

Figure 1. ECG examination showed prolongation of QTc interval and venticular extrasystole trigeminy

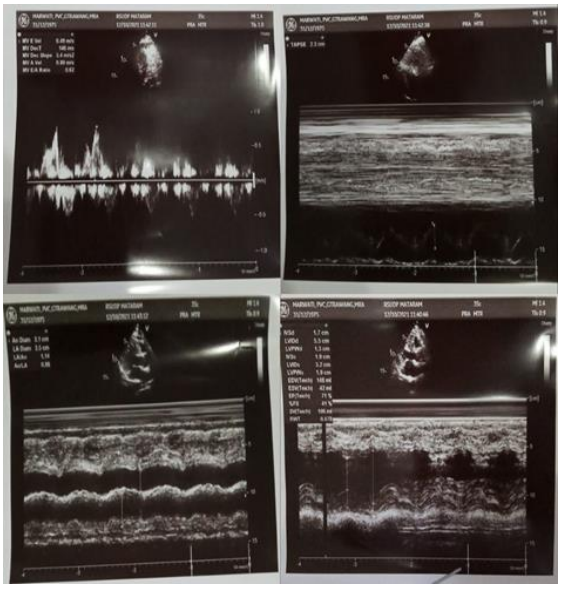

Figure 2. Echocardiography examination showed normal heart chamber, diastolic dysfunction grade I, and concentric left ventricular hypertrophy.

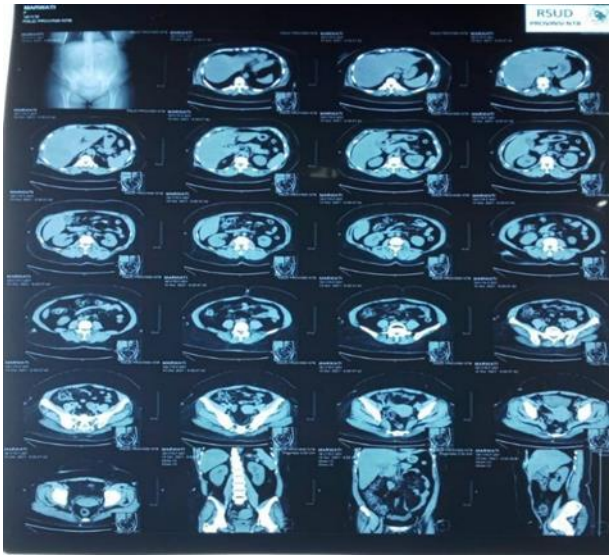

Figure 3. Abdominal computed tomography scan on patient showed cystic mass on her right lobe of the liver

On echocardiography examination showed normal heart chamber, the patient had diastolic dysfunction grade I and concentric left ventricular hypertrophy with 71% ejection fraction (Figure 2). Due to the patient's complaints of nausea, vomiting and tenderness in the epigastrium, an abdominal computed tomography scan was performed on the patient and the results were a cystic mass in the right lobe of the liver (Figure 3). From that examination, the patient diagnoses with acquired long QT syndrome secondary to electrolyte imbalance.

The The patient was given intravenous omeprazole and ondansetron to reduce complaints of vomiting and epigastric pain, her electrolytes imbalance (hyponatremia and hypokalemia) were treated with intravenous NaCl 3% 7 drips per minute, KCl 25 mEq on 500 cc normal saline three times in 8 hours, oral spironolacton tablet 100 mg twice daily, oral KCl tablet 600 mg three times daily, and high potassium diet to maintain sodium level greater than 135 mmol/L and potassium level greater than 4 mmol/L. On the second day of treatment, the patient underwent another ECG examination and still showed the presence of prolongation of QTc interval (554 ms) and venticular extrasystole trigeminy (Figure 4). On the third day of treatment, the patient underwent ECG examination and laboratory examination showed slightly improvement of prolongation of QTc interval (479 ms), prominent U wave in all leads, and there is no venticular extrasystole trigeminy (Figure 5). From laboratory examination showed slightly increase of potassium serum level to 2.5 mmol/L.

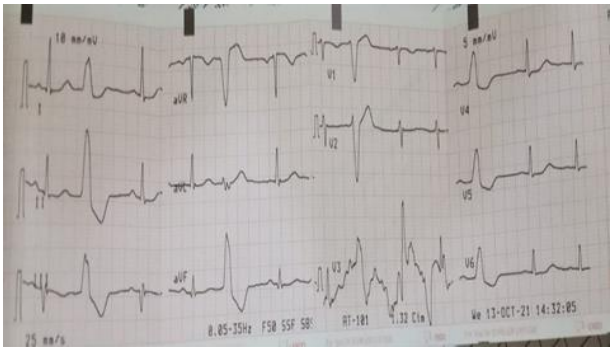

Figure 4. Second ECG examination showed prolongation of QTc interval (522 ms) and venticular extrasystole trigeminy.

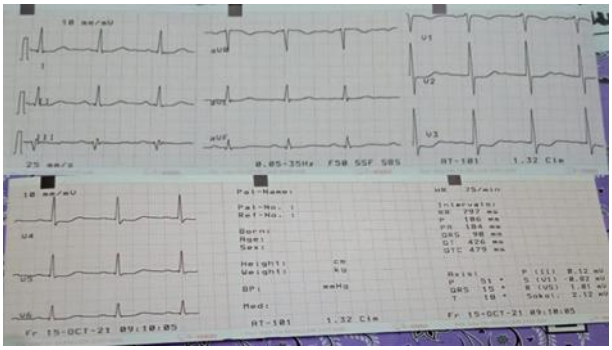

Figure 5. Third ECG examination showed prolongation of QTc interval (479 ms) and U-wave in all leads.

3. DISCUSSION

The long QT syndrome (LQTS) is a type of cardiac arrhythmia syndrome characterized with impaired ventricular repolarization manifest as prolongation of QT interval on the ECG [1,2]. This predisposes to the development risk of syncope, ventricular arrhythmias, seizure, and cardiac death to the patient [1,3,4]. LQTS can caused by two conditions, such as inherited disorder in which there are genes changes or mutations of cardiac ion channels on cardiac myocyte and acquired in which malfunction of the cardiac ion channels is caused by medication or electrolyte imbalance, especially hypokalemia, hypomagnesemia, and hypocalcemia [1,3,4,6]. In the present illustrative case, prolongation of the QT interval was caused by the electrolyte imbalance. There are several reasons that make LQTS is an important disease, because LQTS often be a life-threatening disorder, and patients with clinical signs without treatment have a high mortality rate arround 21% in a year after the first symptoms [1].

The QT interval on ECG describe the duration of ventricular depolarization and repolarization and measured on the ECG examination from the beginning of the QRS complex to the end of T wave [7,8]. QT interval is impacted by the variety of heart rate (bradycardia and tachycardia). The RR interval must be estimated for rate correction. Some formulae have been proposed for measurement of corrected QT interval (QTc) and the gold standard formulae is Bazett's formula. Measurement of QTc interval with Bazett's formula is described in Figure 6 [6,9]. The normal QT interval is range from 300 to 440 ms and if QTc interval >440 ms is considered prolong QT interval [9].

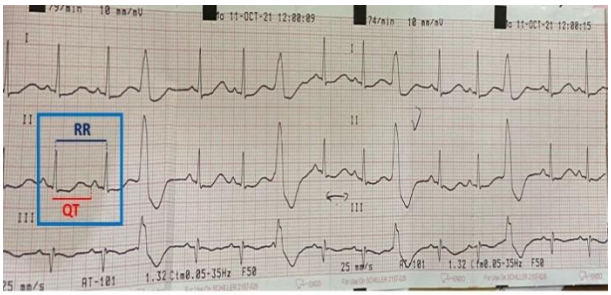

$$QTc = \frac{QT}{\sqrt{RR}}$$

Figure 6. Bazett's formula for measurement the QTc interval.

Impaired ventricular repolarisation is described through QT prolongation or abnormal morphology of T-wave on ECG examination [5]. The prolongation of QTc interval is best seen in lead II, V5 or V6 but all 12 leads should be examined and avoid for appearance U wave in QTc interval measurement [5,10]. In general, LQTS can be diagnosed by any of the following (1) when the duration of QTc interval ⩾ 500 ms in asymptomatic patient on repeated 12-lead ECG examination, but in patients with syncope LQTS can be diagnosed when the duration of QTc interval ⩾ 480 ms on repeated 12-lead ECG examination (based on Heart Rhythm Society guidelines); (2) risk score ⩾3.5 (based on Schwartz scoring system); or (3) when there is evidence of pathogenic variant genes of LQTS [10,11,12]. In this case, we diagnose this patient with acquired LQTS because of the duration of QTc interval in this patient 638 ms based on Heart Rhythm Society guidelines. We cannot use the Schwartz scoring system for diagnosis LQTS in this patient because the QTc interval prolongation in this patient caused by electrolyte imbalance and not inherited or congenital disease [10].

Acquired long QT syndrome is a abnormality of ventricular repolarization most frequently caused by medications or electrolyte imbalance, especially hypokalemia, hypomagnesemia, and hypocalcemia that may precipitate ventricular arrythmia and cause sudden cardiac death [9]. Although several medications can contribute to prolongation the QT interval, one of the most widely recognize mechanisms of QT interval prolongation is electrolyte imbalance. Hypokalemia in this patient cause changes of myocyte conductivity lead to decrease of amplitude of T-wave, inversion of T-wave, U-waves prominent, and QT interval

prolongation, which predisposes to ventricular arrhythmia. Low extracellular potassium in hypokalemia paradoxically reduces fast potassium channels by increased inactivation or competitive block by sodium. Subsequently, hypokalemia creates a delay of action potential in phase 3 rapid repolarization and prolongs the QT interval [3,9].

The point of the treatment of acquired LQTS includes the recognition and stop of any medication that precipitate the prolongation of QT interval and treat of any electrolyte imbalance, such as hypokalemia or hypomagnesemia [9]. Correction of extracellular potassium levels to the normal range and keep up with the potassium levels > 4 mmol/L can decrease QT interval and related morphological anomalies [3,9]. Potassium sparing diuretics (spironolactone) is likewise known safe and succesful to treat patient with hypokalemia. Potassium levels can increase with using spironolactone could be cause of either impaired transcellular potassium shift or diminished potassium losses. Mineralocorticoid receptors in the colon epithelial cells plays a significant role in potassium elimination. Spironolactone can inhibit these mineralocorticoid receptors and prevent the colonic potassium losses and causing increment of serum potassium levels [13]. After the patient underwent potassium correction, the patient underwent a second ECG examination and found a shortened QTc interval compared to the first ECG examination (from 638 ms to 554 ms).

4. CONCLUSION

LQTS is a type of cardiac arrhythmia syndrome characterized with delayed ventricular repolarization manifest as QT interval prolongation that can caused by two conditions, such as hereditary disorder and acquired. The point of the treatment of acquired LQTS includes the recognition and stop of any medication that precipitate the prolongation of QT interval and treat of any electrolyte imbalance. Early detection in QTc interval may be helpful to diagnose and treatment LQTS to prevent further complications such as syncope, ventricular arrhythmias, and sudden cardiac death.

ETHICAL APPROVAL

The study is in compliance with the Declaration of Helinski.

CONSENT

The author has affirmed during submission that patient consent has been signed and collected in accordance with the journal's patient policy.

REFERENCES

[1]. Schwartz, P. J., Crotti, L., & Insolia, R. (2012). Long-QT syndrome. *Circulation: Arrhythmia and Electrophysiology*, 5(4), 868–877. https://doi.org/10.1161/circep.111.962019.

[2]. Sethi, P., Treece, J., Pai, V., & Onweni, C. (2017). Long QT syndrome unveiled by a fatal combination of medications and electrolyte abnormalities. *Cureus*. https://doi.org/10.7759/cureus.1581

[3]. Digby, G. C., Pérez Riera, A. R., Barbosa Barros, R., Simpson, C. S., Redfearn, D. P., Methot, M., Femenía, F., & Baranchuk, A. (2011). Acquired long QT interval: A case series of multifactorial Qt prolongation. *Clinical Cardiology*, 34(9), 577–582. https://doi.org/10.1002/clc.20945.

[4]. Wilde, A. A., Amin, A. S., & Postema, P. G. (2021). Diagnosis, management and therapeutic strategies for congenital long QT syndrome. *Heart*. https://doi.org/10.1136/heartjnl-2020-318259.

[5]. Bednar, M. M., Harrigan, E. P., Anziano, R. J., Camm, A. J., & Ruskin, J. N. (2001). *The QT interval. Progress in Cardiovascular Diseases*, 43(5B), 1–45. https://doi.org/10.1053/pcad.2001.21469.

[6]. Hunter, J. D., Sharma, P., & Rathi, S. (2008). Long QT syndrome. *Continuing Education in Anaesthesia Critical Care & Pain*, 8(2), 67–70. https://doi.org/10.1093/bjaceaccp/mkn003.

[7]. Lankipalli, R. S., Zhu, T., Guo, D., & Yan, G.-X. (2005). Mechanisms underlying arrhythmogenesis in long QT syndrome. *Journal of Electrocardiology*, 38(4), 69–73. https://doi.org/10.1016/j.jelectrocard.2005.06.008.

[8]. Goldenberg, I., & Moss, A. J. (2008). Long QT syndrome. *Journal of the American College of Cardiology*, 51(24), 2291–2300. https://doi.org/10.1016/j.jacc.2008.02.068.

[9]. Kallergis, E. M., Goudis, C. A., Simantirakis, E. N., Kochiadakis, G. E., & Vardas, P. E. (2012). Mechanisms, risk factors, and management of acquired Long QT Syndrome: A comprehensive review. *The Scientific World Journal*, 2012, 1–8. https://doi.org/10.1100/2012/212178.

[10]. Waddell-Smith, K. E., & Skinner, J. R. (2016). Update on the diagnosis and management of Familial Long QT syndrome. *Heart, Lung and Circulation*, 25(8), 769–776. https://doi.org/10.1016/j.hlc.2016.01.020.

[11]. Magnusson, P., & Gustafsson, P.-E. (2017). A case of Long QT syndrome: Challenges on a bumpy road. *Clinical Case Reports*, 5(6), 954–960. https://doi.org/10.1002/ccr3.985

[12]. Jancauskaite, D., Smigelskaite, A., Mikstiene, V., Barysiene, J., Tunold, A., Marinskis, G., & Aidietis, A. (2018). Genetic disease modifying future career: A case report of long qt syndrome. *Journal of Clinical Case Reports*, 08(02). https://doi.org/10.4172/2165-7920.10001081

[13]. Langote, A., Hiremath, S., Ruzicka, M., & McCormick, B. B. (2017). Spironolactone is effective in treating hypokalemia among peritoneal dialysis patients. *PLOS ONE*, 12(11). https://doi.org/10.1371/journal.pone.0187269