Management of Stage II Sinonasal Carcinoma (T2N0M0) with Transnasal Endoscopic Resection and Radiotherapy

Riska Handriani[1,2*], Fadhlia Fadhlia[1,2], and Benny Kurnia[1,2]

[1] *Otorhinolaryngology Head and Neck Surgery Department, Faculty of Medicine, University of Syiah Kuala*
[2]*dr. Zainoel Abidin Hospital, Banda Aceh, Indonesia*
[*]*Corresponding author. Email: riskaa_im@yahoo.com*

ABSTRACT
Nasoethmoidal carcinoma is a malignant tumor found in the nasal cavity and ethmoidal sinuses. The early stage is rarely found due to the similarity of symptoms inflammatory process in sinonasal. The main modality for sinonasal cancer is surgery followed by radiation as adjuvant treatment. The prognosis for early-stage sinonasal malignancy is generally good, which found a low recurrence rate. This study aims to report the management of early-stage sinonasal carcinoma. A 44-years-old male with the main symptom of left nasal blockage and bleeding since 6 months ago, physical examination showed a solitary mass at the posterior nasal septum. Histopathology result was well-differentiated squamous cell carcinoma and Paranasal sinuses CT-Scan showed a solid mass in left posterior nasal cavity extended to ethmoidal sinuses. He underwent transnasal endoscopic resection, and we suggested continuing with radiotherapy at central java. Follow-up 2 months after radiotherapy, we performed a biopsy, and histopathology revealed a chronic inflammatory process without malignancy, paranasal sinuses CT Scan n physical examination within normal limits. Transnasal endoscopic resection followed by radiotherapy is an appropriate and effective treatment for sinonasal carcinoma in the early stage. A case of limited-stage II sinonasal carcinoma with transnasal endoscopic resection surgery followed by radiotherapy has been reported with good result and need to be followed until the next five years.

Keywords: *Sinonasal carcinoma, transnasal endoscopic resection, squamous cell carcinoma.*

1. INTRODUCTION

Sinonasal carcinoma is the second most common malignancy found in the head and neck after nasopharyngeal carcinoma. Only around 10% of all malignancies in the head and neck are found in the United States, with an incidence of only 0.5-1 per 100,000 people. The most common malignant tumor is Squamous Cell Carcinoma (SCC) [1]. The most frequent location of SCC is in the maxillary sinus (60%), followed by the nasal cavity (20%) and the ethmoid (10-15%). In the sphenoid sinus (1-2%) and frontal sinus (0.3%), SCC is rarely found [2].

Based on the American Joint Committee on Cancer (AJCC), sinonasal carcinoma is divided into tumors that grow in the nasal cavity and ethmoid sinus (nasoethmoidal complex) or tumors that grow in the maxillary sinus. The clinical-stage and advanced prognosis of sinonasal carcinoma is related to the site of beginning growth. Tumors of the maxillary sinus are usually found at a higher stage and have a worse prognosis than tumors in the nasal cavity [1,3].

Sinonasal cancer is more common in people who work in the hardwood furniture sector, nickel refining, leatherwork, and mustard gas production [4]. Risk of sinonasal SCC has been associated with wood dust exposure. Formaldehyde, radium, mustard gas, and asbestos have all been linked to occupational exposures. Smoking does increase the risk by 2-3 fold. Active HPV is strongly implicated. Recent studies have found transcriptionally active HPV in 40.9% of sinonasal SCC [5].

Nasal stuffiness, blood-stained nasal discharge, facial paraesthesias, or pain are clinical symptoms of nasal cavity cancer and paranasal sinuses. These signs

and symptoms may be misdiagnosed as sinusitis. The direction of dispersion will determine late traits [4,6].

Diagnosis of sinonasal carcinoma is based on history, physical examination, radiological examination, histopathology (biopsy). Radical tumor resection followed by either adjuvant radiotherapy or observation represents the mainstay of therapy. Endoscopic approaches are increasingly used in the treatment of nasal cavity SCC besides traditional open approaches, such as lateral rhinectomy or degloving facial approaches [4,6].

Management of sinonasal SCC cases based on the 2020 National Comprehensive Cancer Network Guidelines, malignancies identified at an early stage can be treated with surgical resection followed by observation or adjuvant radiation. In comparison to open surgery, endoscopic surgery is becoming more popular in treating sinonasal SCC in the early stage [6,7].

Figueroa et al. 2020 said that the local control and survival rate obtained in patients treated for malignant tumors of the nasal cavity and paranasal sinuses by endonasal endoscopic surgery was 73.33% [2].

2. CASE REPORT

A man, 44 years old, came to the ENT clinic at Zainoel Abidin hospital with complaints of Nasal congestion that has been felt since six months ago_and has worsened since 2 weeks, accompanied by intermittent bleeding from the left nose. Complaints of nasal congestion initially felt intermittent, but since 2 weeks, the patient began to feel persistent. Lymphadenopathy, swallowing pain, tinnitus, aural fullness, and trismus have not complained. The histopathology results found well-differentiated squamous cell carcinoma with acute inflammation. Then it was done by transnasal endoscopic resection, and we suggested continuing with radiotherapy in Central Java. The patient had a history of smoking since adolescence for over 20 years, around 1 pack per day, and has only recently quit after 5 months.

The patient's general status was conscious with normal vital signs. From physical examinations, it appears that the left nasal cavity is narrowed, the media turbinate are covered with a solitary dense, hyperemic, non-tender and bleeding easily, accompanied by mucopurulent secretions. The right cavity is normal limits, the inferior turbinate is eutrophic, there are mucopurulent secretions. Posterior rhinoscopy revealed postnasal. The lymph nodes in the neck are not enlarged.

Figure 1. Clinical appearance of patient

On July 22, 2020, a biopsy was performed on the left nasal cavity. The histopathological result found well-differentiated Squamous Cell Carcinoma. The patient was performed paranasal sinuses Computer Tomography, chest X-rays, complete blood test, and clinical chemistry. On the paranasal sinuses computed tomography examination, a mass in the left posterior nasal cavity was found in the left posterior nasal cavity that extended to the choana, left ethmoid sinus, obliterated the left medial inferior turbinate caused a choanal obstruction (Figure 2).

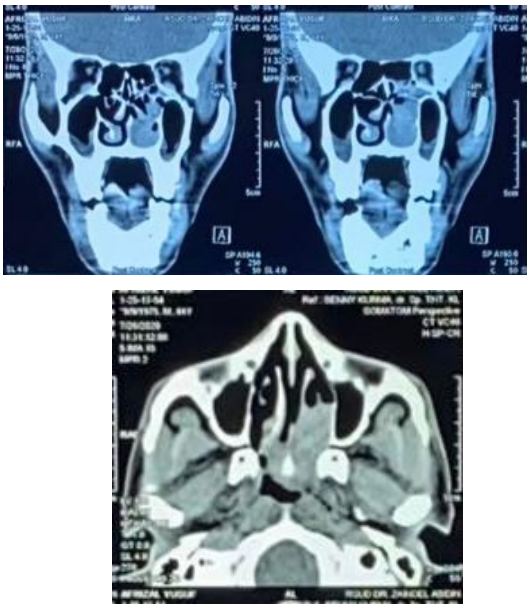

Figure 2. Paranasal Sinuses CT Scan showing mass in the left posterior nasal cavity and left ethmoid sinus.

Chest X-rays and complete blood laboratory were found within normal limits. The patient was diagnosed with stage 2 left sinonasal carcinoma. (T2N0M0). After that, the patient was planned with transnasal endoscopic resection and radiotherapy. Informed consent and counseling were performed before surgery. The patient was consulted to the Cardiology department to tolerate surgery with mild tolerance, consult to the Anesthesia department was planned under general anesthesia with ASA I. On August 22, 2020, a transnasal endoscopic resection was performed on a mass in the posterior part

of the nose near the left septum with IV prophylactic antibiotics. Cefazoline 1 gr in 100 cc of NaCl 0,9 % was used in 20 minutes and fasting for 6 hours before surgery.

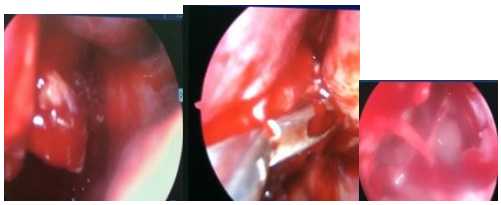

Figure 3. transnasal endoscopic resection

The patient was under general anesthesia. The procedure begins by assessing the nasal cavity using 0 telescopes to identify the mass. The mass was seen in the posterior part of the nose near the left nasal septum and resected with a margin of 5 mm from the tumor margin to ensure a safe margin. Anterior ethmoidectomy was performed using an ostium seeker. After that, the ethmoid bulla was opened and cleaned. A mass was seen in the left ethmoid area and removed with a j curette and Blakesley forceps.

After surgery, The resected tumor tissue was sent to the Anatomical Pathology laboratory. The postoperative diagnosis was posted endoscopic transnasal resection of the indication for stage 2 left sinonasal carcinoma. On the first day following surgery, the patient complained of mild pain (VAS 2) in the surgical site, and his vital signs were normal. Physical examination showed no blood seepage on the bandages of nasal packing covering the surgical wound.

On the 2nd day after surgery, the pain in the surgical wound was no longer felt, the nasal packing was removed, and the patient was sent home with Cefixime 2x100 mg and 2x50 mg sodium diclofenac, and control to the ENT-KL clinic on the 7th postoperative day.

On the seventh day following surgery, there were no complaints. Vital signs are within normal limits. There were no signs of complication or inflammation. The results of postoperative histological examination (August 22, 2020) showed *non-keratinizing squamous cell carcinoma*.

Figure 4. Follow up, 7 days after surgery.

The patient is planning to receive adjuvant radiotherapy right away. The patient will be referred to RSPAD Hospital in Central Java because RSUDZA does not have radiotherapy facilities.

The patient underwent radiotherapy 33 times fraction with a dose of 66 Gy in RSPAD Hospital, Central Java.
After 2 months of radiotherapy, the patient returned to the ENT clinic. After a physical examination, it turned out that the patient had post-radiotherapy synechiae, and we did release synechiae, together with a biopsy at three points. The histopathological results showed an inflammatory process without malignancy, physical examination, and paranasal sinuses ct scan within normal limits.

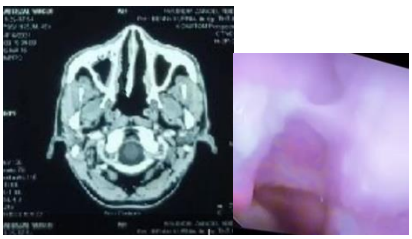

Figure 5. Follow up 2 months after radiotherapy.

3. METHODS

The literature search was conducted on June 21, 2021, with the keywords "Sinonasal carcinoma, transnasal endoscopic resection, squamous cell carcinoma" Results of research on ScienceDirect, PubMed, Jscisociety, to search for the evidence.

The literature search was performed using the following inclusion criteria: 1) Transnasal endoscopic resection for sinonasal carcinoma: concept, treatment outcomes, indications, surgical margin, adjuvant therapy, complication, and oncologic outcomes. 2) patient with T1-2 disease, nasal cavity or ethmoid tumors, and some T3 disease without bony destruction.

The management of sinonasal carcinoma may have promising results with surgery followed by radiotherapy. Endoscopic resection is feasible for sinonasal squamous cell carcinoma and has a similar oncologic outcome as a traditional open approach for early-stage sinonasal tumors. This literature is excluded from the analysis.

4. RESULT

Treatment for sinonasal squamous cell carcinoma varies depending on the tumor type and the stage, patient performance status, and comorbidities. However, surgical resection with postoperative radiotherapy appears to be the optimal approach. Transnasal endoscopic resection and radiotherapy are appropriate and effective treatments for sinonasal carcinoma in early stage [7].

Nakamaru et al. [8] mentioned that safe indications for EES for patients with sinonasal squamous cell carcinoma were a relatively limited disease, such as T1-

2 disease, nasal cavity/ethmoid tumors, and some T3 disease. Endoscopic resection is feasible for sinonasal squamous cell carcinoma without bony destruction of the sinus walls and has a similar oncologic outcome as a traditional open approach. Regarding surgical margins for EES and open approaches, it's important to remember that the best results come from careful patient selection and free margin surgery. As previously stated, margin-negative surgery is required for a successful outcome. As a result, EES indications are based on the expectation that the tumor can be resected with a negative surgical margin using EES [8].

Figueroa et al. [2] said the local control rate and survival obtained in patients treated for malignant tumors of the nasal cavity and paranasal sinuses by endonasal surgery with endoscopes alone or combined with an external approach was 73.33%. Tumors with greater extension and infiltration, higher T staging, location in the paranasal sinuses, and unfavorable histologies such as undifferentiated carcinoma had a higher need for neoadjuvant or adjuvant treatment and a worse prognosis than those not very extensive, T1-2 and localized neoplasms in the nasal cavity [2].

5. DISCUSSION

Reported a case of a 44 years old man diagnosed with stage two sinonasal squamous cell carcinoma. Diagnosis is made based on the patient's history, physical examination, radiological and histopathological examinations. Tumors are two times more common in men than women [5]. Symptoms usually appear when the sinus or nasal cavity is blocked or when the tumor has penetrated the sinus wall and invaded nearby tissue, causing pain or bleeding. The secretions are frequently bloody. Based on the literature, nasal congestion and bleeding from the nose are the most common symptoms in patients in the early stages [1,9]. In patients, the left nasal cavity is narrowed, the media turbinate is covered with a solitary dense, hyperemic, non-tender, and bleeding easily, accompanied by mucopurulent secretions.

Sinonasal carcinoma is thought to be caused by several factors, including exposure to industrial fumes, smoking, exposure to various agents, the Human Papilloma Virus (HPV), and smoking thought to be associated with an increased incidence of sinonasal cancer [10]. In this case, the patient had a history of smoking since adolescence for over 20 years, around 1 pack of cigarettes per day. the patient has been an active smoker for a long time.

Early symptoms of the nasal cavity and paranasal sinus cancers, such as nasal obstruction, nasal discharge, epistaxis, and facial pain, are similar to those of inflammatory conditions; as a result, patients and clinicians may overlook these complaints about a long time, resulting in a significant delay in diagnosis. A sinonasal expansive lesion must be suspected when symptoms are unilateral, persistent, and not respond to medical treatment [11]. Nasal cavity tumors were diagnosed early and had a little extension, possibly due to the early appearance of signs and symptoms such as nasal obstruction and epistaxis that made the patients consult quickly, in contrast to paranasal sinus neoplasms, which were diagnosed at a more advanced stage and involved several subsites [2]. This early symptom is in accordance with the complaints experienced by the patient are nasal obstruction and epistaxis.

Ohngren's classification, an imaginary plane is drawn, extending between the medial canthus of the eye and the angle of the mandible. Superstructural growths have a worse prognosis than those located below it (infrastructural). In lesions that arise in infrastructure, symptoms generally appear earlier to be detected more quickly so that tumor resection has satisfactory results. In the superstructure, symptoms often appear at an advanced stage, making resection difficult because it extends to the inferior fossa, pterygomaxillary, orbital, and cranial bases. In these patients, tumor growth is infrastructural. Symptoms appear earlier and are detected sooner, allowing for successful tumor resection [1,12].

Imaging investigation should include computed tomography (CT), which is complementary to biopsy. Computed tomography scans give Advantages: Evaluating tumor involvement to the paranasal sinuses, the boney skull base, and the retroorbital and orbital apex region [9,13]. On the patient's Paranasal sinuses CT-Scan, there was a sinonasal mass in the left nasal cavity and the left ethmoid sinus.

Before surgery, nasal tumors had been biopsied with histopathology results found well-differentiated Squamous Cell Carcinoma, and this is in accordance with the theory that the most common histopathology is Squamous Cell Carcinoma, which is around 68-82% of cases [14].

Treatment for sinonasal SCC varies somewhat depending on the stage, the location of the tumor, proximity to important structures, and somewhat based on the tumor type. However, surgical resection with clear margins is the treatment of choice for most sinonasal tract carcinomas. Surgical resection with postoperative radiotherapy appears to be the optimal approach. Treatment for sinonasal SCC refers to the NCCN guidelines 2020 [7,15]. This patient is a stage two patient whose choice of treatment is resection of the tumor mass followed by radiotherapy.

Surgical treatment has evolved, and appropriate cancer resections can be performed in selected patients using endonasal approaches with endoscopes. A

transnasal endoscopic resection is an option. Sinonasal squamous cell carcinoma were relatively limited diseases, such as T1-2 disease, nasal cavity/ethmoid tumors, and some T3 diseases without bony destruction of the sinus walls [8].

According to the International Consensus Statement on Endoscopic Skull-Base Surgery published in 2019, expert opinion has suggested that the following criteria would indicate that a patient is not an appropriate candidate for endoscopic resection of SN-SCC if the following structures are involved: hard palate, anterior maxillary, inferior maxillary, extensive posterior maxillary, orbital floor, ascending process of the maxilla, nasal bone, anterior table of the frontal sinus, or posterior table of the frontal sinus osseous extension, soft palate extension, extensive pterygopalatine fossa/infratemporal fossa extension, cranial nerve extension to or beyond the respective skull-base foramen, cavernous sinus extension, orbital extension, brain parenchymal extension, or involvement of the soft tissues of the face. This consensus states that so far, oncologic outcomes are similar between endoscopic and open approaches in selected patients with sinonasal squamous cell carcinoma. In addition, there is now adequate published evidence of benefit for endoscopic resection of sinonasal squamous cell carcinoma. However, this procedure should be an option only for properly selected patients and experienced surgeons [8].

Based on the 2020 NCCN Guidelines, repeat surgery, radiotherapy, or a combination of both can be selected in cases of recurrence that occur after surgery [8]. Definitive or adjuvant radiotherapy provides an effective treatment for sinonasal malignancies. The histopathological type of squamous cell carcinoma with early-stage theoretically has sufficient sensitivity good response to radiotherapy [14,16]. Sinonasal tumor response to radiation varies depending on the tumor type. Radiation can be used as a single modality or as a follow-up therapy after surgery when tumor margins are suspected. The prognosis for early-stage sinonasal malignancy is generally good, which found a low recurrence rate. The 5-year survival rate for patients who received radiation after surgery was 79% compared with 49% for patients treated with radiotherapy alone [11].

6. CONCLUSION

A limited-stage II sinonasal SCC case with transnasal endoscopic resection surgery followed by radiotherapy showed a good result and needs to be followed until the next five years.

REFERENCES

[1] Shah J, Patel S, Singh B,Wong R. Nasal cavity and paranasal sinuses in: Jatin Shah's Head and Neck Surgery and Oncology 5th Edition. Elsevier; 2019. p. 115-55

[2] Figueroa E, Serrano C, Ruggeri CS. Endoscopic Surgery in malignant rhinosinusal tumors.J Otolaryngol Rhinol; 2020.

[3] Amin, M.B, Edge SB ,Greene, et al. American Joint Committee on Cancer, Cancer Staging Form Supplement, Eighth edition, 2018.

[4] Dhingra PL. Neoplasms of the paranasal sinuses. In Disease of Ear, Nose, and Troat Head and neck surgery, six edition , Elsevier, 2014.P:205-209.

[5] Al-qurayshi Z, Smith R, Walsh JE. Sinonasal Squamous Cell Carcinoma Presentation and Outcome : A National Perspective. 2020.

[6] Janik S, Gramberger M, Kadletz L, Pammer J, Grasl MC, Erovic BM. Impact of anatomic origin of primary squamous cell carcinomas of the nasal cavity and ethmoidal sinus on clinical outcome. Eur Arch Otorhinolaryngol. 2018 .275(9):2363-2371.

[7] Bruce JY, Darlow S. Head and Neck Cancer. NCCN Clin Pract Guidel Oncol (NCCN Guidel). 2020

[8] Homma A, Nakamaru Y, Lund VJ, et al. Endonasal endoscopic surgery for sinonasal squamous cell carcinoma from an oncological perspective. Auris Nasus Larunx Elsevier.2020. 41-49

[9] Chan Y Vonne, Goddar JC, Tumor of the paranasl sinuses in: K.J.Lee's Essential Otolaryngology Head and Neck Surgery, 11th edition, Mc Graw Hill. 2016 P. 510-520.

[10] Zimmer Lee A, Carrau Ricardo I. Neoplasms of the Nose and paranasal sinuses. In: Bailey JB, ed. Head and Neck Surgery Otolaryngology. Fourth ed. Lippincott Williams & Wilkins. Philadelpia. 2014. P.2044-2096

[11] Bossi Paolo, Farina Davide, Gatta Gemma, Lombardi Davide, Nicolai Piero, Orlandi Ester. Paranasal sinus cancer in Critical Reviews in Oncology/Hematology, Elsevier, 2015.

[12] Dagan Roy, Bryant Curtis. Sinonasal cancer: Practical Guides in radiation Oncology, Springer International Publishing Switzerland, 2017.P: 141-151.

[13] Lund VJ, Clarke PM , Swift AC, Mc Garry GW, Kerawala C, Caenell D. Nose and paranasal sinus tumours: United Kingdom National Multidisciplinary Guidelines. The Journal of Laryngology & Otology. 2016;(130) P:111–118.

[14] Badwal, Jaspreet Singh. Cancer of the nasal septum. World Journal of Pharmaceutical and Medical Research. 2018.

[15] S James, Jr Lewis, Sinonasal Squamous Cell Carcinoma: A Review with Emphasis on Emerging Histologic Subtypes and the Role of Human Papillomavirus.Head and neck pathol. Cross Mark. 2016.

[16] Duru Birgi, S., Teo, M., Dyker, K.E. et al. Definitive and adjuvant radiotherapy for sinonasal squamous cell carcinomas: a single institutional experience. Radiat Oncol. 2015.