Bilateral Non-Invasive Follicular Thyroid Neoplasm with Papillary-Like Nuclear Features (NIFTP) Presenting in a Female Child

Ade Burhanudin

RSUD Pantura MA Sentot Patrol Indramayu, Indonesia
Corresponding author. Email: burhanudin.ade@gmail.com

ABSTRACT
Non-invasive follicular thyroid neoplasm with papillary-like features (NIFTP) is a benign thyroid lesion without recurrence or distant metastasis. The management of NIFTP can be partial or total thyroidectomy, which is sufficient to provide a perfect cure rate. Most cases of NIFTP were found in adults and few cases were found in children. In this case report, we present a case of NIFTP in a 13-year-old child. This case report also adds a new case of NIFTP in the pediatric age group with bilateral nodule characteristics without nodule invasion and no recurrence until the last examination, recommending less aggressive management.

Keywords: *NIFTP, Children, bilateral.*

1. INTRODUCTION

In the last 30 years the diagnosis of thyroid cancer has increased quite dramatically. Although the survival rate about 97.8% thyroid cancer has a very significant impact. In the United States alone for the treatment of thyroid cancer during the period 1985-2014 spent about 1.6 billion dollars. For this reason, an attempt was made to make an appropriate classification of thyroid tumors based on the potential for malignancy so that it is hoped that the management of benign thyroid lesions will not be too aggressive. In 2017 the WHO issued a classification of thyroid tumors to clarify what was previously made of a widely misunderstood lesion [1].

In 2016 Nikiforov et al. proposed the term non-invasive follicular thyroid neoplasm with papillary-like features (NIFTP) A noninvasive follicular thyroid neoplasm with papillary-like nuclear features is a well-defined, noninvasive thyroid tumor with a follicular growth pattern and nuclear feature characteristic of papillary thyroid carcinoma, but without the presence of psammoma bodies or well-formed papillae and without the characteristic findings poorly differentiated carcinoma or papillare thyroid carcinoma aggressive subtype. This is considered a pre-malignant lesion [2].

Categories for well-differentiated thyroid tumors based on histological characteristics are divided into follicular and papillary types. Follicular thyroid tumors, consisting of follicular cells lined with cuboidal epithelium, have a prevalence of about 10-15% of total thyroid cancers. Based on the nature of its invasion of the thyroid capsule, it is divided into follicular adenoma, which is a follicular tumor that does not invade the thyroid capsule, and follicular carcinoma, which is a follicular tumor that invades the thyroid capsule. Papillary thyroid cancer is the most common type of thyroid tumor. It is an epithelial tumor that has a good prognosis, in contrast to the papillary sub-follicular type based on its unique nuclear feature characteristics [1].

Another very unique thyroid lesion is NIFTP, this type is clinically and histopathologically distinct. Also

known as the non-invasive encapsulated follicular variant of papillary thyroid carcinoma. NIFTP differs from classic papillary tumor carcinoma. NIFTP has the property of very slow growth and rarely become malignant, this is important to distinguish it from other types of malignant tumors. The diagnosis of NIFTP is made based on the pathological anatomical results of the resection revealing the tumor and confirmation of several criteria such as nuclear feature of papillary thyroid carcinoma, the full encapsulation of the tumor, no vascular or capsular invasion, follicular pattern of growth with no psammoma bodies, and no evidence of necrosis. Molecular examination is a major part of the diagnosis regarding the unique genetic structure of NIFTP that includes markers like an activating mutation in one of the RAS genes (NRAS most common, 36–67 %), THADA fusions (22 %), and PAX8-PARG rearrangement (4–22 %) [1].

NIFTP was reclassified with the aim of obtaining a characteristic clinical picture of these lesions in an effort to appropriately manage patients and predict treatment costs to prevent potential overtreatment and reduce the burden of patients with a "cancer" diagnosis [3]. Here, we present a 13-year old female child with lumps on the right and left neck, after a total thyroidectomy was found final pathology report identified bilateral NIFTP lesions.

2. CASE REPORT

A 13-year-old female patient (RM 159781) came to the ENT Clinic MA Sentot Patrol Hospital on September 2019 with a lump in the anterior aspect of the neck that was first noticed about 12 months back before entering the hospital. Initially the lump was small and gradually got bigger, feeling some discomfort in the neck but not painful, eating and drinking did not choke, it wasn't difficult to swallow, there was no hoarseness, no shortness of breath. Complaints of frequent pounding chest, trembling hands, irritability, weight loss and gain, fatigue, lots of sweating are not complained of. There was no history of chronic medical condition. There was no family history of any cancers, nor a history of exposure to radiation.

On physical examination, there was compost mental awareness, cooperation, blood pressure 110/70 mmHg, pulse 84x / minute, respiratory rate 20 x / minute. On physical examination the ears, nose and throat were within normal limits, on the neck there was a nodule in the right lobe of the thyroid measuring ± 5 x 3 x 2 cm and the left lobe of the thyroid measuring ± 4 x 3 x 2 cm. The surface is bumpy, well-defined, the consistency is soft and not painful. When swallowing the mass moves too. It was found that there was multiple neck lymph node enlargement at level III and IV bilateral in size of 0.5 - 2 cm.

Intial ultrasound (US) of the thyroid gland, it was found that the right thyroid was enlarged with multiple inhomogen hyperechoic nodules in the right thyroid, Tirad 4A (simple neoplastic pattern). Enlarged left thyroid with multiple inhomogeneous hyperechoic nodules in the left thyroid, Tirad 4A (simple neoplastic pattern). There was multiple lymph node enlargement in the right and left neck area.

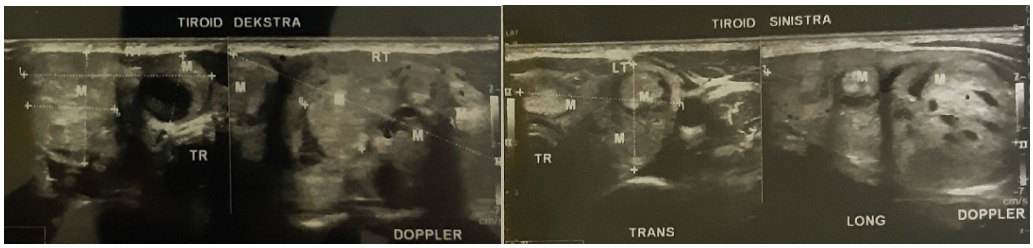

Figure 1. Right and left thyroid ultrasound

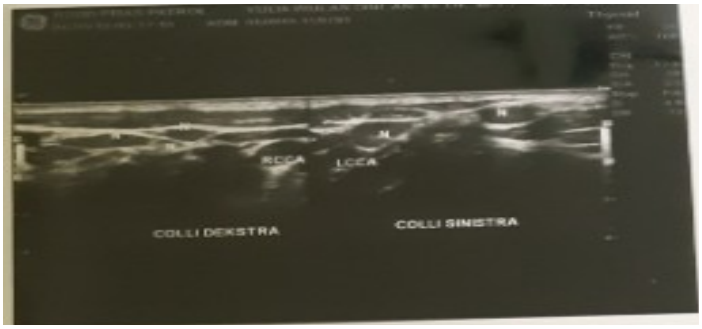

Figure 2. Ultrasound of cervical lymph nodes

In this patient, immunoserology examination was also carried out. Free T4: 1.40(0.93 – 1.70), Sensitive TSH: 1.34 (0.27 – 4.20) with a euthyroid impression. From the results of ultrasound and immunoserological examination, a thyroid tumor was suspected, for that she was referred to the tertiary hospital for fine-needle

aspiration for cytology (FNAC). Undertook FNAC biopsy of right and left lobe nodule. Another solid nodule in the right and left lobe suspicious neck node enlargment was also aspirated. Aspiration of the right thyroid, it appears hyperplastic oval round tumor cells, clusters of microfollicel structure and partially growing papillifers, polymorphic nuclei, hyperchromatic, chromatin rather coarse and appearing inclusions in the nucleus cytoplasm. Also visible are scattered lymphocytes and polymorphonuclear (PMN) cells. Aspiration of the suspected right neck lymph nodes shows a tumor mass as mentioned above, as well as lymphocyte and PMN cells. The aspiration of the left thyroid and left neck lymph nodes showed a tumor mass as mentioned above as well as lymphocyte and PMN cells. Conclusion: Malignant lesions of bilateral thyroid and bilateral neck lymph nodes were suspected of bilateral thyroid papillary carcinoma and had metastasized to bilateral neck lymph nodes.

The patient is planned for surgery to remove the thyroid gland for that a Neck computed tomography examination is performed and found a well-defined bulky lobulated inhomogen solid and cystic mass on the right thyroid with dimensions of approximately 65.1 x 28.8 mm accompanied by calcified punctate faint pressing the thyroid cartilage and trachea. There was a well-defined bulky lobulated inhomogen solid and cystic mass from the left thyroid to the upper left anterior mediastinum with dimensions of approximately 54.4 x 28.5 mm. There was an enlarged left posterior neck lymph node, the largest measuring 18.9 x 9.9 mm.

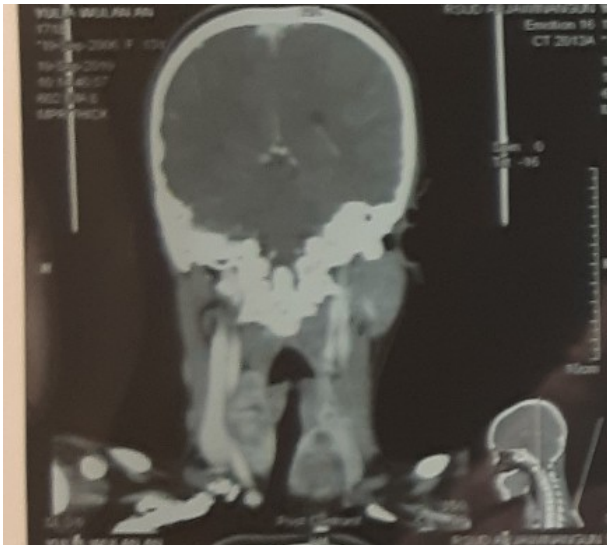

Figure 3. CT Scan of the coronal neck section

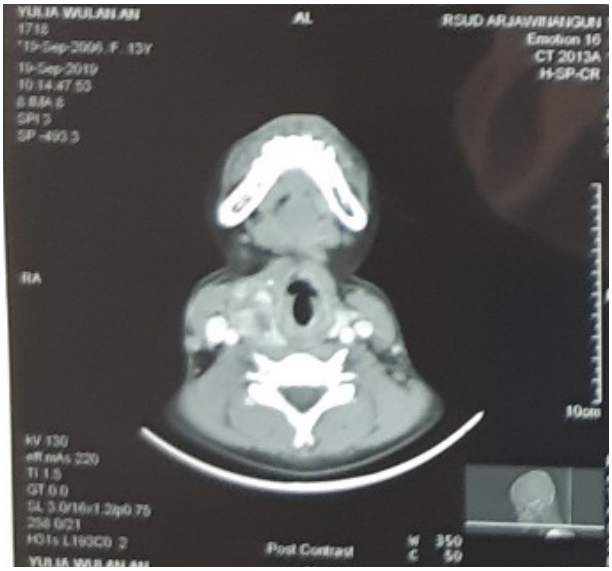

Figure 4. CT scan of the axial section of the neck

The patient was diagnosed with bilateral thyroid papillary carcinoma with bilateral neck lymphadenopathy. And it is planned to do a total thyroidectomy with bilateral neck dissection. On November 16, 2019, a total thyroidectomy was performed with preparation for bilateral neck dissection.

At exploration, both lobes of the thyroid gland were bumpy with multiple nodule enlarged. Bilateral recurrent laryngeal nerves and parathyroid glands were identified and preserved. There were not found enlarged lymph nodes in the bilateral neck. The specimens that have been removed are inspected, drain is installed, the operating field is closed.

Postoperative period was uneventful. There are no signs and symptoms of hypocalcemia. Serum calcium levels are within normal limits. The patient was treated for five days, Patient is discharged after the drain was removed, surgical wound and the general condition is good. One week post operation, patient went to the ENT clinic with the results of the anatomical pathology examination. The histopathology report Macroscopic: 2 pieces of united thyroid tissue weighing 45 grams, each measuring 5 x 2.5 x 2 cm and 4.5 x 3 x 1.5 cm. In the lamellation, a multinodular mass appears gray-brown in color. Microscopic: the preparation is a piece of thyroid tissue covered with fibrous connective tissue capsules and thyroid follicles consisting of a proliferation of thyroid follicles covered with a layer of cuboidal epithelial cells with cell nuclei within normal limits, some of the follicles appear dilated and bleeding. There is seen the Sanderson Polster and Plummer effect. Conclusion: bilateral thyroid follicular adenoma with cystic degeneration and bleeding.

There are differences in interpretation between the FNAC examination and the postoperative anatomical pathology report, for this reason a review of the thyroid specimen is performed, and the result is Microscopy: the

preparation is a piece of thyroid tissue covered with fibrous connective tissue capsules and thyroid follicles consisting of proliferation of thyroid follicles covered with a layer of cuboidal epithelial cells with the nucleus is within normal limits, some of the follicles appear to be dilated and bleed. There is seen the Sanderson Polster and Plummer effect. In one focus a nodule lined with fibrous connective tissue capsules containing proliferation of thyroid follicles. Thyroid follicles are composed of the proliferation of epithelial cells of the thyroid cells with a partially oval morphology, eosinophilic cytoplasm, a round nucleus partly ground glass appearance. No capsule invasion, intravasa invasion or necrosis were seen. There is no visible lymphoid tissue structure. Conclusion: Non-invasive follicular thyroid neoplasm with papillary like nuclear feature. The patient was routinely followed up after surgery, and evaluated for no signs of enlarged lymph nodes and other post operative complication

3. DISCUSSION

Thyroid nodules in children are rare but often have a greater risk of malignancy than adults. The incidence of thyroid nodules in children is about 3.7% in healthy children aged 11-18 years old. Compared with adults, thyroid nodules in children have a higher potential for malignancy, that is 16% in children and 5% in adults. Thyroid nodules are more common in women, this has been reported from several previous studies which stated is likely secondary to the estrogen sensitivity of the thyroid gland. Thyroid cancer in children is rare and usually appears at an advanced stage where lymph node involvement and lung metastases are found compared to cases in adults [4].

Several literature reports that thyroid lesions in children have about 1.6 times higher risk of cancer than adults. Based on data published by the World Health Organization, papillary thyroid carcinoma accounts for about 90% of all thyroid cancers. The most common is the classic variant of papillary thyroid carcinoma, especially in the group of children over the age of 12 years. In recent decades, several researchers have stated that follicular variants of papillary carcinoma, including non-invasive follicular variant of papillary carcinoma and invasive follicular variant of papillary carcinoma, have molecular differences and their prognosis. In 2015 the term non-invasive follicular variant papillary carcinoma replaced with the term non-invasive follicular thyroid neoplasm with papillary-like nuclear features by Endocrine Pathology Society [5].

Based on the meta-analysis, it is known that the prevalence of NIFTP is about 9.1% of all papillary thyroid carcinomas worldwide, even though NIFTP is actually a noncancerous lesion. The prevalence in the Asian population is very rare, around 1.6% compared to the western population, which is 13.3%. NIFTP cases can occur in adults but sometimes also found in the pediatric population [6].

NIFTP is clinically similar to most other thyroid neoplasms. Thyroid nodules may be detected on routine or focused physical examination or incidentally during unrelated diagnostic imaging. If non-invasive follicular thyroid neoplasm with papillary-like features grows large enough, it exerts a mass suppression effect on surrounding structures, which can cause dysphonia, globus sensation, or airway compromise [3].

Most cases of NIFTP based on some literature show no symptoms or complaints with bilateral thyroid enlargement or only one lobe. Regarding thyroid involvement, there is some variation in the degree of thyroid involvement. One case had multinodular gland enlargement, in another case only one gland was involved. Our patient had thyroid enlargement in both lobes which is a classic feature of thyroid nodules [1].

Various investigation modalities can be used to assess the characteristics of thyroid nodules including thyroid function tests, ultrasound, fine needle aspiration biopsy, radionuclide scans and evaluate patient demographic data. In adults' population, the results of these examinations are used to consideration whether or not a patient needs thyroidectomy. However, they can also be used for diagnosis in the pediatric population, and as a consideration for partial or total thyroidectomy [4]. Clinically, NIFTP is generally the same as other thyroid nodules, and can be detected on physical examination or on imaging studies of the neck. On ultrasound examination, the NIFTP image shows a well-defined oval or round nodule, hypervascular with a hypoechoic border, this is different from the invasive follicular variant of papillary thyroid carcinoma which has a more irregular or lobulated border and are mostly hypervascular [7].

From the ultrasound examination, several echogenicity variables were found, such as hypoechoic, hyperechoic or isoechogenic. The results of the ultrasound assessment are highly dependent on the skill and experience of the operator. In addition, there are limitations to the ability of ultrasound machines when used to assess thyroid nodules. Nodules that are too small may not be accurately identified. Therefore, ultrasound findings should be interpreted with caution because they do not have perfect sensitivity [1].

The ultrasonographic findings for NIFTP are smooth, wider than tall, without calcification and occur in multinodular glands. On Doppler examination the flow pattern was perinodular and intranodular with flow rates similar to those of minimally invasive follicular carcinoma and follicular adenoma [6]. Thyroid function tests are necessary to determine thyroid gland activity. According to the literature of all cases of NIFTP showing a euthyroid result this indicates that the nodule

is inactive [1]. Likewise, our patient showed a euthyroid result.

CT scan examination cannot be used to determine whether a lesion is cancerous or benign because it has not been shown to be sensitive and specific. Therefore, the lifetime risk of cancer associated with CT is not justified (the lifetime risk of cancer associated with CT is estimated to be 2/1000 to 3/1000 in children under 15 years of age) [4].

In children, cytology and fine needle aspiration are controversial. This examination is useful in preoperative planning. Findings of fine needle aspiration may be malignant, benign, indeterminate, or follicular. In follicular lesions it is difficult to distinguish whether it is malignant or benign because of the inability of FNA to assess capsular invasion. If the lesion is found to be malignant, the patient should undergo total thyroidectomy as initial management. However, if the lesion is known to be uncertain or benign, it is sufficient to perform a lobectomy. If the FNA result shows a nodule, a benign lesion or a cyst, the patient can be observed if the lesion is small to avoid operative intervention. The accuracy rate of FNA in adults can reach 97%, while in the pediatric population the accuracy rate only reaches 90%. Other disadvantages of FNA include relying on the experience of cytopathologists, sampling errors, and the need for sedation in young children [3]. The FNAC sample showed hypercellular with presumably neoplastic cells with characteristic focal papillary thyroid carcinomas arranged in microfollicles. The nuclear characteristics are finer than conventional papillary thyroid carcinomas; nuclear inclusions are very rare or absent in comparison with the classic papillary type carcinoma and no papillae are found. Cytological examination was unable to differentiate the invasive encapsulated follicular variant of papillary thyroid carcinoma from NIFTP because the capsule could not be evaluated by FNA; however, NIFTP has few intranuclear inclusions and usually does not show papillae on FNA. Most cases of NIFTP were grouped into the categories of atypia of unknown significance (AUS) / follicular lesion of unknown significance (FLUS), follicular neoplasm (FN) / suspicious for follicle (SFN), and suspicious for malignancy [6].

In general, NIFTP appears as a well-defined or encapsulated solid nodule. The excised surface is often paler than the normal surrounding thyroid tissue and necrosis and bleeding may not be visible. The capsule may be thin and difficult to see; however, a clear demarcation between the lesion and the surrounding thyroid tissue can be seen. In the NIFTP series studied by Nikiforov et al., we found 109 tumors ranging in size from 1.1 to 9 cm [3].

Microscopically (histologically) the NIFTP is a nuclear picture of existing papillary thyroid carcinoma: Shape and size: nucleus enlargement, elongation, crowding, overlapping. Nuclear membrane irregularities: pseudo inclusions, grooves, irregular contours. Chromatin characteristics: glassy core, clean with margins. The fibrous capsule may be thin, thick, partial or the lesion may be well demarcated from adjacent thyroid tissue. Follicular growth pattern can be normofollicular, microfollicular, or macrofollicular with abundant colloid [6].

NIFTP behaves differently from classic papillary thyroid carcinoma both histopathologically and clinically. Where NIFTP is experiencing very slow growth and rarely shows the potential for malignancy. This is important to differentiate from other malignant thyroid tumors [1].

The characteristics of NIFTP tumors have many similarities to those of benign follicular adenomas. Thus, as with benign adenomas, NIFTP management for total thyroidectomy or radioactive iodine therapy may not be necessary. With less invasive treatment, it is hoped that it can improve the patient's quality of life and reduce psychological stress on cancer diagnosis [8].

This patient underwent a total thyroidectomy surgery with preparation for bilateral neck dissection on the basis of the FNAC results suggesting papillary thyroid cancer and the results of ultrasound and CT scan showed enlarged cervical lymph nodes. At the time of the operation, there was no enlargement of the cervical lymph nodes, only the two enlarged thyroid glands were lumps resembling these lymph node nodules, which may have been read from ultrasound and CT scan as if there were enlarged lymph nodes.

Total thyroidectomy is the procedure of choice in lesions identified as cancer, whereas lobectomy is performed on lesions whose diagnosis is uncertain or benign. In addition, postoperative I131 therapy was performed in malignant cases and thyroglobulin levels were monitored after treatment for recurrent disease. The overall prognosis for thyroid cancer is excellent with a survival of about 98.8% at 10 years in children [4]. Total thyroidectomy in children has more risks and complications than adults. Luiz Paulo et al in their report stated that about 24% of temporary hypocalcemia and permanent hypocalcemia occurred in about 16% of patients after total thyroidectomy. Other complications that are often encountered are recurrent laryngeal nerve injury, hematoma and postoperative bleeding [9].

The most common postoperative complications of total thyroidectomy are recurrent laryngeal nerve injury and hypocalcemia. In our patient, no hypocalcemia and recurrent laryngeal nerve injury were found. Hypocalcemia results from removal of the parathyroid glands, which may be carried away by removing the thyroid gland at the time of surgery. In addition, the parathyroid glands may also become devascularized

during thyroid gland dissection. Hypocalcemia can be temporary or permanent. Transient hypocalcemia is considered moderate risk and is easily managed with oral calcium supplementation [4]. Another risk of total thyroidectomy is recurrent laryngeal nerve injury (RLN), resulting in hoarseness, dysphagia, and respiratory failure if bilateral injury occurs. In the literature, it is reported that about 1% of permanent RLN injuries occur after total thyroidectomy. In patients with NIFTP, after complete resection of the tumor mass and histopathological examination, no malignancies including microcarcinoma were found. The postoperative follow-up protocol is still a matter of debate. Some consensus states that drugs to suppress TSH are not necessary. According to the American Thyroid Association, cervical ultrasonography, thyroglobulin (Tg) and antithyroglobulin (TgAb) antibodies are not required, while some authors recommend monitoring as in low-risk papillary thyroid cancer. Change of a name by omitting the term cancer, changing the course of the disease to a non-malignant, and the definition of strict diagnostic criteria to exclude the possibility of metastases, treating patients with NIFTP the same as patients with papillary thyroid carcinoma does not appear to be warranted.

NIFTP patients without any signs of malignancy and ultrasound examination did not reveal any remaining thyroid lobe tissue (after lobectomy) and can be treated as in the case of follicular adenoma. This management is in accordance with the currently used nomenclature, that is NIFTP which does not contain the term cancer and the nature of this lesion is non-malignant. It is based on the presence of clear diagnostic criteria, molecular signature, no evidence of metastasis and no clinically apparent recurrence [10].

4. CONCLUSION

The current report demonstrated a case of NIFTP affecting a young female child, NIFTP as a new entity is needed more evidence-based approach to managing thyroid neoplasms. Despite the fact that NIFTP is currently based on a histological diagnosis, clinicians must be aware of the ultrasonographic, CT scans and cytological findings of nodules corresponding to NIFTP. With the inclusion NIFTP as a non-malignant lesion is impact in technique of surgery, clinical treatment and follow-up. In addition, clinicians and pathologists must be familiar with the histological criteria for the diagnosis of NIFTP to prognosticate and manage patients appropriately to prevent potential overtreatment and reduce the burden to patients of a “cancer” diagnosis.

REFERENCES

[1] Mohamed SAH, Walid EA, Abdallah ES et al. First bilateral non-invasive follicular thyroid neoplasm with papillary-like nuclear features (NIFTP) co-occurring with bilateral papillary thyroid microcarcinoma. Case report and literature review. International Journal of surgery case report. Vol 78 januuary 2021 page 411-416.

[2] Rosario PW, Mourão GF: Noninvasive follicular thyroid neoplasm with papillary-like nuclear features (NIFTP): a review for clinicians. Endocr Relate Cancer. 2019 May 1; 26(5) R259-R266.

[3] Jug R, Jiang X. Noninvasive Follicular Thyroid Neoplasm with Papillary-Like Nuclear Features: An Evidence-Based Nomenclature Change. Pathology Research International 2017 (7) 1-6.

[4] Nini K, Cynthia G, Clinical Study : Thyroid Nodules in Children: A Single Institution’s Experience. Journal of Oncology Volume 2011, Article ID 974125, 4 pages doi:10.1155/2011/974125

[5] Rossi ED, Mehrotra S, Kilic AI, et al. : Noninvasive follicular thyroid neoplasm with papillary-like nuclear features in the pediatric age group. *Cancer Cytopathol.* 2018;126(1):27–35.

[6] Jug R, Poller D, Jiang X. NIFTP. PathologyOutlines.com website. https://www.pathologyoutlines.com/topic/thyroidglandniftp.html. Accessed May 29th, 2021.

[7] Esther DR, William CF, Zubair B et al. Noninvasive Follicular Thyroid Neoplasm with Papillary-Like Nuclear Features (NIFTP): Update and Diagnostic Considerations—a Review. Endocrine Pathology (2019) 30:155–162

[8] American Thyroid Association, Clinical Thyroidology for the Public vol 11 issue 8 August 2018

[9] Santhosh KN, Thansingh T, Elizabeth MI, et al. Papillary Carcinoma Thyroid in a Seven Year Old Child: A Case Report, BMH Medical Journal 2014;1(4):79-82

[10] Rosario PW, Mourão GF: Noninvasive follicular thyroid neoplasm with papillary-like nuclear features (NIFTP) inchildren and adolescents. *Endocrine.* 2018;61(3):542–544.