Follicular Lymphoma Mimicking a Benign Submandibular Gland Tumor

Izry Naomi Lumbantobing*

Royal Prima Hospital, Medan, Indonesia
**Corresponding author. Email: izrynaomi@gmail.com*

ABSTRACT
Follicular lymphoma of the submandibular gland is exceptionally uncommon. Lymphomas within the head and neck region do not have particular clinical behavior and manifestation. Furthermore, frozen section and fine-needle aspiration cytology can only provide a provisional diagnosis. Therefore, surgeons might not be aware and send patients for surgical treatment before determining a final diagnosis. We describe a case of follicular lymphoma in a patient formerly identified as a benign submandibular gland tumor.

Keywords: *non-Hodgkin's lymphoma, follicular lymphoma, neck mass, salivary gland, submandibular gland.*

1. INTRODUCTION

The third most common malignancy in the head and neck area after squamous cell carcinoma and adenocarcinoma is lymphoma. Its accounts for 2%-5% of salivary gland neoplasms [1, 2, 3]. The parotid glands are most frequent involved, accounting for 70% of cases, followed by the submandibular glands (25%), sublingual glands, and minor salivary glands (<10%) [1,2,3,4,5].

Classification of lymphoma by histopathology divided into Hodgkin's (HL) and non-Hodgkin's (NHL). According to their origin within or outside the lymph nodes, they can be subdivided into intranodal and extra-nodal types. Non-Hodgkin's lymphoma accounts for 2-4% of head and neck lymphatic tumors, 4-5% of all cancers [6,7,8], and 86% of lymphoma cases [9].

They are predominantly nodal and primarily found in the nasal cavity, paranasal sinuses, Waldeyer's ring, oral cavity, and salivary glands [7]. A salivary gland NHL is rare, most effective 5-10%, and represents 1.7% - 3.1% of all salivary gland malignant tumors [2,3,6,7,9,10,11,12].

Rzepakowska et al. reported 73.2% of nodal type lymphomas and 26.8% of extra-nodal type, which covered: submandibular glands, parotid glands, parapharyngeal space, hypopharynx, and larynx [13].

Follicular lymphomas account for only one-third of NHL. It consists of a low to intermediate-grade lymphoma that shows a follicular architecture and represents the neoplastic counterpart of germinal center B lymphocytes [14]. The submandibular triangle is a site susceptible to malignancies, including lymphoma. However, because lymphoma of the submandibular gland is relatively rare, most surgeons did not anticipate it pre-operatively. Moreover, most pathologists find it hard to provide a definitive diagnostic report on the frozen section or fine-needle aspiration biopsy (FNAB). That is why the patients underwent various surgical treatment before making a final diagnosis.

In this report, author present a case of follicular lymphoma in a patient previously diagnosed with benign submandibular gland tumor.

2. CASE REPORT

A 68 years old male came to the outpatient clinic of Royal Prima Hospital Medan with left-sided upper neck swelling for six years. The swelling first noticed was a size of a marble. It enlarges gradually but remains no pain occurs. The patient did not complain any respiratory or swallowing problems. Besides being a former heavy smoker, he has no significant medical history or issues.

Figure 1. Patient before surgery in anterior and lateral position

Physical examination showed a mass on the left submandibular area approximately 10 x 6.5 cm in size. It extends from the infra-auricular region, almost reaching the midline of the neck and parallel to thyroid cartilage inferiorly—no underlying skin changes. When palpated, it was painless, non-tender, fixated but with firm boundaries. The oral cavity and oropharynx appeared normal. No neck lymph node enlargement was palpable. No cranial nerve involvement.

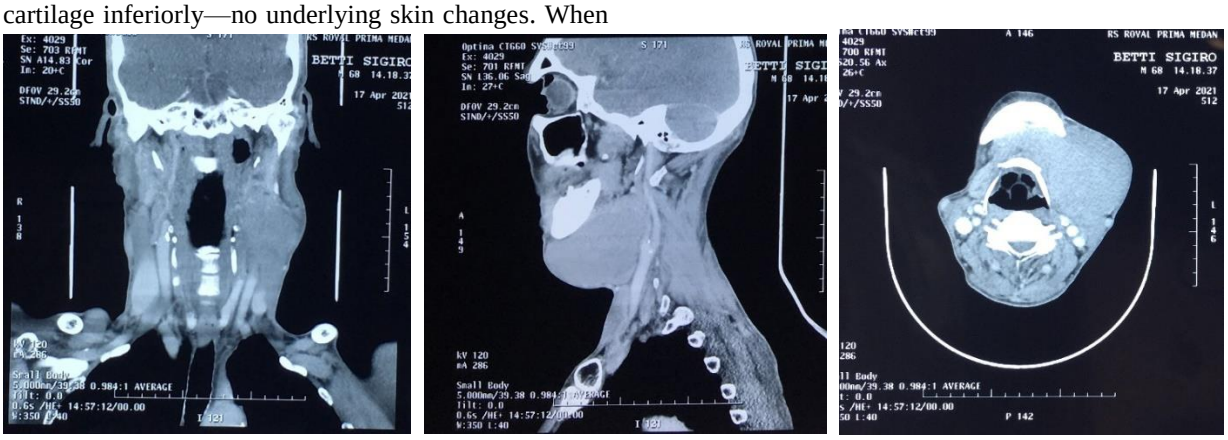

Figure 2. CT scan showing a well-defined isodense lesion measuring 9.7 x 6.3 x 6.2 cm, indistinguishable from the submandibular gland

Contrast computed tomography scan of the neck revealed a large, slightly enhanced, oval-shaped solid mass, with a regular edge in the submandibular region (measured 9,7 x 6,3 x 6,2 cm). It is attached to the left parotid and left masseter, infrahyoid, and sternocleidomastoid muscles. Difficult to distinguish from the left submandibular gland. Multiple lymphadenopathies in levels 2, 3, 4, and 5 are noted. Fine needle aspiration cytology (FNAC) features were suggestive of a benign smear. The patient underwent screening for HBsAg, HIV, and SARS Cov 2 RNA, and the results are negative.

Based on these results, we diagnosed this patient with a benign tumor of the left submandibular gland. We performed surgical excision. During excision, we noticed swelling and inflammation of the submandibular duct. The mass and the submandibular salivary gland were excised entirely, and the specimen was sent for histopathological analysis. The postoperative course was uneventful, and the patient was discharged after six days.

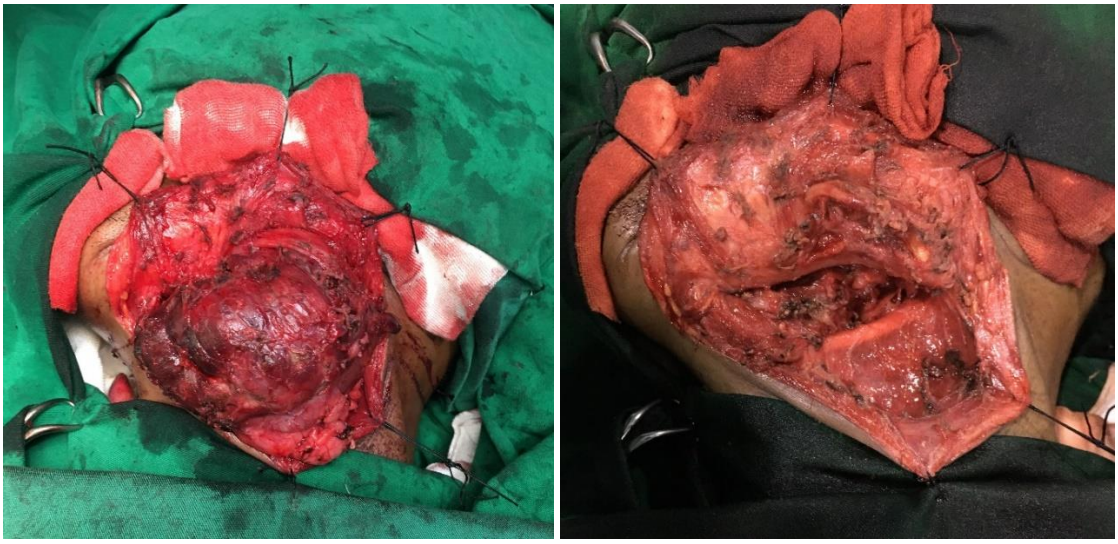

Figure 3. The mass was exposed and removed

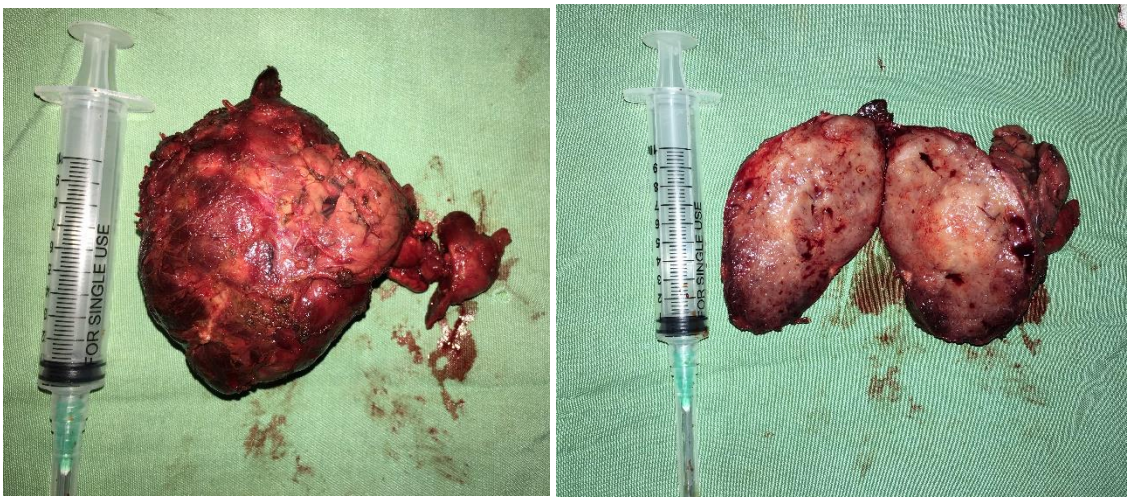

(a) (b)

Figure 4. Gross specimen with the submandibular gland (a). Cut sections show a yellowish core surrounded by brownish areas (b).

Figure 5. Patient 2 weeks after surgery in anterior and lateral positions

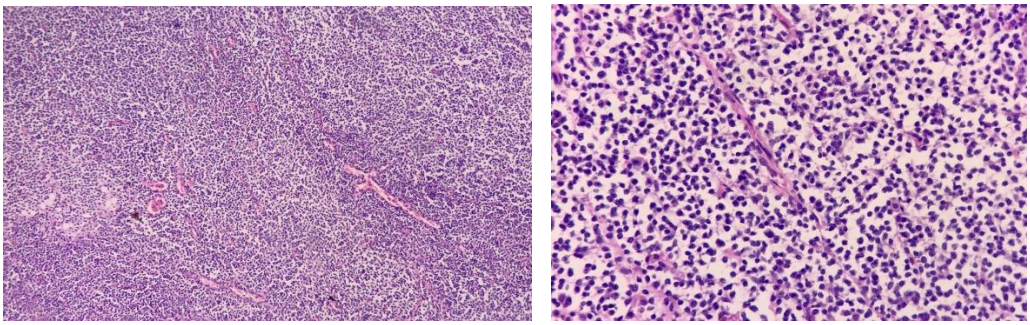

(a) (b)

Figure 6. Hematoxylin and Eosin stain, 100x (a) and 400x (b)

Histopathological examination on hematoxylin and eosin (HE) stained sections revealed the following aspects: the lymphoid tissue has disorganized and consists of a monotonous distribution of atypical and pleomorphic lymphoid cells. The sizes are relatively more significant than mature lymphocytes and diffusely distributed. The enlarged nucleus (increased N/C ratio), round and oval, chromatin is rough with prominent nuclei and eosinophilic cytoplasm. Atypical mitoses are easy to find. Proliferative blood vessels were also found with mild infiltration of mature lymphocyte cells, as well as interstitial bleeding in several places. The salivary gland cell structure and configuration are still within normal limits.

The provisional diagnosis is non-Hodgkin's lymphoma, a small cell type. Immunohistochemical examinations were proceeded to confirm the type of lymphoma.

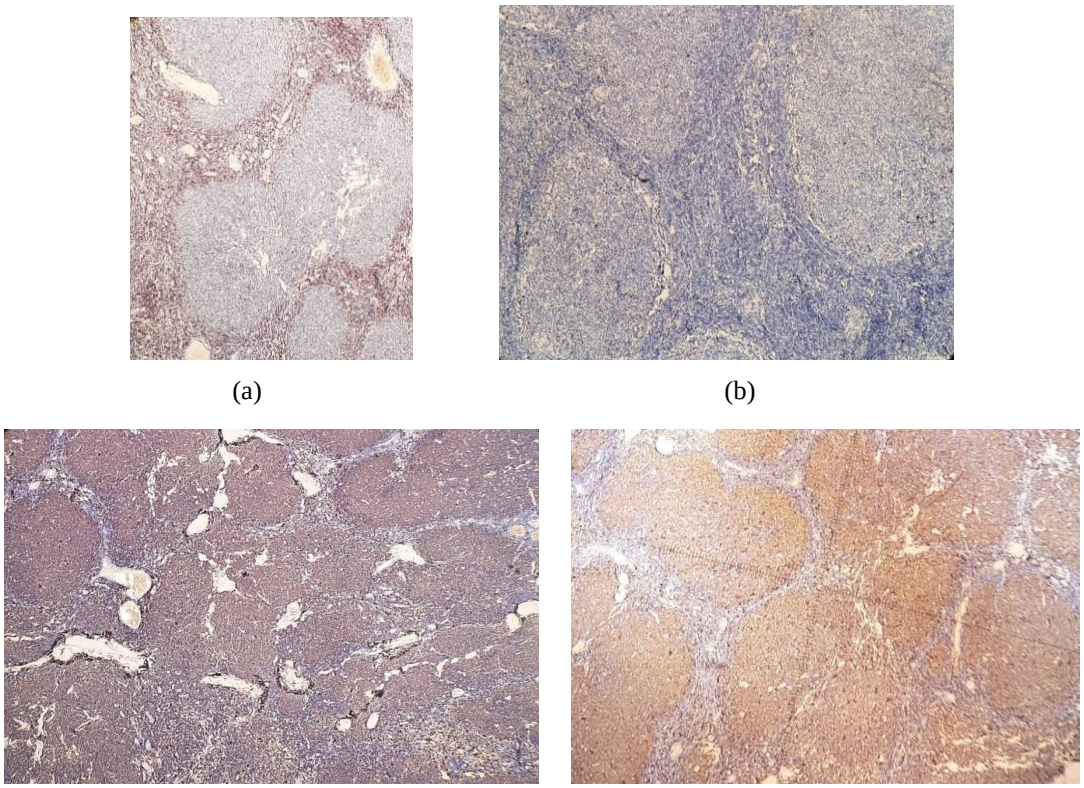

(a) (b)

(c) (d)

Figure 7. Immunohistochemistry revealed that the cells were negative expression for CD3 (IHC stain, ×100) (a), positive < 30% of cell tumor for Ki67 (IHC stain, ×200) (b), and strong positivity for CD20 (c) and Bcl-2 (d). (IHC stain, ×100)

Immunohistochemistry indicated that the cells were firmly positive for Bcl-2 and CD 20 (both are cytoplasmic markers), positive for Ki67 in < 30% of cell tumors, and negative for CD3.

Based on the results of immunohistochemical profiling, author establish the diagnosis with follicular lymphoma. The patient was then referred to a higher center for further examinations and treatment

3. DISCUSSION

Non-Hodgkin's lymphoma is higher in males with the ratio male to females 2:1. It occurs especially in more than 65 years old, and those with autoimmune disease or there is a history of hematological malignancies in their family [9,15].

There are non-modifiable and modifiable risk factors for NHL. The non-modifiable factors including sex, age, race/ethnicity, family history, autoimmune disease, and immunosuppression. On the other hand, modifiable risk factors can be radiation and chemical exposure, obesity, tobacco, smoking, alcohol, and breast implants [15]. In our patient, other than being an ex-heavy smoker, he has no other significant risk factor.

The clinical manifestations of lymphomas in the head and neck region are varied but usually lack specific characteristics. Nevertheless, symptoms can consist of indolent cervical lymphadenopathy, fatigue, occasionally B-symptoms such as high fever, night sweats, weight loss, susceptibility to infections, and changes in the blood work [16]. Onset of symptoms and hospitalization in patients suffering from lymphoproliferative neck diseases reported to be ranged from 0.5 to 36 months, with the average being 7.5 months [14]. Here, our patient did not have the occasional B symptoms or any other complaints and significant medical findings except for the mass on the submandibular region for the last six years.

On a CT scan, some lymphoproliferative malignancies can demonstrate heavy contrast enhancement, some just slightly. It has been stated that lymph nodes with lymphoma involvement are characterized by iso or hypodensity oval lesions compared to muscular tissue [14]. This patient's CT scan showed a mass with slight enhancement, solid and oval-shaped with a regular edge.

Sen et al. [5] reported a retrospective review of five primary salivary gland lymphomas cases in two years. The cases consist of two patients with parotid region swelling (initially diagnosed with Warthin's tumor) and three with submandibular region swellings (suspected with chronic sialadenitis and pleomorphic adenoma). Out of these five patients, definitive diagnoses were made after surgical excision of the mass.

Fatima et al. and Nassie et al. [13] also reported that in several cases of their case series, the FNAC results were non-diagnostic or inconclusive, so the surgical procedure has to be done to confirm the diagnosis. From the clinical work up, the diagnosis of primary non-Hodgkin's lymphoma is not anticipated in this case, and so we proceed with the surgical treatment.

As previously mentioned, lymphomas of the salivary glands may include extra-nodal and nodal-type lymphomas. Differentiating the both types can be difficult because lymphoma cells often spill over into the adjacent tissues [17]. Cervical lymphadenopathy is the most frequent head and neck presentation in nodal type NHL. While in extra-nodal NHL, the sites can include skin, nasal cavity and paranasal sinuses, Waldeyer's ring, oral cavity, salivary glands, thyroid, and larynx [18].

Primary lymphomas of the salivary glands are infrequent, with only 2–5% of all salivary gland neoplasms. Primary salivary gland lymphoma can be considered when the parenchyma is involved. Intraglandular lymph nodes involvement without infiltration of the parenchymal gland can be considered a nodal origin [4]. However, a lesion should be considered primary salivary gland lymphoma if it has no capsule and no lymph nodes found [19]. Hyman and Wolff suggest the diagnosis criteria for the primary lymphoma, which are: a) first clinical presentation of the disease is the involvement of the salivary gland; b) involvement of salivary gland parenchyma histologically proved; c) architectural and cytologic proof of the malignant character infiltration [12].

In NHL, 71.9% primarily arise in the lymph nodes, and only 29.1% are extra-nodal origin [5]. In this case, the lesion is capsulated, and the salivary gland cell structure and configuration are still within normal limits. Therefore, one could consider this case as a nodal-type origin.

Non-Hodgkin's lymphoma derives from a lymphocyte progenitor and accommodates a heterogeneous group of exceptionally various malignancies. It could developed from B-cells, T-cells, and NK cells [7, 19]. Typically, NHL in the neck are from mature B cells origin [10, 17]. The most common type is diffuse large B-cell lymphoma (30% of all malignancies) followed by follicular lymphoma, marginal nodal zone B-cell lymphoma, Mantle cell lymphoma, extra-nodal marginal zone B-cell lymphoma, B-cell chronic lymphocytic leukemia/ small lymphocytic lymphoma, and extramedullary plasmacytoma [14].

Histologically, NHL can be categorized into low and high-grade subtypes. Low-grade B cell NHL commonly grows slowly (indolent) and the treatment may not immediately need. They can relapse and remit and are mainly incurable. On the other hand, high-grade B cell NHL is typically aggressive and can be unexpectedly fatal if not treated properly; however, they are high curability with prompt treatment [20].

In the United States, 60 percent of the cases were rapidly progressing or high-grade NHL. Diffuse large B-cell lymphoma (DLBCL) is the most frequent type of the aggressive NHL. As for slowly progressing or low-grade NHL, 40% where follicular lymphoma (FL) being the most frequent type of indolent NHL [15].

Follicular lymphoma is a slow-growing NHL from B-lymphocytes and accounts for one-third of all NHL [6]. The definitive diagnosis requires haematoxylin and eosin staining of the histological specimen, immunostaining for B cell markers (CD20), T cell marker (CD3), and proliferative marker (Ki67). When treatment of R-CHOP is possible, immunohistochemical detection of CD20 antigen on malignant B-lymphocytes is also required [21]. Presence of chromosomal translocation t (14;18) (q32; q21) or variation in 85% of the cases is the hallmark genetic abnormality related to FL. It pairs the chromosome 14 containing immunoglobulin heavy chain gene with chromosome 18 containing the Bcl2 oncogene primary to replace expression of the Bcl2 protein [22].

The Ann Arbor staging, being critical, is the most broadly system used as treatment guidelines and to determine follicular lymphoma prognosis. Stage I is confined to a single lymph node region (I) or a single extra-nodal site (I-E). Stage II consists of two or more areas of nodal involvement on the same side of the diaphragm (II) or one or more lymph node regions with an extra-nodal site (II-E). Stage III involved lymph node on both sides of the diaphragm (III), possibly with an extra-nodal site (III-E), the spleen (III-S), or both (III-SE); and stage IV involve the liver, marrow, or other extensive extra-nodal diseases. The system is also defined into substage A for localized, extra-nodal disease, E for the absence of systemic signs, and B for the presence of unexplained weight loss (10% in 6 months), and unexplained fever, and night sweat [18].

The International Prognostic Index (IPI) is significantly more accurate to help predict the risk of relapse and long-term survival. This index consists of a) age more than 60 years, b) advanced stage (III or IV), c) extra-nodal site involvement >1, d) performance status ≥ 2, e) raised serum lactate dehydrogenase level. The total number of above-listed features can be stratified as risk groups as follows: 0–1 (low), 2 (intermediate low), 3 (intermediate high), and 4 or 5 (high). Five-year survival rates prediction of these groups are 73%, 51%, 43%, and 26%, respectively [18].

Localized low-stage indolent lymphomas are sufficiently treated with radiotherapy [19]. Fifty percent of patients also respond effectively to single-agent rituximab [23]. Advanced staged lymphomas need aggressive chemotherapy. Rituximab-CHOP is commonly provided every three weeks for 6 to 8 cycles [19]. Localized high-grade lymphomas are treated with a combination of radiotherapy and chemotherapy [1,19].

Regardless, patients with no signs and a small disease volume can often be observed over time. The criteria are those with no sites of lesion ≥ 7 cm and less than three sites of 3-7 cm lesions [24]. In patients without immediate treatment need, they should undergo periodic assessment and start treatment whenever necessary. Therapy should be given when the patient shows signs of lymphoma progression, such as newly enlarged lymph nodes, bone or other organ involvement, or reduced blood cell formation [21,24].

Most lymphoma cases present with clinical manifestations mimic other salivary gland epithelial neoplasms. A pre-operative fine-needle aspiration cannot provide a definitive diagnosis. Hence, sometimes the lymphomas of the salivary gland are treated surgically. With surgery, a definite diagnosis and even a specific subtype of malignant lymphoma can be attained.

4. CONCLUSION

Clinicians should be acquainted with the potential of lymphoma in patients with benign submandibular gland lesions. Therefore, a thorough pre-operative assessment should be carried to avoid unnecessary radical operations and hence treatment delays. In addition, recognizing the differences between submandibular NHL and salivary epithelial tumors (benign or malignant) is fundamental because the management of these tumors is different.

ETHICAL DECLARATION

Authors declared that the patient was consented about publishing his case on the scientific journal.

REFERENCES

[1] Iversen L, Eriksen PRG, Andreasen S, Clasen-Linde E, Homøe P, Wessel I, et al. Lymphoma of the sublingual gland: glinical, morphological, histopathological, and genetic characterization. Front. Surg. 2020; 7:581105. doi: 10.3389/fsurg.2020.581105.

[2] Binayke RS, Deshpande KA. Diffuse large b cell lymphoma of submandibular gland in a seropositive case – a rare presentation. Int J Res Med Sci. 2017; 5: 2257-9.

[3] Jamal, B. Treatment of parotid non-Hodgkin's lymphoma: a meta-analysis. Journal of Global Oncology. 2017; 1-6. DOI: 1 0.1200/JGO.17.00071

[4] Gupta D, Gahlot GPS, Rana V, Jagani R, Swarup D. Primary aggressive non-Hodgkin's lymphoma of the parotid gland in a young individual: a case report. International Journal of Case Reports and Images. 2014; 5(5): 377–81.

[5] Sen R, Srivastava D, Agarwal M, Yadav H, Bhargava S, Jahan A. Primary salivary gland lymphomas: a case series. Clin Cancer Investig J. 2016; 5: 11-4.
[6] Eltayeb AS, Alfadul AA, Agaimy SA, Suleiman AM. Diffuse swelling of salivary and lacrimal glands as a first and only manifestation of non-hodgkin b cell lymphoma: a case report. Ann. Int. Med. Den. Res. 2017; 3(1): DE01-4.
[7] Yaprak N, Temel IC, Derin AT, Güney K. Diagnosis and treatment of malignant lymphomas of parotid gland. Kulak Burun Bogaz Ihtis Derg. 2015; 25(6): 346-49.
[8] Zhang XY, Wang ZM. Relevance on the diagnosis of malignant lymphoma of the salivary gland. World J Clin Cases 2020; 8(13): 2717-2726.
[9] Utama MA, Kentjono WA. (2021). Non-Hodgkin's's lymphoma in the parotid gland similar to benign lymphoepithelial lesion: a case indonesian male. Indian Journal of Forensic Medicine & Toxicology, 2021; 15(1). 1334-39.
[10] Movahed R, Weiss A, Velez I, Dym H. Submandibular gland malt lymphoma associated with sjögren's syndrome: case report. J Oral Maxillofac Surg. 2011; 69: 2924-29.DOI: 10.1016/j.joms.2011.02.033.
[11] Chhabra1 S, Bhutani N, Kumar M, Yadav S, Sen R. Primary non-Hodgkin'ss lymphoma of the parotid gland: a common entity at an uncommon location. Acta Scientific Cancer Biology. 2019; 3(1): 17-21.
[12] Fatima S, Badri RN, Siddiqui WA, Alshehri A. Primary salivary gland lymphomas: a case series. Libyan J Med Sci. 2020; 4: 192-5.
[13] Rzepakowska A, Zwierzyńska K, Osuch-Wójcikiewicz E, Niemczyk K. Lymphoid tissue neoplasms in the neck region – epidemiological and clinical analysis over 15 years. Otolaryngol Pol. 2017; 71 (3): 1-9.
[14] Kaseb H, Ali MA, Koshy NV. Follicular lymphoma. [Updated 2021 Jul 2]. In: StatPearls [Internet]. Treasure Island (FL): StatPearls Publishing; 2021 Jan-. Available from: https://www.ncbi.nlm.nih.gov/books/NBK538206/.
[15] Thandra KC, Barsouk A, Saginala K, Padala SA, Barsouk A, Rawla P. Epidemiology of non-Hodgkin's's lymphoma. Med Sci (Basel). 2021 Jan 30;9(1):5. Available from DOI: 10.3390/medsci9010005. PMID: 33573146; PMCID: PMC7930980.
[16] Storck K, Brandstetter M, Keller U, Knopf A. Clinical presentation and characteristics of lymphoma in the head and neck region. Head & Face Medicine. 2019. 15:1-8.
[17] Gorodetskiy VR, Probatova NA, Kondratieva TT. Peripheral t-cell lymphoma of the submandibular salivary gland as an unusual manifestation of richter's syndrome: a case report and literature review. Case Reports in Hematology. 2017; 1-8. doi:10.1155/2017/126236.
[18] Singh R, Shaik S, Negi BS, Rajguru JP, Patil PB, Parihar AS, et al. Non-Hodgkin's's lymphoma: A review. J Family Med Prim Care 2020; 9:1834-40.
[19] Lee HG, Lee JY, Song JM. Malignant lymphoma on parotid gland: a clinical case. J Korean Assoc Oral Maxillofac Surg. 2017; 43: 138-43.
[20] Ninkovic S, Lambert J. Non-Hodgkin's lymphoma. Medicine. 2017; 45(5), 297-305.
[21] National Comprehensive Cancer Network. Follicular lymphoma (version 5.2021). 2021. Retrieved from https://www.nccn.org/professionals/physician_gls/pdf/b-cell.pdf
[22] Magnoli F, Tibiletti MG and Uccella S. Unraveling tumor heterogeneity in an apparently monolithic disease: bcl2 and other players in the genetic landscape of nodal follicular lymphoma. Front. 2019. Med. 6:44. doi: 10.3389/fmed.2019.00044
[23] Karmali R, Kimby E, Ghielmini M, Flinn, IW, Gordon, LI & Zucca, E. Rituximab: a benchmark in the development of chemotherapy-free treatment strategies for follicular lymphomas. Annals of Oncology 2018 29: 332–340, doi:10.1093/annonc/mdx768.
[24] Freedman A, Jacobsen E. Follicular lymphoma: 2020 update on diagnosis and management. Am J Hematol. 2020; 95:316–327. Available from: https://doi.org/10.1002/ajh.25696