Placenta Previa Accreta: A Case Report on Management of Elective Cesarean Delivery at Tertiary Hospital in West Nusa Tenggara

Ainun Karima[1*], Punarbawa, G.M[2], Muhammad Rizkinov Jumsa[3], Suwana. F.P.[1]

[1] *Apprentice doctor Department of Obstetrics and Gynecology West Nusa Tenggara Hospital*
[2] *Department of Obstetrics and Gynecology West Nusa Tenggara Hospital*
[3] *Department of Obstetrics and Gynecology University of Mataram*
[*]*Corresponding author. Email: ainkarimaa@gmail.com*

ABSTRACT
The Incidence and prevalence of placenta accreta and placenta previa has increased due to the increasing numbers of cesarean deliveries. Placenta accreta is one of the most serious complications of pregnancy and is often associated with placenta previa and severe obstetric hemorrhage and one of an important cause of maternal-fetal-neonatal morbidity and mortality. We report the case of a 32-year-old woman who diagnosed with gravida 4 para 2 with two times previous cesarean sections, 1 time abortion, and history of adhesion during her second cesarean section. The diagnosis by ultrasound and followed by cystoscopy examination showed invasion of placental blood vessels to detrusor muscle and submucous of urinary bladder. The decision for elective cesarean section was made and delivery time was at 34+3 weeks of gestation. A 2500g male baby has been delivered, placenta was not removed due to massive bleeding that occurred during the operation and an urgent decision for supra-cervical hysterectomy was taken. Patient admitted to intensive care unit due to severe blood loss during operation and the patient was discharged on the sixth day of postoperative treatment. Pathologies that occur in placental implantation such as placenta previa and placenta accreta are often associated with high maternal-fetal-neonatal morbidity and mortality. Cesarean section with hysterectomy is usually performed between 34-36 weeks of gestation before the time of delivery to await sufficient surfactant in the fetal lungs and limit the possibility of massive bleeding.

Keywords: *Placenta, Previa, Accreta, Cesarean, Hysterectomy, Delivery.*

1. INTRODUCTION

Placenta accreta spectrum is an abnormality of trophoblast invasion in myometrium of pregnant woman which is divided into three levels; placenta accreta, increta, and percreta based on the depth of invasion of part or all of the placenta into the myometrium of pregnant women [1,2]. Placenta accreta occurs when the villi attached to the surface of the myometrium but do not penetrate the myometrium, placenta increta occurs when the villi attach deeper and penetrate into the myometrium to the serosa, and placenta percreta occurs when the villi penetrate the myometrium across the serosa and may attach to other organs such as the bladder [3,4].

The Incidence and prevalence of placenta accreta and placenta previa has increased due to the increasing numbers of cesarean deliveries. Placenta accreta is one of the most serious complications of pregnancy and is often associated with placenta previa and severe obstetric hemorrhage and one of an important cause of maternal-fetal-neonatal morbidity and mortality [2]

The cause of placenta accreta is the presence of a defect in the uterine wall causing failure of normal decidualization at the site of the uterine scar leading to abnormalities in trophoblastic infiltration. The main risk of plasenta acreta spectrum is caused by previous cesarean delivery combined with placenta previa [4,5]. A Prospective observational cohort study of 723 women with placenta previa by Robert M Silver et al in US resulting the risk for placenta accreta was 3%, 11%, 40%, 61%, and 67% for first, second, third, fourth, and fifth or more repeat cesarean deliveries, respectively [6]. Placenta accreta usually necessitating hysterectomy due to it's massive bleeding [7].

Maternal and fetal-neonatal outcomes are improved when the right examination and diagnosis of placenta acreta is made before the time of delivery and the woman is managed by a multidisciplinary team with expertise in the condition [1,5].

2. CASE REPORT

A 32-year-old woman diagnosed with gravida 4 para 2 with no concomitant disease had two times previous cesarean sections, 1 time abortion, and history of adhesion during second cesarean section came to obstetric and gynecologic outpatient clinic of West Nusa Tenggara General Hospital on April 19, 2021, refered from Dompu Hospital as the case of placenta accreta was suspected by her last ultrasonography examination on April 12, 2021. She was made a routine ultrasonography examination during 1st and 2nd trimester of pregnancy but the on the ultrasound examination did not show any abnormality of placenta. On abdominal ultrasound examination in West Nusa Tenggara General hospital showed a fetus with appropriate biometric parameters and clear and sufficient amniotic fluid. On doppler images showed of placenta previa accreta with invasion of bridging vessels to urinary vesica (Figure-1). The diagnosis by ultrasound and followed by cystoscopy examination showed invasion of placental blood vessels to detrusor muscle and submucous of urinary bladder (Figure-2). The decision for elective cesarean section was made at 34+3 weeks of gestation. Patient was told about potential of obstetric complication. On May 08, 2021 cesarean section performed with general anesthesia, at 10.10 a healthy male baby weighing 2500g was delivered. The operation lasted about 2 hours, patient had severe blood loss due to massive bleeding during surgery and decision of supra-cervical hysterectomy was taken. The patient lost about 5000 ml of blood during operation and then developed severe hemodynamic instability with a 30% - 40% reduction in systolic blood pressure, then the transfusion protocol was immediately started with the intraoperative administration of 4500 ml of PRC. After surgery the patient was admitted to the intensive care unit due to severe blood loss during the operation and the patient was discharged on the sixth day of postoperative care.

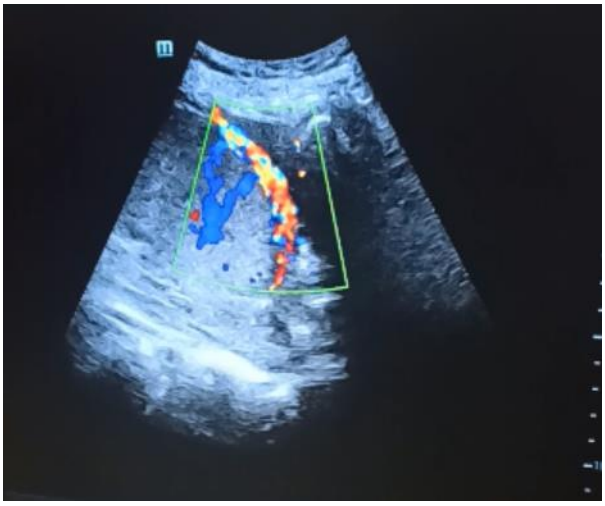

Figure 1 Ultrasonographic

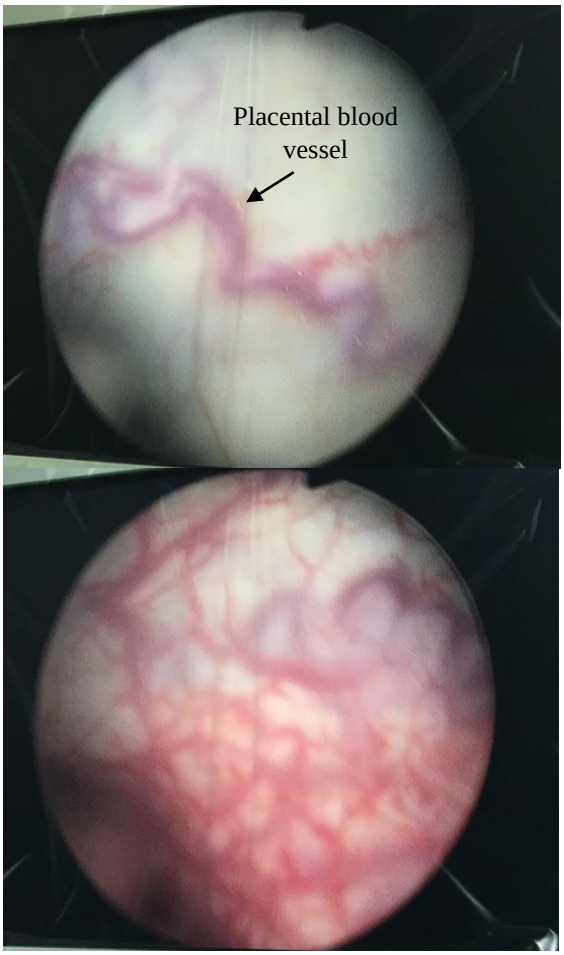

Figure 2 Cystoscopy

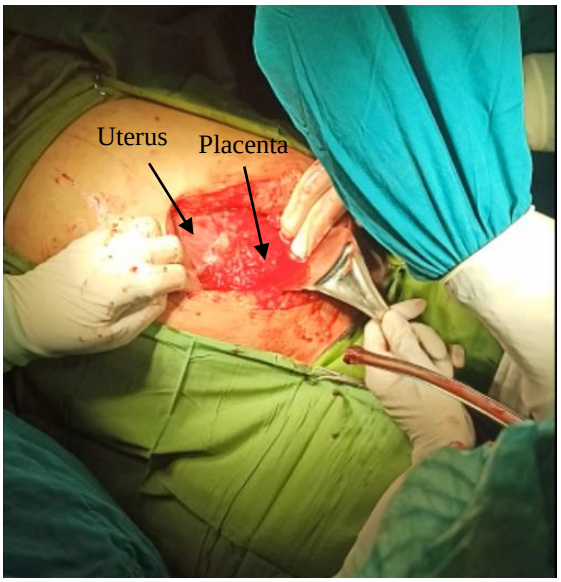

Figure 3 Placenta attach to lower uterus segment

3. DISCUSSION

The incidence of abnormal placenta invasion has increased in the last 30 year and reported to occur in 2–90 per 10.000 births due to increasing rates of cesarean section [2]. The main risk factors of placenta acreta are placenta previa and a history of previous cesarean section or a combination of both [1,3]. Antenatal diagnosis in cases of placenta accreta is very important because it will optimize treatment management and patient outcomes [1,3,5].

Ultrasonography is the primary antenatal obstetric diagnosis. Accurate diagnosis of placenta accreta has shown to improve maternal outcomes and allows clinicians to conduct appropriate risk assessment and management and planned delivery to a tertiary referral center with an experienced multidisciplinary team [1,5,6].

In our case, the patient was diagnosed with placenta previa accreta with a history of two previous cesarean section, one time abortion, and history of adhesion during second cesarean section. As discussed in the theory regarding placenta accreta, there is an increase in the incidence of placenta accreta in patients with placenta previa by 3% of women who have had one previous cesarean section, increasing to 11% after undergoing 2 cesarean sections, and to 40% after 3 procedures [6]. placenta previa also one of the most common risk factor in cases of placenta accreta [1,3,5]. The patient also has a history of abortion and curettage which is also a risk factor for placenta accreta [6,8,9].

Patient was evaluated by obstetrician gynecologists with experience and expertise in the diagnosis of placenta accreta spectrum by doppler sonography and cystoscopy. From Ultrasound examination found sufficient amnion fluid, placenta is on inferior uterus segment with retroplacental clear zone, lacunae grade 3, and bridging vessels invaded to the urinary vesica. This is as explained in theory that ultrasound is said to be the main modality for antenatal diagnosis in cases of placenta accrete as explain in obstetric case sonsensus the American Collage of Obstetrician and Gynecologist, ultrasonographic features of placenta accreta with placenta previa is found in 80% of cases of placenta accreta, multiple vascular lacunae, loss of the normal hypoechoic zone between placenta and myometrium and decreased retroplacental myometrial thickness (less than 1 mm), and placental appearance into myometrium, serosa, or bladder [1,5]. On cystoscopy, the results were sufficient urinary bladder capacity with hyperemic urinary bladder mucosa with detritus and placental blood vessels appeared to invade the urinary bladder mucosa with a diameter of 1.5 cm – 2 cm.

The operative management in the form of cesarean section and supracervical hysterectomy due to massive bleeding in patients was carried out on May 8, 2021 which 34+3 weeks of gestation at the Central Surgical Installation of the West Nusa Tenggara General Hospital. The decision on the timing of delivery needs to consider the risk factors and benefits for the mother and the fetus or neonate [1,10]. 34-36 weeks of gestation is an optimal time delivery of most large hospital centers to handle neonatal complications as surfactant production has sufficient [1,10,11]. The operative procedure and anesthetic action performed on this patient were general anesthesia with endotracheal intubation. The operation process is led by the main operator in this operation, namely an obstetrician consultant urogenital consultant with a team consisting of an obstetricians and gynecologist, anesthesiologist, a pediatrician, and a cardiovascular thoracic surgeon. Optimal management approach for accretas patient recommended by Society for Maternal–Fetal Medicine and the American College of Obstetricians and Gynecologists with comprehensive multidisciplinary care team, managing high level postpartum hemorrhage, and access to a blood bank for transfusion protocols [1].

4. CONCLUSION

Pathology of placental implantation is associated with high maternal-fetal-neonatal morbidity and mortality. Proper antenatal diagnosis can provide optimal outcomes for the mother, and caesarean section combined with hysterectomy to limit the amount of bleeding is recommended due to removal of the placenta is associated with with significant hemorrhage and the procedure is usually performed between 34-36 weeks of gestation taking into account both maternal and fetal outcomes [1,10,11].

In addition to caesarean section with hysterectomy, other conservative methods to maintain fertility can also be applied, these methods include leaving the placenta

in situ. however, leaving the placenta and the use of methotrexate also carries serious risks, such as late postpartum hemorrhage, infection, and pulmonary embolism that can endanger the life of the mother.[1].

From this case, we learn that there are still many things we need to know both about the pathology of placental implantation and how to prevent it so that the possible risk of massive bleeding can be limited and prevented.

AUTHORS' CONTRIBUTIONS

Karima and Suwana were responsible for the concept, Karima wrote the paper, and the manuscript was reviewed by Punarbawa and Jumsa. Operative was done by Punarbawa. All authors approved the final version.

ACKNOWLEDGMENTS

We would like to acknowledge dr Sanoko as the first attending on our case who revered the patient to our care and for the reviewer of this article.

REFERENCES

[1] American College of Obstetricians and Gynecologist. Placenta Accreta Spektrum. The American College of Obstetricians and Gynecologist. Society for Maternal Fetal Medicine. 2012;132(6):259-268

[2] Meriem NADI, Placenta accreta: Case report presenting obstetric emergency. World Congress on Gynecology and Obstetrics. 2020;6(5):17-19

[3] Cunningham, F. Gary,, Kenneth J. Leveno, Steven L. Bloom, Catherine Y. Spong, Jodi S. Dashe, Barbara L. Hoffman, Brian M. Casey, and Jeanne S. Sheffield. Williams Obstetrics. 25th edition. New York: McGraw-Hill Education, 2018.

[4] Jauniaux E, Ayres-de-Campos A, Langhoff-Ross H, Fox KA, Collins S. FIGO Placenta Accreta Diagnosis and Management Expert Consensus Panel : FIGO Classification for The Clinical Diagnosis of Placenta Accreta Spectrum Disorder. International Journal of Gynecology & Obstetrics. 2019; 146: 20-24. DOI : https://doi.org/10.1002/ijgo.12407

[5] Morlando M, Collins S. Placenta Accreta Spectrum Disorders: Challenges, Risks, and Management Strategies. International Journal of Women's Health 2020;12: 1033–1045. DOI : https://doi.org/10.2147/IJWH.S224191

[6] Silver RM, Landon MB, Rouse DJ, et al. Maternal morbidity associated with multiple repeat cesarean deliveries. Obstet Gynecol. 2006;107(6):1226–1232. DOI: https://doi.org/10.1097/01.AOG.0000219750.79480.84

[7] Canonico, S., Arduini, M, Epicoco, G et.all. Placenta Previa Percreta: A Case Report of Successful Management via Conservative Surgery. Case Reports in Obstetrics and Gynecology. Article ID 702067, 3 pages. 2013 DOI: https://doi.org/10.1155/2013/702067

[8] Jauniaux E & Collins, Sally & Burton, Graham. The Placenta Accreta Spectrum: Pathophysiology and Evidence-based Anatomy for Prenatal Ultrasound Imaging. American journal of obstetrics and gynecology. 2018;218(1):75-87. DOI: https://doi.org/10.1016/j.ajog.2017.05.067

[9] Mascio, D.D., Calì, G., and D'Antonio, F. Updates on The Management of Placenta Accreta Spectrum. Minerva Ginecologica. 2019;71(2): 113-120. DOI: https://doi.org/10.23736/S0026-4784.18.04333-2

[10] Geldarina, E., Ervere, I., Lapsane, E., Vasjutenko, M. Case Report: Management of Elective Cesarean Delivery in the Presence of Placenta Previa and Placenta Increta. Obstet Gynecol Int J. 2017;7(4): 00255. DOI: https://doi.org/10.15406/ogij.2017.07.00255

[11] Paul O. Nkadi, M.D.,1 T. Allen Merritt, M.D.,2 and De-Ann M. Pillers, M.D., Ph.D. An Overview of Pulmonary Surfactant in the Neonate: Genetics, Metabolism, and the Role of Surfactant in Health and Disease. Mol Genet Metab. 2009;97(2): 95–101. DOI: https://doi.org/10.1016/j.ymgme.2009.01.015.