Voice Improvement After Thyroid Surgery

Edo Wira Candra*

Department of Otorhinolaryngology – Head & Neck Oncology Surgery, EMC Sentul Hospital. Bogor, West Java, Indonesia.
**Corresponding author. Email: dr.edo.candra@gmail.com*

ABSTRACT
Patients with enlarged thyroid gland (goiter) that cause paralysis of recurrent laryngeal nerve (RLN) or hoarseness usually have associated with thyroid malignancy. Malignancy can be directly or indirectly related to RLN. Cases of vocal cord paralysis associated with benign thyroid disease or goitre are rare. As an objective, we present a case of a woman with hoarseness who is known to have left vocal cord paralysis which is suspected to be closely related to her thyroid disease (adenomatous goiter). As a method, this patient underwent a thyroid procedure (left isthmolobectomy) to see if her hoarse voice could decrease or disappear. As a result, after the thyroid procedure, there was improvement or disappearance of the hoarse voice. It is strongly suspected that the thyroid lesion suppressed the RLN resulting in impaired vocal cord movement or paralysis and causing hoarseness. In conclusion, thyroid procedure can be recommended to treat hoarse voice which is influenced by disturbance of vocal cord movement due to compression of thyroid lesion to RLN.

Keywords: *Hoarseness, Recurrent Laryngeal Nerve, Thyroidectomy, vocal cord paralysis*

1. INTRODUCTION

A goiter, also called struma, is a swelling in the neck due to enlargement of the thyroid gland. The goiter can be in the form of impaired function or changes in the composition of the gland and its morphology. The enlargement of the thyroid gland can affect the surrounding organs. The goiter may point inward, pushing against the trachea, esophagus and vocal cords. This will lead to difficulty of breathing, dysphagia or hoarseness. If the enlargement comes out it will give the shape of a large neck that can be asymmetrical or not, rarely accompanied by difficulty of breathing and dysphagia [1,2].

Goiter occurs due to lack of iodine which can inhibit the formation of thyroid hormone by the thyroid gland. In turn, it will inhibit the formation of TSH. The low level of TSH then causes the thyroid cells to secrete large amounts of thyroglobulin (colloid) into the follicle, and the gland grows larger and larger. As a result of iodine deficiency, there is no increase in the formation of T4 and T3, the size of the follicle becomes larger and the thyroid gland can gain weight of about 300-500 grams. In addition, goitre can be caused by congenital metabolic disorders that inhibit thyroid hormone synthesis, inhibition of hormone synthesis by chemicals (goitrogenic agents), inflammatory processes or autoimmune disorders such as Graves' disease [1,2].

Thyroid enlargement associated with or presenting with vocal cord palsy heightens the suspicion of thyroid malignancy. However, cases of vocal cord palsy in the setting of benign thyroid disease, though rare has been reported in literature. Various mechanisms have been suggested for the vocal cord palsy associated with benign goiter. These include compression (of the RLN and/or its blood supply), stretching of the RLN (by the large goiter or by the retrosternal component), inflammation or edema of RLN (as in thyroiditis).

Patients with large, obstructive, and substernal non-toxic MNGs or those with continued growth are best managed with surgery [3,4]. In this report, author would like to report the case of voice disorder in patient with goiter.

2. CASE REPORT

A 48-year-old woman with a voice that often turns hoarse since the last 4 years. Hoarseness has been reported to have worsened in the past 5 months. Complaints of shortness of breath, weight loss, and coughing up blood were denied. In the last 3 years the patient also felt that there was a slight enlargement in the front of the neck that was palpable but not very visible. The lump is painless. The patient also admitted that he often complained of cough, phlegm, especially in the morning and had a history of gastric disease. The patient had several times been treated with suspicion of chronic strep throat due to gastric acid irritation, received treatment and there seemed to be improvement in his voice but could not reach the maximum condition.

The patient never complained of frequent heart palpitations, bulging eyes, could not stand in hot weather, frequent sweating, muscle weakness, weight loss accompanied by decreased appetite, or shaking hands. The patient had never received radiation treatment to the head and neck area previously.

On physical examination, general condition is good and vital sign within normal limit. General status: right and left eyes do not appear exophthalmos, upper extremities: tremor -/-. Ear examination: the right and left external acoustic canals were spacious, the right and left tympanic membranes were intact. Nasal examination: the right and left nasal cavities looked spacious, pink mucosa, no secretions, no septal deviation. Throat examination: hyperemic posterior pharyngeal mucosa, granular (+), quiet T1/T1 tonsils. Examination of the neck: palpable solid, smooth, smooth surface in the left thyroid region, approximately 2.5 cm in diameter, painless and the lump moves during swallowing. The patient did not find any enlargement of the cervical lymph nodes on palpation.

On indirect laryngoscopy examination, the left vocal cord movement was slightly weak/slow during adduction and there was no mass in the larynx (Figure 1). Other findings were within normal limits.

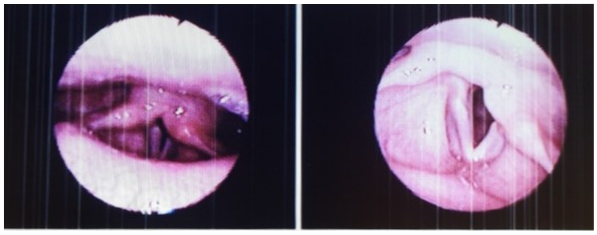

Figure 1 Preoperative indirect laryngoscopy shows weakness of left vocal cord mobility

Fine needle aspiration was carried out with cytology results showing benign thyroid nodular lesions with degenerative cysts. No malignant cells were found.

On a CT-scan of the neck with contrast there was enlargement of the right and left perijugular lymph nodes with the largest diameter of 14mm, no central necrotic appearance (Figure 2). It was seen that the right and left thyroid parenchyma were less homogeneous with the left thyroid thickened and there was a solid nodule in the center measuring 2.3 x 2.2 cm.

A chest X-ray showed cardiomegaly (Left Ventricle), no significant pulmonary infiltrate was seen and a left pleural effusion was suspected (minimum).

Examination of thyroid gland function was found within normal limits with TSH levels: 1.360 uIU/mL, fT3 2.60 pg/mL and FT4: 1.08 ng/dL. Other laboratory tests included complete blood count, hemostasis function, liver and kidney function within normal limits.

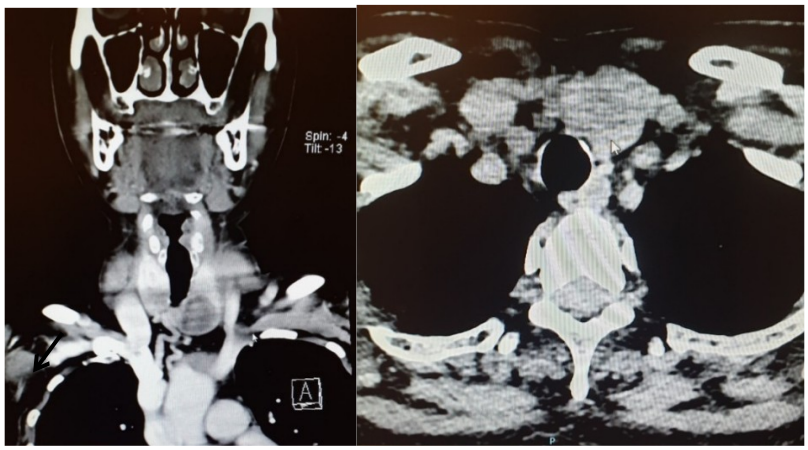

Figure 2 CT-Scan with contrast (arrow indicated the mass)

Based on the history, physical examination and supporting examinations, the patient's then diagnosis as non-Toxic Struma Nodosa with Voice disorder et causa paralysis of left vocal cord.

The patient then planned for surgery under general anesthesia. A left lobectomy was performed, with the findings of a solid, spongy mass of the left thyroid lobe measuring 4.5 cm x 3.5 cm x 3 cm (Figure 3). Then we put a drain through the surgical wound. Postoperatively, the patient received Ceftriaxon 1 x 2 grams intravenously, tranexamic acid 3 x 500 mg intravenously and ketorolac 2 x 30mg intravenously. Methylprednisolone 3x 62.5mg intravenously, and Pantoprazole 1x40mg intravenously.

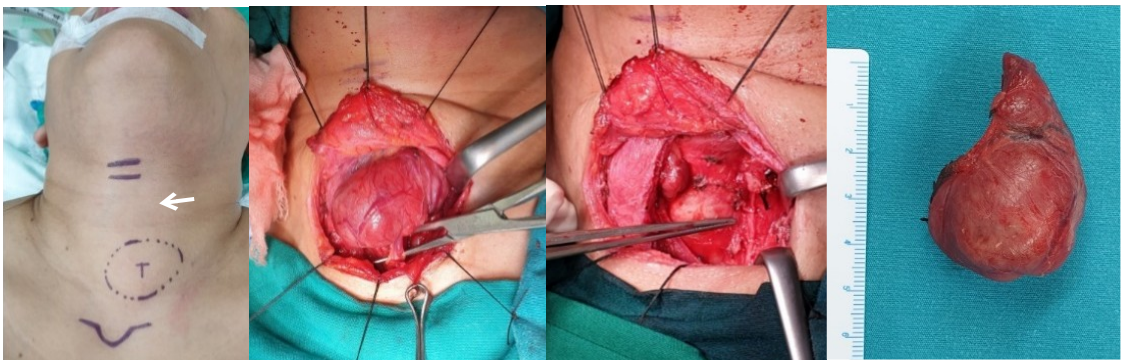

Figure 3 Left lobectomy. White arrows indicate left recurrent laryngeal nerve.

On the second day after surgery, the condition of the surgical wound was well maintained, hecting was good, pus was not visible, drain production was ± 10 cc of serosanguin and there was an improvement in the sound. On third day, drain production was ± 5 cc. On fourth day found minimum drain production. Then the drain was removed and the patient was allowed to go home with oral medicine.

Histological impressions in accordance with Adenomatous Struma. No signs of malignancy were visible on the mass.

Tenth days after surgery, the patient returned to the hospital for evaluation. The surgical wound was found dry, there was no pus, there was no hoarseness in the voice and then a laryngoscopy evaluation was carried out, the left vocal folds were better in the adduction process (Figure 4).

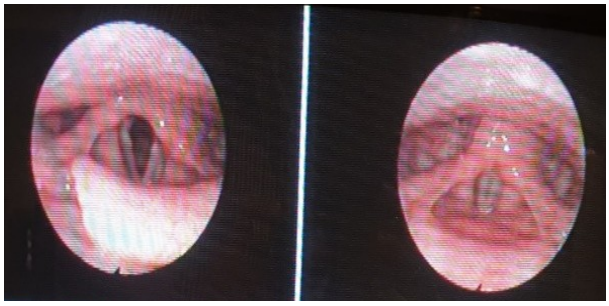

Figure 4 Evaluation post surgery found better left vocal cord mobilization.

3. DISCUSSION

Thyroid enlargement associated with vocal cord paralysis raises the suspicion of a thyroid malignancy. However, vocal cord paralysis can also be caused by benign thyroid disease. The incidence of vocal cord paralysis associated with benign thyroid enlargement is uncertain because as many as 30 to 50% of patients with unilateral RLN palsy may be asymptomatic, and thus may not seek medical attention [4,5].

Rowe-Jones et al [6] noted that the incidence of vocal cord paralysis before surgery for benign thyroid tumors was 0.96% (22 cases out of 2321 benign thyroid surgeries) experienced significant improvement after undergoing thyroid surgery. Reuger et al [7] reported a similar 0.7% of correlated benign thyroid tumors cases with improvement of vocal cord paralysis after undergoing thyroid surgery procedure. Deependra et al [8] reported a similar report of about 0.7% of benign thyroid cases associated with vocal cord paralysis who had voice improvement after thyroid surgery procedure.

The intraoperative finding of the left RLN was identified with a very thin structure. This is suspected to occur due to the left RLN being stretched by the thyroid mass for a long period. Deepandra et al [8] in their research revealed various mechanisms that were thought to cause vocal cord paralysis in benign thyroid enlargement. One of the mechanism was direct compression to the RLN or its blood supply. It can also be due to stretching by a large thyroid mass or by a retrosternal component. The other mechanism was caused by inflammation of the NLR such as in cases of thyroiditis [8].

Evaluation has been carried out on patients 5 days and 10 days after lobectomy surgery, it was found that there was an improvement in the voice and mobility of the left vocal cord. Similarly, in the study of Rowe-Jones et al [6] who recorded a postoperative voice recovery of 89% of patients. The other study reported the improvement in 2 weeks until 1 year [9].

4. CONCLUSION

A case of a 48-year-old woman has been reported with voice disorder due to left vocal cord paralysis and left thyroid tissue enlargement in the last 4 years. Left lobectomy was performed and postoperative monitoring showed improvement in voice quality. Indirect laryngoscopy examination showed improvement in left vocal cord mobility/adduction. It is strongly suspected that the cause of left NLR paresis is due to compression or stretching of benign thyroid tissue (adenomatous goiter). The gentle surgery to remove the goiter may led to decompression of RLN and finally improve the voice quality.

CONCENT TO PUBLISH

I hereby declare that I have provided informed consent from the patient. She agree to published her case through a written manuscript as long as her identity remain kept confidentialy.

REFERENCES

[1] Moore, KL & Agur, AMR. Essential Clinical Anatomy, Wiliams and Wilkins, 1996. pp. 156-161.
[2] Guyton, A.C Hall, J.E, Textbook of medical physiology. W.B Saunders Company, Philadelpia, Pennsylvania. (1996) ed. 9, pp. 1311-1312.
[3] Castro Regina M. (Accessed : 25 february 2012), goiter-diagnostic and treatment consideration. Available at: http://www.google.com (last update : 2004).
[4] Cunning DS. Unilateral vocal cord paralysis. Ann Otol Rhinol Laryngol 1955;64:487-93.

[5] Huppler EG, Schmidt HW, Devine KD, Page RP. Ultimate outcome of patients with vocal cord paralysis of undetermined cause. Am Rev Tuberc Pulm Dis 1956;73:52-60.
[6] Rowe-Jones JM, Rosswick RP, Leighton SE. Benign thyroid disease and vocal cord palsy. Ann R Coll Surg Engl July 1993;75(4):241-44.
[7] Rueger RG. Benign disease of the thyroid gland and vocal cord paralysis. Laryngoscope 1974;84:897-907.
[8] Deependra NS, Agarwal A, Gupta S, Jain M. Benign Thyroid Disease causing RLN Palsy. World Journal of Endocrine Surgery, May-August 2011;3(2):65-68
[9] O'Duffy F, Timon C. Vocal fold paralysis in the presence of thyroid disease: management strategies. J Laryngol Otol. 2013;127(8):768-72. doi:http://dx.doi.org/10.1017/S0022215113001552.