Hemiglossectomy with Supraomohyoid Neck Dissection on T3N1M0 Tongue Cancer Patient

A Case Report

Karina Witary Ayu Siagian[1,2*], Benny Kurnia[1,2], and Fadhlia Fadhlia[1]

[1] *Otorhinolaryngology Head and Neck Surgery Department, Faculty of Medicine University of Syiah Kuala*
[2]*dr. Zainoel Abidin Hospital, Banda Aceh, Indonesia*
[*]*Corresponding author. Email: karinawitaryayu@gmail.com*

ABSTRACT
Hemiglossectomy, surgical removal of half of the tongue, is one of the procedures for tongue cancer management. Surgery followed with supraomohyoid neck dissection (SOHND) is suggested to treat regional metastasis. SOHND is a selective neck dissection indicated for patients with T2, T3 tongue cancer in which cervical lymph nodes are clinically negative (N0) or N1. A 62-year-old female with the main complaint of mass on the left part of the tongue that she experienced for the past six months. The history of betel fruit chewing was confirmed. Physical examination showed a mass on the two-third posterior left tongue with a size of 4x4cm, DOI 11 mm, and enlargement on left cervical lymph node 2x1x0.5cm, mobile and painless. The histopathology result of the biopsy revealed an invasive keratinising squamous cell carcinoma, and Oropharynx-CT Scan showed a heterogeneous mass enhancement with a size of lesion 1.0x2.4cm, irregular border, lesion seemed not extended to genioglossus muscle yet, enlargement of cervical lymph node 2.7 and 1.3cm, the density of bone was normal.Hemiglossectomy is the main treatment for T3N1M0 tongue cancer, and radiotherapy should be considered as adjuvant therapy for a better prognosis.

Keywords: *Tongue Cancer, Hemiglossectomy, Supraomohyoid Neck Dissection, SOHND*

1. INTRODUCTION

Tongue cancer is one of the malignancies in the oral cavity, which usually originates from the squamous cells on the tongue surface (squamous cell carcinoma) [1]. The most frequent intraoral malignancy in the head and neck is tongue Squamous cell carcinoma (SCC) [2], contributing to 90% of oral cavity neoplasms [3,4]. According to the World Health Organization, the incidence of tongue cancer in Indonesia was 1.5% in 2020, making it the 17th most frequent cancer in the country [5]. The prevalence of tongue cancer in dr. Zainoel Abidin Hospital, Aceh, Indonesia, between 2015 to 2020 was 57, in which 35 of them received chemotherapy and the other 22 underwent surgical procedures.

Most of the lesions are located at the 2/3 anterior of the tongue, usually on the lateral and upper side [12]. The commonly cited symptoms include leukoplakia, erythroplakia, and tongue ulcer. Patients also complain of localised pain, odynophagia, dysphagia, dysarthria, and weight loss. A mass on the neck is reported inpatient on which the cancer is likely to have been metastasis to the neck area [13]. In addition to physical examination, biopsy and contrast-enhanced computed tomography (CT) scan of the oropharynx are important supportive diagnostic tools to provide findings of size, location, and tumour extension as well as the radiologic appearance of the draining lymph nodes [13]. Biopsy and histopathology examinations are the gold standard of diagnosis for tongue cancers. [12]. According to the National Comprehensive Cancer Network (NCCN) 2021 guidelines, management of tongue cancer includes surgical procedures, radiation, and chemotherapy [14]. Surgical procedure was decided based on tumor size, location, involvement of lower jaw bone (mandibular), and metastasis occurrence [15]. Hemiglossectomy, a surgical removal of half of the tongue, is one of intraoral surgical procedures in tongue cancer management [16,17]. Neck dissection following glossectomy is always considered due to high occurance of cervical lymph node metastasis in tongue cancer [18]. Supraomohyoid neck dissection (SOHND) is one of the selective neck dissections used as a treatment for patients with tongue cancer [13]. SOHND is indicated for patients with large T2, T3, and T4 in whom the cervical lymph nodes enlargement are either clinically negative (N0) or single, discrete, and <3 cm (N1) [20].

Generally, tongue cancer prognosis is poor with less than 25% five-year survival rate [12]. Surgical procedures, along with adjuvant radiotherapy or chemotherapy could increase survival rate of patients with tongue cancer [21,22].

2. CASE REPORT

A 62-year-old female complaint of a mass on the 2/3 posterior left side of the tongue that she had experienced for the past six months. Initially, the patient had an ulcer (stomatitis) on her tongue's left side for 2 months. Solid food swallowing was normal, although she admitted of having swallowing pain and bad breath occasionally. She further complained of having a lump on her left neck that she had experienced for the last 2 months prior to the visit. In regards to medical history, the patient was diagnosed with hypertension but rarely takes her medicine. She does not smoke or drink alcohol, but she used to chew betel fruit for about seven years before quitting three years ago. Furthermore, she consumes salted and grilled fish frequently. No toothache, loss of appetite, or weight changes were noted.

General status was obtained moderate state, compos mentis awareness, cooperative and heart rate 80 times a minute, respiratory rate 20 times a minute, blood pressure 140/90 mmHg. Physical examination showed a symmetric face and skin colour appears to be normal. Localised status on oropharynx region showed a fixed pedunculated mass on the 2/3 posterior left tongue with the size about 4x4cm, with 11 mm depth of invasion (DOI), appeared to bleed easily. A stage III lymph node enlargement was found on the neck area. Lymph node size was 2x1x0.5 cm (width, length, depth), with smooth surface, mobile, with no tenderness and no trismus (Figure 1). The blood laboratory and chest x-rays showed a normal result.

On January 8th, 2021, a biopsy was performed on the patient to identify the suspected malignancy. The result histopathology before surgery revealed invasive moderately differentiated non - keratinising squamous cell carcinoma.

Figure 1. Clinical Appearance Of The Mass Observed During Intra-Oral Examination.

A contrast-enhanced Oropharynx CT-Scan (January 20th, 2021) showed a hypodense lesion, with partly unclear dan irregular border, sized 1.0x2.4 cm on the tongue that showed as a heterogeneous contrast – enhanced appearance. Multiple lymph nodes were observed at the left side of the neck, sized 2.7 and 1.3 cm, yet no signs of spread to M. Genioglossus was observed. Airways looked normal with normal caliber, and normal bone density, suggesting tongue cancer (Figure 2). USG showed no intraabdominal metastasis. Based on these, the patient was diagnosed with T3N1M0 tongue cancer and stage I hypertension, then prepared for the left hemiglossectomy procedure and supraomohyoid neck dissection (SOHND). The preparation was consulted to the Cardiology department for tolerate surgery with moderate tolerance, also consult to Anaesthesia department which the surgery will occurred under general anaesthesia with ASA II.

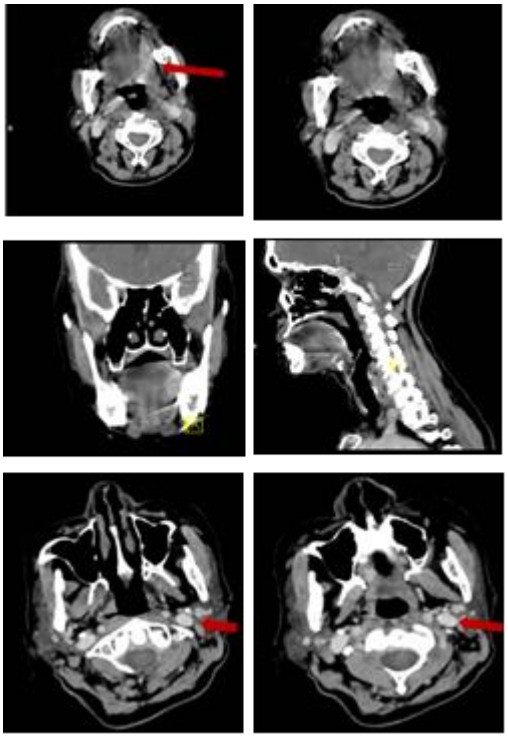

Figure 2 Contrast-Enhanced Oropharynx CT Scan Showed a Locoregional Lymphatic Spread to The Neck.

2.1 Left Hemiglossectomy Procedure

The procedure was done on February 9th, 2021. Tongue fixation was done using 1.0 silk thread to the drape on the the patient's right side. An ulcerative tumor was seen on the lateral-posterior left side of the tongue, with approximate size of 4x4 cm. A margin incision was marked, approximately 2 cm from the ulcer. Tumor excision was done from 2 cm of the anterior edge to the midline of the tongue using electric cautery. After ligation the lingual artery, the excision was continued to the posterior side, passed the terminalis line. Excision was then continued from the lateral anterior to the posterior until the anterior fold of the fossa tonsils. The tumor was removed and the bleeding was controlled. Specimens to ensure for free margin was taken from the four left areas: posterior midline, posterior lateral, first anterior midline, and second anterior midline. The wound was closed with two layers of suture using 3.0 polysorb thread (Figure 3).

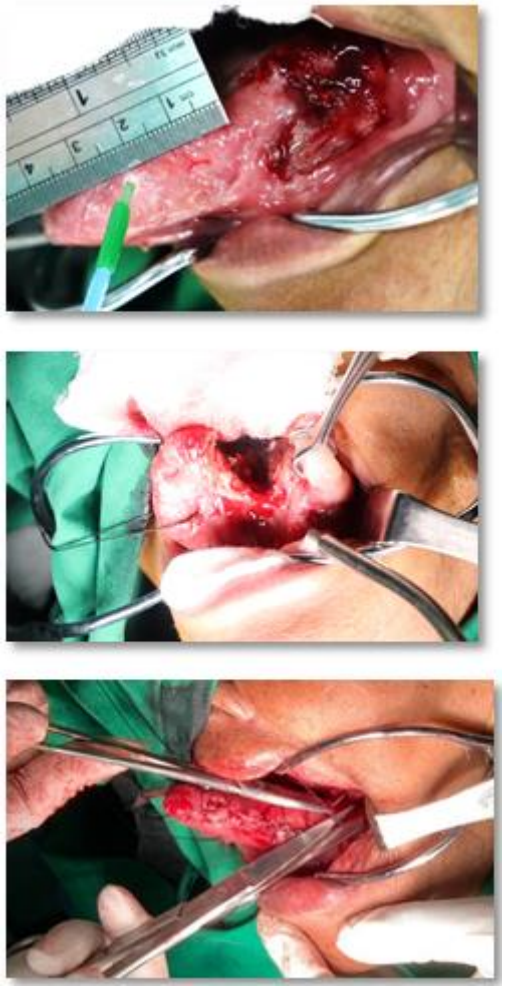

Figure 3 Hemiglossectomy Procedure.

2.2 Supraomohyoid Neck Dissection Procedure

A skin mark of surgical area was done as 5-7 cm incision 2-3 cm below angulus mandibula pararelly, following infiltration with 2 ampules of pehacaine was made into lower and upper sub-platysma flaps. The left submandibular gland was identified and freed until the digastricus muscle appeared and we started lymph node dissection of level IA and IB and continue to level IIA dan IIB as well as level III upper border of omohyoid muscle. A IIA level (1cm) of lymph node was identified and dissected, and continued to IIB level lymph node, in which spinal accessory nerve was identified and IIB level of lymph node was dissected from the internal jugular vein downwards until it conjoined with the level III lymph node (1.5x1 cm). Control of bleeding was done, and drain was inserted. The muscles then sutured up and the wound was closed. (Figure 4).

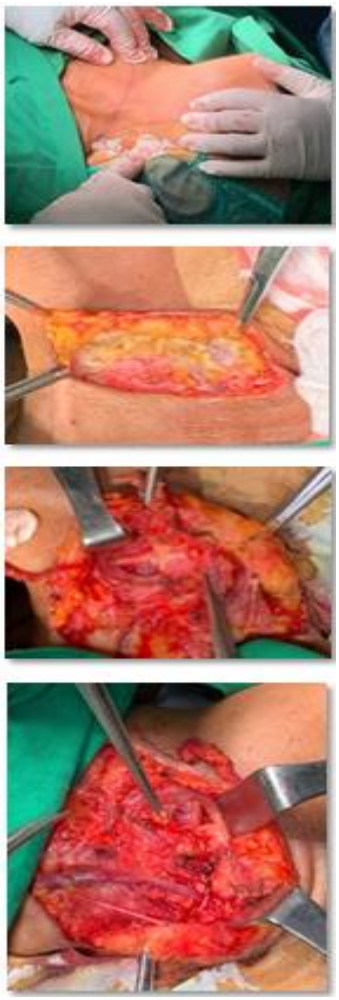

Figure 4 SOHND Procedure.

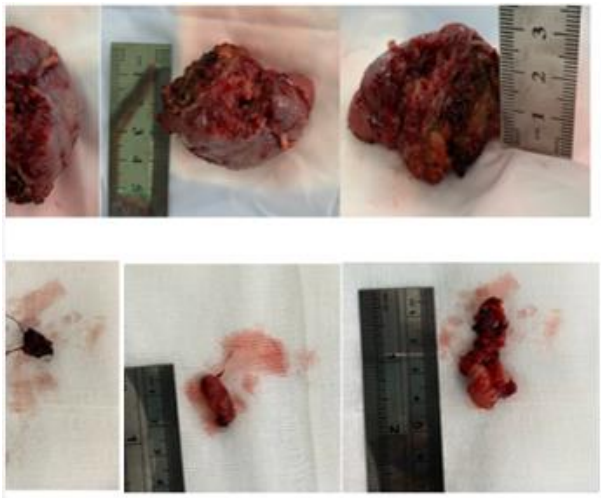

Figure 5 (A,B,C,D) Tumor Mass From Tongue; (E,F) Cervical Lymh Node

After surgery, the patient's condition was good, mobilisation of tongue was good, the wound was dry in the neck, and the patient went home on 3rd postoperative day. On 12th postoperative day, mobilisation of tongue was good, the wound was completely closed in the neck, there was no inflammation, postoperative histopathology showed Invasive keratinising squamous cell carcinoma.

Figure 6 Postoperative Follow-Up 12 Days After Surgery

3. DISCUSSION

This is a report of a 62-year-old female patient with a chief complaint of growing lump on the 2/3 posterior left side of the tongue, which she had experienced for the last 6 months. The patient was diagnosed with Stage III T3N1M0 tongue cancer and stage 1 hypertension.

The patient in this report was a female on her sixties, which pretty similar to the general epidemiologic characteristics. From the examination we found that the patient had a history of betel quid chewing for seven years before quitting three years prior to hospital visit. This might be the risk factor of tongue cancer in this patient, as suggested in previous studies [2,11]. Betel fruit chewing is a tradition in some Asian countries like India, Nepal, Pakistan, and Indonesia. Areca nut, wrapped in betel leaf were consumed with or without tobacco. Investigations showed that Areca nut has a carcinogenic and addictive effect, and is one of the risk factors of oral cavity malignancies [2,4,11].

Initially, the patient experienced an ulcer on her left tongue, which grew bigger within the last 2 months. A fixed pedunculated ulcer sized 4x4 cm, with 11 mm DOI, that appeared to be easily bleed, located at the 2/3 posterior left tongue and stage III lymph node enlargement sized 2x1x0.5 cm, with smooth surface, mobile, and no tenderness were noticed during intra-oral examination. This is in accordance to previous studies that mentioned most of the malignancies start with an ulcer. In general, ulcerative ulcers are the sign of advanced stage tongue cancers. Most of the lesions located at the 2/3 anterior of the tongue [12], however the lesion in this patient was located at the 2/3 posterior of the tongue. Generally, lesions located at the posterior of the tongue were associated with poorer prognosis as they are more progressive and easier to spread, thus more difficult to treat.

In this patient, we also found level III lymph node enlargement, indicated regional metastasis. According to the American Joint Committee on Cancer (AJCC)

staging, DOI >10 mm, with 4 cm surface area of the lesion are corresponding to T3 stage [23,25]. In accordance with the 2018 AJCC, history taking, physical examination, and contrast-enhanced oropharynx CT-scan in this patient lead to stage III T3N1M0.

A biopsy and histopathology exam done in this patient before surgery showed an invasive moderately differentiated non-keratinising squamous cell carcinoma, while post surgery histopathology exam suggested an invasive keratinising squamous cell carcinoma. Tongue biopsy has 93.53% specificity and 83.33% sensitivity, and showed a representative result for the removal of the whole lesion compared to other examinations such as cytology examination with fine needle aspiration (FNAB) [12,23,25], a condition where the malignancy has combined non-keratinising and keratinising appearance is called hybrid or SCC with non-keratinising maturation. Previous studies showed that such condition was associated with HPV infection.

In accordance with NCCN therapy guidelines, the patient underwent left hemiglossectomy and SOHND. Hemiglossectomy is a trans-oral surgical procedure in tongue cancer management, which is done by removing half of the tongue, indicated in massive lesion that infiltrates intrinsic and extrinsic muscles but is limited to ipsilateral of the tongue [16,17]. Beside complete removal of the cancer, a successful surgery results in improved ability to swallow food and restored speech. Compare to total glossectomy, hemiglossectomy causes less disability, results in better swallow function and restored speech [18].

Since the tongue has many lymphatic drainages, the rate of regional metastases of tongue cancer is high, especially to the nearby lymph nodes [18]. Approximately 40% of tongue cancer patients already have regional metastases when they first came to the hospital [26]. Therefore, neck dissection following glossectomy should always be considered [14].

According to the American Head and Neck Society, SOHND is one of the elective upper neck dissections to remove a group of lymph nodes staged I-III with sternocleidomastoid muscle, internal jugular vein, and spinal accessory nerve preservation in patients with N0 or N1 (with cancer spreading to one lymph node on the primary malignancy ipsilaterally, and the cancer found in the lymph node sized 3 cm or less) [19]. SOHND was done in this patient since a level III lymph node enlargement was found on the left neck, with no extra nodule expansion found. The enlargement of collar lymph node occurred due to metastasis from lymphatic drainage from mid-jugular, at the intersection of omohyoid and sternocleidomastoid muscles and the sternocleidomastoid muscle posterior border. Previous investigation suggested postoperative radiation therapy after SOHND can achieve better regional control than comprehensive neck dissection and postoperative radiation therapy [14].

The tongue cancer prognosis in general is poor, with the five-year survival rate is below 25%, where patients with 1/3 dorsum lesion had lower five-year survival rate [12]. Adjuvant radiation or chemotherapy following surgical procedure could improve disease prognosis and increase tongue cancer survival rate [21,22].

4. CONCLUSION

SCC of the tongue is the most frequent oral cavity malignancies. According NCCN, SOHND following hemiglossectomy procedure was done in this patient, who was diagnosed with Stage III T3N1M0 SCC and hypertension stage 1. For better prognosis and higher five-year survival rate, hemiglossectomy and SOHND in this patient should be followed with radiotherapy.

ETHICAL APPROVAL

The study is in compliance with the Declaration of Helinski.

CONSENT

Informed consent was obtained from the patient for publication of this case report.

REFERENCES

[1] PH. Montero, SG. Patel. Cancer of the oral cavity. Surg Oncol Clin N Am. 2015;24(3):491-508. https://doi.org/10.1016/j.soc.2015.03.006

[2] A. Credé, M. Locher, M. Bredell. Tongue cancer in young patients: case report of a 26-year-old patient. Head Neck Oncol. 2012;4:20. https://doi.org/10.1186/1758-3284-4-20

[3] KS. Ettinger, L. Ganry L, Fernandes RP. Oral Cavity Cancer. Oral Maxillofac Surg Clin North Am. 2019;31(1):13-29. https://doi.org/10.1016/j.coms.2018.08.002

[4] L. Kayal, S. Jayachandran, YH. Bhaskar. Squamous cell carcinoma of tongue: a case report and review of literature. Int J Cur Res Rev. 2016;8(9):64-67.

[5] F. Bray, J. Ferlay, I. Soerjomataram, RL. Siegel, LA. Torre, A. Jemal. Global cancer statistics 2018: GLOBOCAN estimates of incidence and mortality worldwide for 36 cancers in 185 countries. CA Cancer J Clin. 2018;68(6):394-424. https://doi.org/10.3322/caac.21492

[6] EM. Sturgis, Q. Wei, MR. Spitz. Descriptive epidemiology and risk factors for head and neck cancer. Semin Oncol. 2004;31(6):726-733. https://doi.org/10.1053/j.seminoncol.2004.09.013

[7] E. Leoncini, W. Ricciardi, G. Cadoni, et al. Adult height and head and neck cancer: a pooled analysis within the INHANCE Consortium. Eur J Epidemiol. 2014;29(1):35-48. https://doi.org/10.1007/s10654-013-9863-2

[8] MG. Kato, CH. Baek, P. Chaturvedi, et al. Update on oral and oropharyngeal cancer staging - International perspectives. World J Otorhinolaryngol Head Neck Surg. 2020;6(1):66-75. https://doi.org/10.1016/j.wjorl.2019.06.001

[9] CH. Shiboski, BL. Schmidt, RC. Jordan. Tongue and tonsil carcinoma: increasing trends in the U.S. population ages 20-44 years. Cancer. 2005;103(9):1843-1849. https://doi.org/10.1002/cncr.20998

[10] E. Soudry, M. Preis, R. Hod, et al. Squamous cell carcinoma of the oral tongue in patients younger than 30 years: clinicopathologic features and outcome. Clin Otolaryngol. 2010;35(4):307-312. https://doi.org/10.1111/j.1749-4486.2010.02164.x

[11] KK. Ang, J. Harris, R. Wheeler, et al. Human papillomavirus and survival of patients with oropharyngeal cancer. N Engl J Med. 2010;363(1):24-35. https://doi.org/10.1056/NEJMoa0912217

[12] J. Shah, S. Patel, B. Singh, R. Wong. Jatin Shah's Head and Neck Surgery and Oncology. 5th ed. Philadelphia: Elsevier; 2019.

[13] M. Gonzalez, A. Riera March. Tongue Cancer. In: StatPearls. Treasure Island (FL)2021.

[14] DG. Pfister, S. Spencer, D. Adelstein, et al. Head and Neck Cancers, Version 2.2020, NCCN Clinical Practice Guidelines in Oncology. J Natl Compr Canc Netw. 2020;18(7):873-898. https://doi.org/10.6004/jnccn.2020.0031

[15] A. Fauzi, A. Hardianto, R. Wariz. Hemiglosectomy with selective neck dissection in squamous cell carcinoma at the tongue. J Dentomaxillofac Sci. 2016;1(2):139-144. https://doi.org/10.15562/jdmfs.v1i2.13 https://doi.org/10.22208/jdmfs.1.2.2016.287-293

[16] M. Ansarin, R. Bruschini, V. Navach, et al. Classification of GLOSSECTOMIES: Proposal for tongue cancer resections. Head Neck. 2019;41(3):821-827. https://doi.org/10.1002/hed.25466

[17] G. Mannelli, F. Arcuri, T. Agostini, M. Innocenti, M. Raffaini, G. Spinelli. Classification of tongue cancer resection and treatment algorithm. J Surg Oncol. 2018;117(5):1092-1099. https://doi.org/10.1002/jso.24991

[18] JLM. Bigcas, OT. Okuyemi. Glossectomy. In: StatPearls. Treasure Island (FL) 2021.

[19] LP. Kowalski, A. Sanabria. Elective neck dissection in oral carcinoma: a critical review of the evidence. Acta Otorhinolaryngol Ital. 2007;27(3):113-117.

[20] JE. Medina, RM. Byers. Supraomohyoid neck dissection: rationale, indications, and surgical technique. Head Neck. 1989;11(2):111-122. https://doi.org/10.1002/hed.2880110203

[21] D. Pulte, H. Brenner. Changes in survival in head and neck cancers in the late 20th and early 21st century: a period analysis. Oncologist. 2010;15(9):994-1001. https://doi.org/10.1634/theoncologist.2009-0289

[22] K. Kirtane, CP. Rodriguez. Postoperative Combined Modality Treatment in High Risk Resected Locally Advanced Squamous Cell Carcinomas of the Head and Neck (HNSCC). Front Oncol. 2018;8:588-588. https://doi.org/10.3389/fonc.2018.00588

[23] BS. Tuli. Textbook of Ear, Nose, and Throat. India: Jaypee Brothers Medical Publishers; 2013. https://doi.org/10.5005/jp/books/12073

[24] UPG. Selvi, D. Kamatchi, R. Tharani, S. Anusuya. Demographic, Habits and Clinical Presentation of Oral Cancer in Trichy's Population. International Journal of Contemporary Medical Research. 2017;4(1):287-290.

[25] EA. Soepardi, N. Iskandar, J. Bashiruddin, RD. Restuti. Buku Ajar Ilmu Kesehatan: Telinga Hidung Tenggorok Kepala & Leher. Jakarta: BP FKUI; 2012.

[26] EN. Myers, BR. Gastman. Neck dissection: an operation in evolution: Hayes Martin lecture. Arch Otolaryngol Head Neck Surg. 2003;129(1):14-25. https://doi.org/10.1001/archotol.129.1.14

[27] VR. Kolli, RV. Datta, JB. Orner, WL. Hicks Jr, TR. Loree. The Role of Supraomohyoid Neck Dissection in Patients With Positive Nodes. Archives of Otolaryngology-Head & Neck Surgery. 2000;126(3):413-416 https://doi.org/10.1001/archotol.126.3.413