Mucormycosis in Healthy Young Man
A Case Report in Indonesia

Metta Octora[1,2,3*], Arthur Pohan Kawilarang[2,3], and Eddy Bagus Wasito[2,3]

[1]*Division of Microbiology, Faculty of Medicine, University of Mataram , Indonesia.*
[2]*Department of Microbiology, Faculty of Medicine, Airlangga University, Surabaya, Indonesia.*
[3]*Department of Clinical Microbiology of Dr. Soetomo Hospital, Indonesia.*
[*]*Corresponding author. Email: mettaoctora@unram.ac.id*

ABSTRACT
Mucormycosis is one of the most common invasive fungal infections. Unlike other filamentous fungi, Mucorales additionally may be a frequently lethal infection in immunocompetence patient. We describe a 22-year-old male patient that presented wound of right lateral eye and right face, as well as pain and pus discharge since 5 months ago and developed rapidly extensive necrosis of tumor. He had no particular pathological history and immunocompetent condition It was diagnosed suspected Actinomycosis with differential diagnosis of Nocardiosis and Actinomysetoma and given therapy of antibiotics. His conditions deteriorated. Microbiology examination was continued by fungal histopathology examination. We found mucomycosis infection description with Periodic Acid Schiff (PAS) stain. He was given amphotericin B therapy and his condition improved. Due to mucormycosis in immunocompetent patient was rare, the challenge of diagnosing rhinoorbitocerebral mucormycosis may result in many undiagnosed cases. The purpose of this article is to describe mucormycosis case in health young man and to emphasize the importance of histopatology for diagnosing suspected invasive fungal infection.

Keywords: *Chronic Mucormycosis, Invasive Fungal, Histopatology Diagnosis.*

1. INTRODUCTION

Mucormycosis is a virulent and aggressive infection caused by the genera Mucor, Absidia, Rhizopus, and Rhizomucor. It's also called as desctructive, necrotizing, and developing life-threatening disease, which can result in misdiagnosis and/or treatment. The saprophytic organisms are often present in the environment, including soil, air, food, and dust, where humans are exposed [1].

There are different types of rhinoorbitalcerebral (44–49%), cutaneous (10%–19%), pulmonary (10%–11%), disseminated (6%–11%), gastrointestinal mucormycosis (2%–11%) and miscellaneous [2]. Mucormycosis occurs most commonly in people who have an underlying immuno-compromised condition, such as diabetes, corticosteroid therapy, organ or bone marrow transplantation, neutropenia, trauma and burns, malignant and hematologic disorders, and hemodialysis therapy, among other immunosuppressive conditions [3].

Mucormycosis has a global incidence ranging from 0.005 to 1.7 per million people. The prevalence of mucormycosis in India is estimated to be 140 per million people, which is approximately 80 times higher than the prevalence in developing countries [4]. According to a systematic review and meta-analysis of 851 case reports published in 2018, the mortality rate is 46%. Patients with disseminated mucormycosis had the highest rate (68%) and those with skin disease had the lowest rate (31%) [5]

Chronic disease begins when spores are inhaled and deposit in the nasal turbinates and alveolar space. Conidia make their way to the distal alveolar space and begin to germinate. Macrophages phagocytoze conidia, followed by neutrophil attacks and the acquisition of free iron, which promotes hyphal proliferation. They cause angioinvasive tissue growth with hemorrhage, thrombosis, and tissue necrosis, as well as dissemination. Death results from the onset of fever and rapid necrosis. By direct invasion or via blood vessels, infection can spread to orbital and intracranial structures [2].

2. CASE REPORT

A 22-year-old male patient presented to the ophthalmologic emergency room with a right eye and face wound that had been accompanied by pain and pus discharge for 5 months. The lump grew and burst, releasing pus and blood, and another lump formed. His condition worsened, with the tumor necrosing rapidly. Since April 2021, the patient has been treated with antibiotics, but there has been no improvement. Weight loss occurred after a lump appeared on the lower eyelid.

The patient had no specific pathological history, such as medicine or poisonous habits, trauma, diabetes, immunodeficiency disease, TB, or a pain genital ulcer. The clinical examination revealed that the patient was aware and had no fever. On the right preauricular region, only revealed granuloma tissue, necrotic tissue, pus, and atrophic skin.

A contrast craniofacial CT scan revealed orbital cellulitis with abscess formation in the cutan-subcutan, as well as idiopathic inflammatory pseudotumor, no signs of track fistula, right mastoiditis, and right frontal and maxillary sinusitis. Antibiotics had been provided to him for 18 days since his admittance, but his condition had deteriorated. *Proteus mirabilis* was found in the pus, and *Micrococcus luteus* was found in the tissue of the cultured sample. The results of laboratory tests revealed a negative ANA test, steadily increasing leucocyte count (range: 10,88-14,51), and a high SGOT/SGPT level (73/72). Blood counts, blood sugar levels, renal function, plasma protein electrophoresis, and HIV, syphilis, and viral hepatitis B and C serologies were all normal.

The right lesion and nodule results of fine needle aspiration biopsy (FNAB) revealed granulomatous chronic inflammation. No acid-fast bacilli were found using ZN staining. Many leukocytes, no bacteria (sterile pus), and blastospores (+) were found by Gram staining. Blastospore (+) 4-6 field of view was revealed by Giemsa staining. The grain test came up negative. The early diagnosis is suspected Actinomycosis based on clinical, radiological, and pathological data. Nocardiosis and Actinomysetoma are the other differential diagnoses. The patient's treatment consists of two weeks of Penicillin G and Clindamycin, and then substituted by Piperacillin Tazobactam, then Moxifloxacin, Penicillin G, Levofloxacin eye drop, and Gentamicin cream, but his health worsened. With Periodic Acid Schiff (PAS) stain, the histopathology result revealed mucormycosis infection. After receiving amphotericin B medication, the patient's condition improved.

3. DISCUSSION

The mucormycosis usually in subjects with an underlying immunocompromised condition, but immunocompetent mucormycosis may be happen in a few cases of chronic description that inconsistent with the classic one, so that can make a misdiagnosis. The rhino-orbital type is a progressively invasive acute rhinosinusitis with ophthalmological and neurological signs [1]. Prevalence of immunocompetent mucormycosis is rare (4-19%). Although inhalation is the most common source of contamination, skin contamination after trauma is the most common cause of rhinoorbitocerebral and pulmonary type in immunocompetent people [6]. The epithelium is an active barrier against vascular and tissue invasion, and the existence of the epithelium previously compromised by chronic rhinosinusitis could explain the development of mucormycosis in immunocompetent people. Spores might be caught at the mucosa or submucosa level of the rhinosinus. If left untreated, they can infiltrate the orbit and/or skull base, causing a rhinoorbitocerebral infection, or they can enter the bloodstream and spread throughout the body [7].

The condition is challenging to diagnose as well as manage. Because the causative agent is naturally ubiquitous, can colonize normal humans, and is a very common laboratory contaminant, culture of the organism from a suspected infected site is rarely adequate to confirm a diagnosis of mucormycosis [8]. Furthermore, the pathogen may be killed during tissue grinding, which is a common practice in the tissue processing industry. Because sterile culture does not rule out infection, a proper alternative diagnosis is a fungal histopathology study [9].

Fungal histopathology description of mucormycosis is characterized by extensive angioinvasive and necrotic conditions. Periodic Acid Schiff (PAS) stain in this case revealed a granulomatous inflammatory reaction in the presence of large cells and polymorphonuclear cells, but no caseous necrosis, and occasionally only nonspecific granulomatous inflammation. (See Figure 1) In the background of necrotic tissue, there are numerous, big (5-30 m) thin-walled fungal hyphae that are nonseptate, branching perpendicularly, and have a ribbon-like appearance, as well as a branch at 90-degree angles. (See Figure 2) [10].

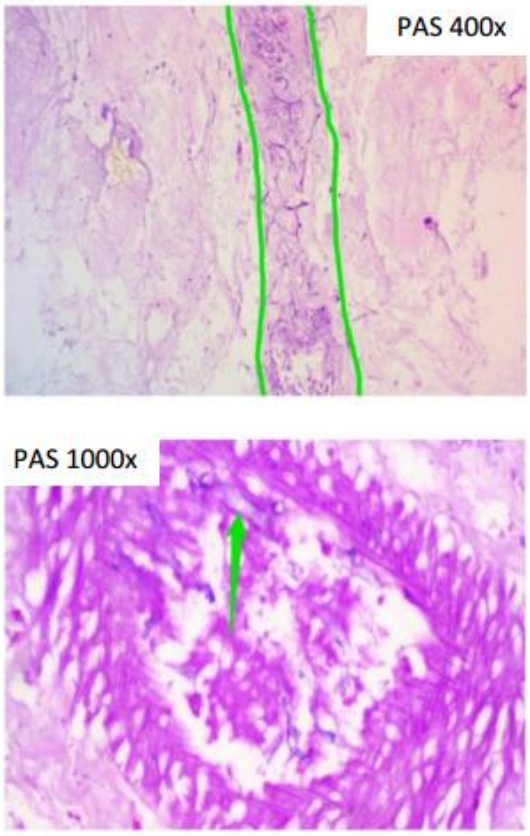

Figure 1. Periodic Acid Schiff (PAS) stains show the presence and type of suppurative/ granulomatous inflammation, invasion into soft tissues, and presence of necrosis (400x, 1000x).

Mucormycosis, Apergilosis, and Actinomycosis have a lot in common histopathologically. Mucor hyphae are not insulated and branch perpendicularly, whereas Aspergillus species hyphae are insulated, smaller in breadth, and branch at a greater angle [11]. It's tough to tell the difference between Mucormycosis and Actinomycosis. Actinomycosis is a bacterial infection caused by Actinomyces species that are nonspore-forming, anaerobic, or microaerophilic.

It's a suppurative and chronic granulomatous disease with abscesses, tissue fibrosis, and draining sinuses that's rarely seen in humans. The most important factors in Actinomycosis diagnosis are sulfur granules, biopsy regimen, and pathological examination. Other noteworthy discoveries include the center core of the rosette's periphery being stained basophilic, while the peripheral clubs were coloured eosinophilic red [12]. Submandibular space, cheek, parotid gland, teeth, tongue, nasal cavity, gingiva, and other locations are frequently implicated with Actimocymosis. The mandible is more frequently affected than the upper jaw (4:1). Rhinoorbitocerebral mucormycosis is the most affected head area [12,13].

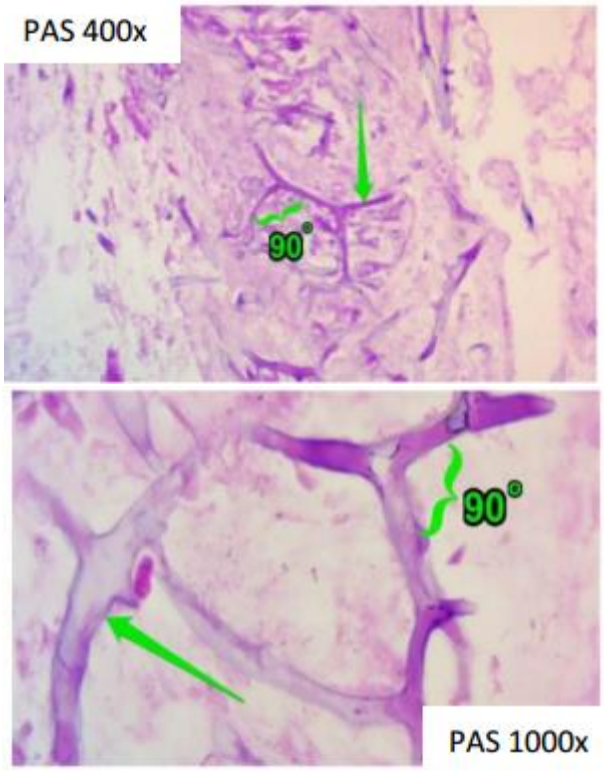

Figure 2. Periodic Acid Schiff (PAS) stain showed nonseptate, wide hyphae (7 to 30 µm) and often branch at 90-degree angles (400x, 1000x)

The fungal growth is aided by increased quantities of free iron ions. Because these fungi grow in anaerobic, aerobic, and microaerophilic environments, detecting such hyphal structures is required for a conclusive diagnosis, even though cultures are frequently negative [14]. As virulence factors, Mucorales species can produce a variety of harmful proteins and metabolic products. The availability of free iron in plasma and tissues is thought to be critical for vascular invasion pathogenesis [15]. In acidotic settings, the availability of free iron in plasma and tissues leads to angioinvasion and neurotropism, as well as reduced antifungal action [9].

Several cases of rhinoorbitocerebral mucormycosis have been misdiagnosed as cellulitis and treated wrongly with antibiotics or Voriconazole as aspergillosis [16]. The first-line treatment for mucormycosis is amphotericin B. For patients who are refractory or intolerant to Amphotericin B, newer generation triazoles (Posaconazole and Isavuconazole) are utilized as salvage therapy [17]. In contrast, Echinocandins and Voriconazole, have few effects on Mucorales. Although there is no standard for the length of treatment, amphotericin B should be started as soon as the disease is detected. Surgical debridement also plays a crucial role in increasing drug distribution and survival rates [18].

4. CONCLUSION

Mucormycosis is a rare disease, and it's unique disease because especially in immunocompetent people present an aberrant and deceptive clinical manifestation. Early diagnosis and multimodal management, both surgery and medicine, with multidisciplinary collaboration, are the core of the patient management. Identification of risk factors, clinical manifestations, radiological findings, as well as microbiological and fungal histopathology examinations improves the chances of an early diagnosis, which may prevent progressive tissue invasion, reduce the need for and/or extent of surgical resection, and improve survival rate. Mucormycosis has non-specific clinical characteristics and imaging tests. The presence of distinctive hyphae in tissue or the recovery of the organism in culture are required for a definitive diagnosis, but organisms in culture are typically sub-optimal. As a consequence, histological investigation is crucial in determining the diagnosis and demonstrating tissue invasion. The pathognomonic symptom for mucormycosis is nonseptate, broad hyphae (7 to 30 m) that branch at 90-degree angles.

ACKNOWLEDGMENTS

1. Department of Medical Microbiology, Faculty of Medicine, Airlangga University, Indonesia.
2. Department of Clinical Microbiology, Dr. Soetomo Hospital, Indonesia

REFERENCES

[1] Razem B., Dennai Y., Slimani F., Chronical rhino-orbital mucormycosis in an immunocompetent host: A case report. Int J Surg Case Rep.,2021, 82:105882. doi: 10.1016/j.ijscr.2021.105882. . PMID: 33865198; PMCID: PMC8079271

[2] Rani SU., Sivaranjani, Y., Kumar, MP.,Rao, GV., Rhinocerebral mucormycosis associated with actinomycosis in a diabetic patient: A rare presentation. Journal of oral and maxillofacial pathology : JOMFP, 2019, 23(Suppl 1), 122–125. https://doi.org/10.4103/jomfp.JOMFP_77_18

[3] Ashraf S., Ibrahim, Spellberg B.,Walsh TJ., Dimitrios P., Kontoyiannis, Pathogenesis of mucormycosis, clinical infectious diseases, 2012, Volume 54, Issue suppl_1, Pages S16–S22, https://doi.org/10.1093/cid/cir865

[4] Centers for Disease Control and Prevention, The fungi that cause mucormycosis live in the environment, National Center for Emerging and Zoonotic Infectious Diseases (NCEZID), Division of Foodborne, Waterborne, and Environmental Diseases (DFWED), 2021.

[5] Oliver A., Cornely, Ana Alastruey-Izquierdo et al., Global guideline for the diagnosis and management of mucormycosis: an initiative of the European Confederation of Medical Mycology in cooperation with the Mycoses Study Group Education and Research Consortium. Lancet Infect Dis, 2019, 19: e405–21.

[6] Mignogna MD., Fortuna G., Leuci S., Adamo D., Ruoppo E., Siano M., Mucormycosis in immunocompetent patients: a case-series of patients with maxillary sinus involvement and a critical review of the literature. *Int. J. Infect. Dis.*, 2011, 15(8):e533–540

[7] Ilharco M., Pereira C.M., Moreira L., Proença A.L., do Carmo Fevereiro M., Lampreia F., Rhinoorbital mucormycosis in the immunocompetent: experience with Isavuconazole, *IDCases*, 2019, 1

[8] Waldorf, AR.C., Halde, Vedros, NA., Murine model of pulmonary mucormycosis in cortisone-treated mice. Sabouraudia, 1982, 20:217–224.

[9] Spellberg, B., Edwards, J., Jr, Ibrahim, A. Novel perspectives on mucormycosis: pathophysiology, presentation, and management. *Clinical microbiology reviews*, 2005, *18*(3), 556–569. https://doi.org/10.1128/CMR.18.3.556-569.2005

[10] Hingad N., Kumar G., Deshmukh R., Oral mucormycosis causing necrotizing lesion in a diabetic patient. A case report. Int J Oral Maxillofac Pathol., 2012, 3:8–12.

[11] Khan S., Jetley S., Rana S., Kapur P., Rhinomaxillary mucormycosis in a diabetic female. J Cranio Maxillary Dis., 2013, 2:91–3.

[12] Lancella A, Abbate G, Foscolo AM, Dosdegani R., Two unusual presentations of cervicofacial actinomycosis and review of the literature. Acta Otorhinolaryngol Ital. 2008, 28:89–93.

[13] Guvercin M., Gurler G., Goktay O., Kadir T., Gursoy B., Cervicofacial actinomycosis: A case report. Oral Health Dent Manage Black Sea Countries, 2005, 4:58–61

[14] Escobar JS., Ramírez JG., de Villajos Ortiz E., López MP., Barberán JL., Pulmonary mucormycosis: A case report and review of the literature. Arch Bronconeumol., 1996, 32:47–9

[15] Morace G, Borghi E., Invasive mold infections: Virulence and pathogenesis of mucorales. Int J Microbiol., 2012, 349278.

[16] Ayoade F., Cloke C., Quiroz T., Tjendra Y., A case of rhino-orbital mucormycosis in an immunocompetent patient following Hurricane Irma, *IDCases*, 2019, *vol.*18.

[17] Sipsas, NV., Gamaletsou, MN., Anastasopoulou, A., Kontoyiannis, DP., Therapy of Mucormycosis, *Journal of fungi (Basel, Switzerland)*, 2018, *4*(3), 90. https://doi.org/10.3390/jof4030090

[18] Kwon-Chung KJ., Taxonomy of fungi causing mucormycosis and entomophthoramycosis (zygomycosis) and nomenclature of the disease: Molecular mycologic perspectives, *Clin. Infect. Dis.*, 2012, 54(Suppl. 1):S8–S15. doi: 10.1093/cid/cir864.