Covid-19 Infection in a Teenage Patient with Nasopharyngeal Cancer
A Case Report in Rural Area

Hamsu Kadriyan[1, *], Yudhi Kurniawan[1], Sang Ayu Kompiyang Indriyani[1], Nova L. Audrey Pieter[2], Masyita Gaffar[2], and Abdul Qadar Punagi[2]

[1]*Department ENT-HN, Faculty of Medicine, University of Mataram, West Nusa Tenggara General Hospital, Indonesia*
[2]*Department ENT-HN, Faculty of Medicin, Hasanuddin University, Indonesia*
[*]*Corresponding author. Email: hamsu@unram.ac.id*

ABSTRACT
Covid-19 with nasopharyngeal cancer (NPC) comorbidities are rare in children. Post-chemoradiation cancer patients are one of the vulnerable groups to have Covid-19 infection. The Covid-19 infection could occur in an urban and rural area. More challenging issues occur in managing Covid-19 patients, furthermore, if there were several comorbidities. In this report, presented a case of post-chemoradiation 14-year-old children with nasopharyngeal cancer and pneumonia Covid-19 confirmed. The patient also documented several comorbidities such as anaemia, hypoalbuminemia, and liver metastasis. The case was found in Lombok, one of the rural areas in Indonesia. The comprehensive treatment was given and finally the patient cure from Covid-19 infection. The patient underwent a conversion within 14 days based on the RT-PCR examination. As a conclusion, Covid-19 could infect children especially those who have an immunity impairment such as post-chemoradiation on NPC patients. Covid-19 with several comorbidities could be managed well either there were several obstacles in rural areas.

Keywords: *Covid-19, NPC, Children, RT-PCR, Rural Areas.*

1. INTRODUCTION

Covid-19 caused by the coronavirus has been declared as a global pandemic by WHO. This is inseparable from the spread of viral infections originating from Wuhan which is spreading rapidly. Currently, the disease has infected more than 200 countries in the world. The incidence is increasing exponentially and currently reaches nearly 16 million people worldwide as of July 25th, 2020 [1].

The infection could occur either to people living in both urban and rural areas. It is well known that the health facilities are much better in urban than rural areas, including the facilities on the management of Covid-19 infection [2]. Lombok consists several rural areas, the island of Lombok is located some distance from the Java island, which is the mainland of Indonesia.

Symptomatic Covid-19 is more commonly reported in adulthood; however, children can also be infected. A report released by the CDC [3] USA states that 98.3% of Covid-19 cases occur in adults while the rest occur in children. In addition, Covid-19 in children case has been reported in several countries [4, 5, 6].

Moreover, nasopharyngeal cancer (NPC) is a disease with a high incidence in Asia, including Indonesia [7]. Kadriyan et al. [8], reported 40 cases of NPC. The report found that most patients were above 40 years old and only 5% were under 21 years old.

Some reports indicate that coronavirus infection is highly susceptible in patients with decreased immunity and can have more severe effects on comorbid patients such as NPC [9]. Other comorbidities may alter the progression of Covid-19 infection, this includes condition such as diabetes, hypertension, anaemia, thrombocytopenia, hypoalbuminemia, as well as the kidney and liver disfunction [10, 11, 12].

In this report, the authors presented a Covid-19 case in children who has been diagnosed with NPC and have

several other comorbidities. The authors managed this patient in one of the rural health facilities in Lombok, Indonesia. Management of patients with several comorbidities was more complicated than those who did not have or a limited number of comorbidities. Furthermore, the management of the case with limited resources such as in rural areas is more challenging.

2. CASE REPORT

A 14-year-old female presents with pain in the whole body accompanied by fever. This complaint has been felt since 4 days before the hospital visit. The patient did not experience coughing and runny nose, however, she felt difficult to breathe. On two previous days, the patient had visited the emergency department with a similar complaint. The complaints on breathing difficulties and pain were improved after the administration of symptomatic medication and nasal oxygen administration. However, on the 4th day, because of the complaint recurrence, the patient was advised to be hospitalized and undergo an isolation and screening procedure for Covid-19 infection.

Previously, the patient was a stage IV B NPC patient who had been diagnosed since August 2019. A histopathology examination showing undifferentiated carcinoma (WHO type 3) and head CT scan (Figure 1) showing a mass in the nasopharynx that extends to the parapharynx and the nasal cavity. This patient has undergone 6 series of chemotherapy with cisplatin and paclitaxel regimens and 33 series of radiotherapy with Intensity Modulated Radiotherapy (IMRT). Finally underwent radiotherapy on 5 May 2020.

On physical examination, body temperature 38^0 C. On examination of the head, found signs of anaemia but cyanosis was not found. No mass was found on the nose and neck. The lung examination found a decreased of vesicular breathing sound in the right lung with crackles, and minimal distention of abdomen.

Figure 1. Head CT scan before chemoradiation showed the nasopharyngeal mass extended to the nasal cavity and parapharyngeal space

Extremities within normal limits upon hospital admission, chest X-ray showed bilateral infiltrate on both lungs, mostly in the right lung. Moreover, laboratory results show haemoglobin (HB) levels of 8.9 g/dL, Leukocytes 14,690 /uL, Platelets 523,000 /uL with NLR 13.6, with an increase in CRP 118 ng/L, electrolytes serum within normal limits, an increase in GOT 100 U/L and GPT 24 U/L. Kidney function and sugar levels were within normal limits. X-pert MTB/RIF showed undetected Mycobacterium tuberculosis. RT-PCR examination (Figure 2a and 2b) of nasopharyngeal and oropharyngeal swab confirmed the presence of the Sars-Cov-2 virus (Covid-19). Based on the data gathered, we diagnosed the patient with NPC and bronchopneumonia due to moderate Covid-19 infection.

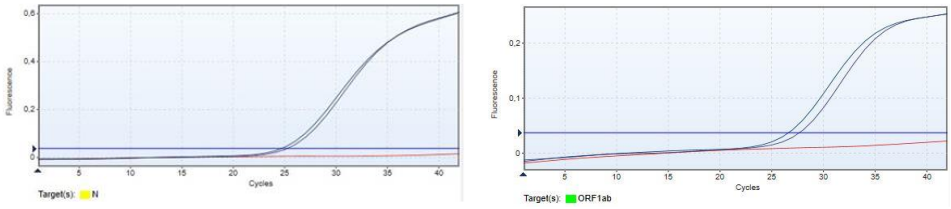

(a) (b)

Figure 2. (a) Target N gene of Covid-19 showed a positive result (b) Showed the gene ORF1ab target with the positive result

The treatment given to this patient was ceftriaxone and azithromycin 500 mg once a day. Symptomatic drugs and other supportive therapy were also given. Antivirals were not given to this patient, neither hydroxychloroquine. This patient was also given Packed Red Cells for haemoglobin (HB) correction. Evaluation in the first 5 days of therapy, there was no improvement seen. Then, the ceftriaxone changed with vancomycin according to the sputum culture that showed mixed infection with staphylococcus aureus which was sensitive to vancomycin. After 2 weeks of treatment, the clinical manifestation was getting better, and 2 consecutive RT-PCR results were negative.

Figure 3 Head CT Scan after Chemoradiation showed a slight thickening of the left nasopharynx and lymph node enlargement.

Evaluation of the results of chemoradiation (5 weeks ahead of chemoradiation) by head CT scan (Figure 3) showed thickening of the nasopharyngeal wall and neck lymph nodes. Chest CT scan (Figure 4) shows pneumonia with minimal pleural effusion, but no sign of metastasis. Abdominal ultrasound showed the presence of a coin lesion that showed the presence of liver metastases, while the results of the bone survey found no signs of metastasis. Based on the results of these examinations, this patient experienced a partial response to chemoradiation.

Monitoring of post-treatment laboratory results obtained albumin 2.7 g / dl, GOT, and GPT 412 and 44 respectively. For low albumin to be corrected to normal, while for liver metastases planned for chemotherapy with cisplatin and paclitaxel regimens as many as 6 series.

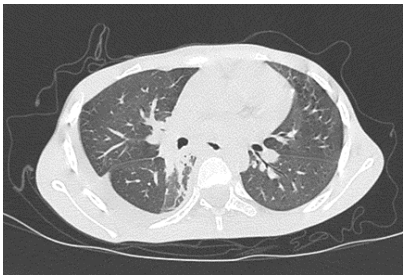

Figure 4 Thorax CT scan showed a sign of pneumonia

3. DISCUSSION

Data from the CDC USA shows that 2,572 of 149,082 (1.7%) confirmed to have Covid-19 infection are children under 18 years. The distribution is almost evenly distributed in all age groups [3]. In China, 728 cases of children were reported to be infected with Covid-19 during January to February 2020. There were no significant differences between male and female sufferers [6]. In Malaysia there were 4 reported cases of Covid-19 in children until the end of February 2020. Mostly (75%) were Chinese citizens who were visiting Malaysia [5].

In this report, the authors documented several comorbid in the patient, including NPC itself, 3 weeks after chemoradiation that leads to immunocompromised, anaemia, hypoalbuminemia, liver metastasis, and pneumonia. The independent factor of each comorbid itself could alter the progress of the Covid-19 infection. Moreover, if the comorbid occurs at a similar time may cause a more severe condition.

Regarding Covid-19 in cancer patients, Liang et al. [13] found 18 out of 1590 Covid-19 patients with a history of cancer (1% of total cases), higher than the overall cancer incidence in China. Other research in 3 hospitals in Wuhan, China reported 28 cases of Covid-19 in cancer patients. The most frequent cancer found in this report was lung cancer, while only 1 case of NPC [14].

As known that patients with comorbidities such as cancer and post-chemoradiation have decreased immunity. Furthermore, this condition can facilitate the transmission of coronavirus infection in these patients. On the other hand, when viewed from case data that has been reported, the actual incidence of Covid-19 in cancer patients is quite small. Venkatraman et al. [15] suggested the use of radiotherapy as a therapeutic measure in Covid-19 cases. In his opinion, low-dose radiation can kill the virus. This suggestion could be associated with the low number of Covid-19 infections in cancer patients, however, more clinical research is imperative.

According to Lee et al. [16], no differences were found between chemotherapy in the 4 weeks before being infected with Covid-19 with patients who did not receive chemotherapy in the 4 weeks before they were confirmed to have Covid-19. Likewise, the mortality rates between cancer patients who were radiotherapy and not radiotherapy in the last 4 weeks found no significant differences [16].

The main symptom of cancer patients infected with Covid-19 is fever. Reports from Dai et al. [9] show fever occurs in 68 of 105 (64.5%) cases. Muscle pain (myalgia) is also a complaint that is often found in 5.7% of cases [9]. Other studies have also found similar things [14]. In this case, the main symptoms in this patient are fever and pain in the whole body. Pain throughout the entire body can be confused with the possibility of bone metastases. In this patient after chemoradiation, a bone scan was performed and no signs of bone metastasis were found. Based on those findings, the myalgia in this patient may occur due to Covid-19.

Anaemia is commonly found in NPC patients, Kadriyan et al. [8] reported that 87.5% of NPC patients were found to suffer from anaemia. Anaemia can occur due to cancer itself, or a direct effect of treatment (both chemo and radiation), and secondary effects from the recovery of NPC treatment [8]. On the other hand, in Covid-19 patients it was found that HB levels were

significantly lower than healthy people. Moreover, for severe cases, HB is significantly lower than mild cases, although the median HB of Covid-19 patients is still within normal limits (13.4 g / dl) [17].

Liver metastasis was a common distance spreading of NPC. Tian et al [18] reported 85 NPC patients with liver metastasis on their 10-year analysis. Liver disfunction was one of the comorbid that can alter the severity of Covid-19 [10]. After 2 weeks of treatment, this patient experienced significant clinical improvement, including muscle pain relief. Moreover, negative results of RT-PCR were received after 2 weeks. A chest x-ray in this patient showed bronchopneumonia, which may occur secondary to Covid-19. Based on this result, the authors decided to continued antibiotics. In addition, antiviral was not given based on Chiotos et al. [11] and Wang and Zhu [19].

In the North American multicentre initial guidance on antiviral use in children with Covid-19 concluded that antiviral could be used for severe cases only. In this guideline, remdesivir was the most antiviral recommended. In the case of remdesivir was not available, Hidroxychloroquine could be given [11]. On the other hand, according to Wang and Zhu [20], Interferon-α (IFN-α) was the most recommended antiviral for Covid-19. Antibiotic recommendation for children with Covid-19 was ceftriaxone in initial admission, but it could be changed after the microbiology testing found a specific bacteria and it's sensitive antibacterial [20]. In this case, the authors change the treatment to vancomycin based on blood culture results.

Simultaneously, evaluation of the thorax CT scan after healing from Covid-19 found a minimal pleural effusion. Pleural effusion may occur due to bronchopneumonia or tuberculosis infection, but the result of Xpert MTB/RIF was negative. The pleural effusion can also be affected by the presence of hypoalbuminemia due to liver metastasis as indicated by the result of an abdominal ultrasound.

The comprehensive care was given to this patient. Although there were several comorbidities occurs, finally she getting a cure for her covid-19 infection. The success therapy on this report may be due to the patient was a teenager. According to Ge et al. [10], the mortality rate was higher in the older patient with several comorbidities. Luckily, the patient's condition did not fall to hypoxia, furthermore, she did not need a ventilator because the ventilator in our hospital was very limited. The limited ventilator not only happened in a rural area but also in urban areas due to the escalation needed of this equipment to handle the Covid-19. However, urban areas have better access and facilities [2].

The next step should be continuous with chemotherapy to handle the liver metastasis. Before starting chemotherapy, laboratory indicators such as HB, albumin, liver, and kidney function test as well as electrolyte should be normal to reduce the risk of organ failure.

The prognosis of NPC especially for stage IV in children's cases is poor. The one and five-year survival rates were consecutively 94,8% and 64,7%. The median survival time was 44,5 months according to the analysis among 32 children NPC cases [21]. The other study found 5-year overall survival rate for stage IV in 158 children and adolescent was 77,1% [22].

The message that can be taken from this case is the Covid-19 infection can occur in children and can be managed well although there were several comorbid such as NPC, post chemoradiation, leucocytosis, anaemia, hypoalbuminemia, pneumonia, and liver metastasis. The limited resources in a rural area should not be an obstacle in managing the case, however, an adaptation should be done to combat the Covid-19 infection. Management of cancer patients itself is still a challenge especially in children; furthermore, if there were Covid-19 which the treatment does not remain to establish. The simultaneous management of all comorbidities should be address to gain a better outcome.

4. CONCLUSION

Although rare, Covid-19 could infect children, especially those who have an immunity impairment such as post-chemoradiation on NPC patients. Covid-19 with several comorbidities could be managed well either there were several obstacles in rural areas. Hopefully, the pandemic could be ended soon and the distribution of resources in urban and rural areas could be managed better in the future

AUTHOR'S CONTRIBUTION

Concept – HK; Resources, material and literature search - HK, YK, SAKI; Writing - HK, SAKI; Critical review: NOLP, MG, AQP. The author(s) read and approved the final manuscript

ACKNOWLEDGMENTS

The author would like to thanks to Fahrin Ramadan Andiwijaya, for his great translation and language revision of this manuscript. We would also thank Triana Dyah Cahyawati for her contribution to x-ray data

ETHICS APPROVAL AND CONSENT TO PARTICIPATE

A single case report does not typically require approval from our Institutional Review Board

CONSENT FOR PUBLICATION

Guardian of the patient consent for publication was obtained.

COMPETING INTEREST

The authors declare that they have no competing interests.

CONSENT FOR PUBLICATION OF THE IMAGE

Author declare that the patient or guardian agreement to published her images on this journal.

REFERENCES

[1] WHO. *Coronavirus disease COVID-2019*. 2020;8:3–8. doi:10.30895/2312-7821-2020-8-1-3-8

[2] Truog RD, Mitchell C, Daley GQ. The Toughest Triage — Allocating Ventilators in a Pandemic. *N Engl J Med* 2020;382:1973–5. doi:10.1056/NEJMp2005689

[3] CDC COVID-19 Response Team. Coronavirus Disease 2019 in Children - United States, February 12-April 2, 2020. *MMWR Morb Mortal Wkly Rep 2020*;69:422–6. doi:10.15585/mmwr.mm6914e4

[4] Cruz AT, Zeichner SL. COVID-19 in Children : Initial Characterization of the Pediatric Disease. *Pediatrics 2020*;145:1–3. doi:10.1093/cid/ciaa198

[5] See KC, Liew SM, Ng DCE, et al. COVID-19: Four Paediatric Cases in Malaysia. *Int J Infect Dis 2020*;94:125–7. doi:10.1016/j.ijid.2020.03.049

[6] Dong Y, Mo X, Hu Y, et al. Epidemiology of COVID-19 Among Children in China. *Pediatrics 2020*;145:e20200702. doi:10.1542/peds.2020-0702

[7] Salehiniya H, Mohammadian M, Mohammadian-Hafshejani A, et al. Nasopharyngeal cancer in the world: Epidemiology, incidence, mortality and risk factors. *World Cancer Res J 2018*;5:e1046. doi:10.15419/bmrat.v5i7.460

[8] Kadriyan H, Sulaksana MA, Lestarini IA, et al. Incidence and characteristics of anemia among patients with nasopharyngeal carcinoma in Lombok, Indonesia. *AIP Conf Proc 2019*;2199:0700151–6. doi:10.1063/1.5141329

[9] Dai M, Liu D, Liu M, et al. Patients with cancer appear more vulnerable to SARS-COV-2: a multi-center study during the COVID-19 outbreak. *Cancer Discov 2020*;10:1–10. doi:10.1158/2159-8290.CD-20-0422

[10] Ge H, Wang X, Yuan X, et al. The epidemiology and clinical information about COVID-19. *Eur J Clin Microbiol Infect Dis 2020*;39:1011–9. doi:10.1007/s10096-020-03874-z

[11] Chiotos K, Hayes M, Kimberlin DW, et al. Multicenter initial guidance on use of antivirals for children with Coronavirus Disease 2019/Severe Acute Respiratory Syndrome Coronavirus 2. *J Pediatric Infect Dis Soc 2020*;:1–15. doi:10.1093/jpids/piaa045

[12] Lippi G, Plebani M, Henry BM. Thrombocytopenia is associated with severe coronavirus disease 2019 (COVID-19) infections: A meta-analysis. *Clin Chim Acta 2020*;506:145–8. doi:10.1016/j.cca.2020.03.022

[13] Liang W, Guan W, Chen R, Wang W, Li J, Xu K, Li C, Ai Q, Lu W, Liang H, Li S HJ. Cancer patients in SARS-CoV-2 infection : a nationwide analysis in China. *Lancet Oncol 2020*;2045:6–7. doi:10.1016/S1470-2045(20)30096-6

[14] Zhang L, Zhu F, Xie L, et al. Clinical characteristics of COVID-19-infected cancer patients : a retrospective case study in three hospitals within Wuhan , China. *Ann Oncol 2020*;31:1–8. doi:https://doi.org/10.1016/j.annonc.2020.03.296

[15] Venkatraman P, Sahay JJ, Maidili T, et al. Breakthrough of COVID-19 using radiotherapy treatment modalities q. *Radiother Oncol 2020*;148:225–6. doi:10.1016/j.radonc.2020.04.024

[16] Lee LYW, Cazier JB, Starkey T, et al. COVID-19 mortality in patients with cancer on chemotherapy or other anticancer treatments : a prospective cohort study. *Lancet 2020*;6736:1–9. doi:10.1016/S0140-6736(20)31173-9

[17] Sun S, Cai X, Wang H, et al. Abnormalities of peripheral blood system in patients with COVID-19 in Wenzhou, China. *Clin Chim Acta 2020*;507:174–80. doi:10.1016/j.cca.2020.04.024

[18] Tian YM, Zeng L, Wang FH, et al. Prognostic factors in nasopharyngeal carcinoma with synchronous liver metastasis: A retrospective study for the management of treatment. *Radiat Oncol 2013*;8:1–7. doi:10.1186/1748-717X-8-272

[19] Wang Y, Zhu LQ. Pharmaceutical care recommendations for antiviral treatments in

children with coronavirus disease 2019. *World J Pediatr 2020*;16:271–4. doi:10.1007/s12519-020-00353-5

[20] Sankar J, Dhochak N, Kabra SK, et al. COVID-19 in Children: Clinical Approach and Management. *Indian J Pediatr 2020*;87:433–42. doi:10.1007/s12098-020-03292-1

[21] Chen J, Hu F. Clinical and prognostic analysis in 32 pediatric nasopharyngeal carcinoma. *J Cancer Res Ther 2015*;11:226–9. doi:10.4103/0973-1482.168191

[22] Liu W, Tang Y, Gao L, et al. Nasopharyngeal carcinoma in children and adolescents - a single institution experience of 158 patients. *Radiat Oncol 2014*;9:4–10. doi:10.1186/s13014-014-0274-7