Advances in Health Sciences Research, volume 48
2nd Aceh International Dental Meeting 2021 (AIDEM 2021)

Two Periodontal Surgical Therapies in One Visit:
Gingival Depigmentation and Frenectomy
(Case Report)

Siti Sopiatin[1*], Ira Komara[1], Ina Hendiani[1], Budhi Cahya Prasetyo[1], Chandra Andi Bawono[1]

[1] *Department of Periodontics, Faculty of Dentistry, Universitas Padjadjaran, Indonesia*

[*]*Corresponding author. Email: siti.sopiatin@unpad.ac.id*

ABSTRACT
Gingival staining is closely related to aesthetic problems. The frenectomy of the frenulum with coronal attachment to the tooth surface is one of the main causes of periodontal disease due to the difficulty of maintaining oral hygiene. Patients who experience these two conditions require at least two types of surgeries. This case report aims to provide information that two surgeries can be performed in one visit only. A 29-year-old male patient visited the Periodontal Clinic of Dental Hospital, Universitas Padjadjaran with the main complaint of staining of the gingiva and the maxillary labial frenulum obstructing movement during tooth brushing. On intra-oral examination, the maxillary gums looked dark and frenulum attachment extent coronally to interdental papilla of incisive maxillary anterior teeth. The treatments in treating gingival staining and removing highly frenulum attachment were gingival depigmentation and frenectomy performed in one visit. **Conclusion:** The gingival depigmentation and frenectomy therapies performed in one visit were effective in terms of time and trauma caused, also more efficient in terms of treatment costs. Benefits in the form of aesthetic can be obtained along with the benefits of obtaining periodontal tissue health.

Keywords: *Gingival depigmentation, Frenectomy, Periodontal surgical therapy.*

1. INTRODUCTION

The physiological gingival color is generally pink, similar to the color of coral. [1] In certain dark-skinned races, the color of the gingiva also tends to be darker. In certain conditions, excessive staining of gingiva called gingival hyperpigmentation. It is due to excessive melanin deposition by active melanocytes in layers of basal and suprabasal oral epithelium cells. This condition can occur in all races and there is no significant difference between men and women. [2] This difference is influenced by the thickness of keratin layer, epithelium thickness, vascularity, and composition of melanin pigment. Melanin is an endogenous brown pigment, a non-haemoglobin derivative that is mostly produced by melanocytes. The pigmentation degree are varies from person to person, it depends on melanoblasts activity. [3]

Etiology of gingival hyperpigmentation can be endogenous or exogenous, including genetic factors, consumption of certain foods or drugs, sun exposure, heavy metals, endocrine diseases, Peutz Jegher's syndrome, inflammation, smoking habits, etc. Dummett stated that gingival hyperpigmentation can be triggered by various factors, including mechanical, chemical and physical factors. [4] [5]

Hyperpigmentation can be classified according to Dummett Gupta Oral Pigmentation Index (DOPI) into:

1. Clinical pigmentation: The colour of gingiva is pink
2. Mild clinical pigmentation: The colour of gingiva is light brown gingival
3. Moderate clinical pigmentation: The colour of gingiva is medium brown gingiva or a mixture of pink and brown
4. Severe clinical pigmentation: The colour of gingiva is dark brown or bluish black. [6]

Gingival hyperpigmentation can be treated by depigmentation of gingival surgery, a periodontal surgery in the form of taking gingival hyperpigmentation tissue using certain instruments, including scalpels, burs, electrosurgery, cryosurgery, chemical, laser, combination, etc. [7]

Other aesthetic related complaint is a cases involving of frenulum attachment, especially in the anterior maxilla, named the superior labialis frenulum. The frenulum is a small fold of mucous membrane that contains muscle fibers attached the lips or cheeks to the alveolar bone that are useful for limiting the lips and cheeks movement. [1]

According to the extent of frenulum attachments, those are classified into:

1. Mucosa: The attachment of the frenulum extends to the mucogingival border.
2. Gingiva: The attachment of the frenulum extends to the attached gingiva.
3. Papillary: The attachment of the frenulum extends to the interdental papillae.
4. Penetrating Papilla: The attachment of the frenulum passes through the alveolar and extends to the palatine papilla. [8]

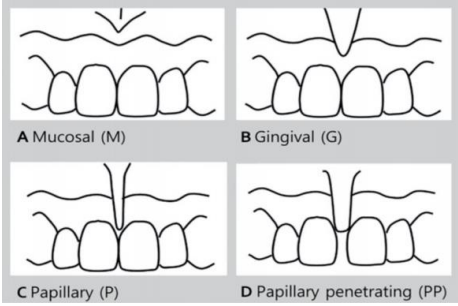

Figure 1. Frenulum Attachment

Based on the attachment, the frenulum attachments are classified into:

1. Low frenulum is a condition where the entire frenulum is attached to the alveolar mucosa
2. Moderate frenulum is a condition where the entire frenulum is attached to the alveolar mucosa to the attached gingiva
3. High frenulum is a condition where the entire frenulum is attached to the mucosa of alveolar to the attached gingiva and gingival margin. [9]

Treatment of high frenulum attachment is frenectomy. Frenectomy is a minor surgical procedure to remove the entire frenulum and its attachments to the underlying bone. Frenectomy can be performed with a scalpel technique (conventional), electro-surgery, laser, etc.

This case report aims to identify periodontal surgical therapy which was carried out in one visit for 2 cases involving the gingiva, including the case of gingival hyperpigmentation and high frenulum attachment.

2. CASE REPORT

A 29-years-old man, a patient of the Periodontal Clinic of the Dental Hospital, Universitas Padjadjaran, had a main complaint of blackish-brown staining of the gingiva in the anterior maxillary area along the teeth 13 to 23 and difficulty in brushing the anterior teeth. maxilla because it is blocked by a thick frenulum that has a high attachment. There was no history of swelling and no pain. The patient has been smoking since about 4 years ago until now. The value of oral hygiene in the fist visit was 25.3% calculated using the O'Learry plaque index.

Figure 2. Clinical features of the first visit.

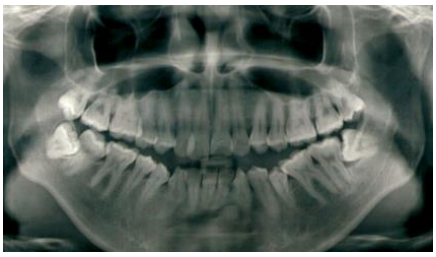

Figure 3. Anterior radiograph of mandible shows no abnormalities

Examination of the patient showing gingival hyperpigmentation and frenulum attachment cases. Treatment plan for the patient including Depigmentation of gingival surgery and frenectomy surgery which will be carried in one visit, instead of 2 concecutive surgery.

Initial therapy was performed at the first visit, including scaling of maxilla and mandible region and oral hygiene instructions. After 1 month evaluation, the patient was called for the the next visit. The blood tests of the patient were within normal so the patient was continued for surgery.

Figure 4. Clinical features after initial therapy.

Prior to surgery, an informed consent was signed, instruments, materials, operators and operator assistants, and patient were prepared.

Surgery begins with anesthesia. The first surgical procedure was gingival depigmentation. Depigmentation in this case was carried out using a scalpel starting from region 1 followed by region 2 in order to remove the hyperpigmented gingival layer.

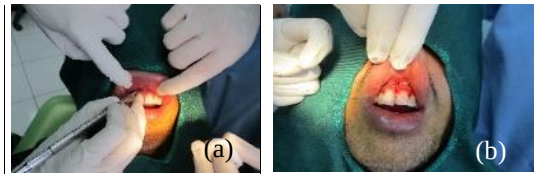

Figure 5. Depigmentation Procedure using Scalpel technique (a), Gingival appearance after scrapping (b)

The next procedure is frenectomy. Frenectomy is performed using scalpel, the frenulum was hold with arterial clamp, then the frenulum was cut down at the top and bottom of the arterial clamp. The cut tissue was then trimmed using tissue nipper to obtain a fine gingival contour.

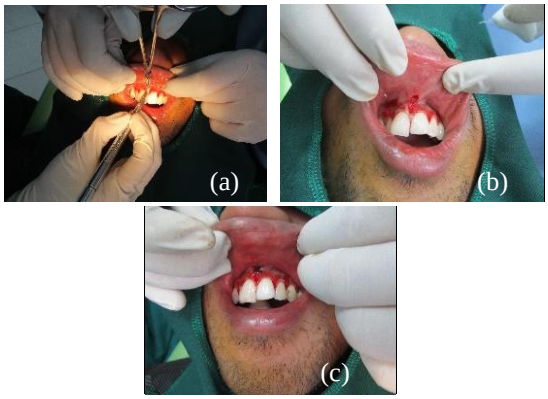

Figure 6. Frenectomy procedure: frenulum cutting (a), open wound post frenulum cutting (b), suturing (c).

The next step is suturing the frenulum starting in the middle then the top and bottom. Irrigation was carried out again and then the surgical area was covered by periodontal dressing. The patient was given postoperative instructions and prescribed antibiotics, analgesics and mouthwashes. Patients scheduled for control after 1 week and 1 month.

Figure 7. Periodontal dressing application.

3. DISCUSSION

Gingival excessive staining is a common case related to aesthetics problem. [2] In this case, patient complained about his hyperpigmented gingiva, and his frenulum. Surgical depigmentation and frenectomy were performed at maxilla. Gingival hyper-pigmentation is caused by many factors. There is a positive correlation with skin color and the severity of melanin pigmentation. [10] In this patient, the gingival hyperpigmentation was severe clinical pigmentation because the hyperpigmented color was blackish-brown and be caused by smoking. Therefore, in this case, depigmentation was carried out along with patient education of smoking cessation to prevent recurrence of hyperpigmentation and periodontal disease.

Depigmentation technique that applied in this case is depigmentation with scalpel technique. This technique can be done with effective in time, relatively easy without requiring special skills and equipment as in other methods such as laser, electrosurgery, etc. However, the scrapping of hyperpigmented tissue must be carried out carefully so as not to exceed the basal layer where the

melanin pigment cells are located, and trying not to involve the deeper tissue than the basal layer which can cause excessive bleeding, even cause the bone to be exposed. To ensure that the scrapings are taken well, irrigation with saline solution is carried out so that good visibility is obtained, then scraping is carried out until all hyperpigmented targets are completely removed. Thus, this procedure needs understanding of structure of gingival layer and expertise in removing of hyperpigmented tissue properly.

Regarding frenectomy, knowledge of the frenulum is also important, especially regarding its attachment. The anatomic conditions of the frenum attachment vary. The attachment of the frenulum that can cause periodontal disease is the high attachment of the frenulum, as well as the attachment of the frenulum passes through the alveolar and extends to the palatine papilla. This condition not only can take to aesthetic problems, but also interfere with a person's movement when brushing teeth, cause problems with the comfort of wearing dentures, hinder tooth movement during orthodontic treatment, and can even cause recession due to retraction of the gingival margin by the frenulum. This can also lead to periodontal problem. [9] [11]

High frenulum attachment occurs because during the growth and development of the teeth and jaws, the frenulum attachment does not migrate apically. The normal location of the frenulum to the periodontal tissue is attached to the attached gingiva so that when it is functioning it does not cause excessive traction. The superior labialis frenulum is of embryonic structure remnant connected to tubercle of upper lip and palatine papilla. The labial frenulum in infancy normally has an attachment area that is close to the crest of the alveolar process and in the midline. In the period of the primary dentition, the superior labial frenulum is often seen attached to the alveolar process between the upper central incisors. Along with normal dentoalveolar growth, the upper alveolar processes will grow coronally and the area of attachment of the superior labial frenulum will become more apical. [12]

The normal location of the frenulum to the periodontal tissue is on the attached gingiva so that when it is functioning it does not cause excessive traction which leads to gingival recession. Therefore, for clarity, indications for frenectomy are as follows:

1. Frenulum attachment that exacerbate gingival and pocket inflammation.
2. Frenulum attachment that causes dental diastema.
3. Frenulum attachment that impede maintenance of oral hygiene.
4. Ankyloglossia.
5. Frenulum attachment that interferes with the retention and stabilization of the denture.

The Contraindications for frenectomy are as follows:

1. The patient has systemic disorders, such as uncontrolled Diabetes Mellitus and bleeding disorders.
2. The patient's psychology is not supportive. [13]

On evaluation 1 week postoperatively, the surgical area gingiva did not appear hyperpigmented, the gingiva looked pale, the frenulum looked red and seemed to be still in the healing process. The patient did not experience pain in either the gingiva or the frenulum. On evaluation 1 month postoperatively, the gingiva appeared normal, coral pink in color and the frenulum in the postoperative area had the same color as the surrounding gingiva. The patient feels satisfied and comfortable, both in aesthetic function and in maintaining oral hygiene where the patient does not experience difficulty in brushing teeth. This good result was also obtained in the case carried out by Basir (2020) where patients who received treatment showed satisfactory results in terms of aesthetics, comfort in cleaning teeth, and their effectiveness. [14]

Figure 8. Postoperative evaluation of 1 week (a, b), and 1 month (c, d).

The healing time required after depigmentation surgery is approximately 1 week to 1 month. Similarly, the healing time required after frenectomy. Thus, if a patient receives gingival depigmentation treatment not in one visit with a frenectomy, it will take at least twice of that time which is about two months. In this case, the area that required depigmentation and frenectomy was in the same anterior maxillary region. Thus, surgeries were performed in one visit. However, these surgeries were performed sequentially, beginning with depigmentation. The reason was that depigmentation surgery only involves the surface layer of the tissue so that there was less bleeding, whereas in frenectomy surgery involving the deeper tissue, causing open wounds that produce more bleeding and require suturing.

The advantage of performing two surgeries in one visit is only require a series of preparation (basic and surgical instruments, also materials), anesthesia, surgical completion including prescription and the number of control visits.

Cases that can be operated on simultaneously are cases that are in the same region, the patient has good psychology, the operator is able to perform surgeries well at the same time. Meanwhile, in cases where surgery cannot be performed simultaneously such as in conditions where the surgical is not in the same region, the patient's psychological condition is not supportive, the operator is not ready to perform two surgeries at once.

4. CONCLUSION

The gingival depigmentation and frenectomy therapies performed in one visit were effective in terms of time and trauma caused, also more efficient in terms of treatment costs. Benefits in the form of aesthetic can be obtained along with the benefits of obtaining periodontal tissue health.

AUTHORS' CONTRIBUTIONS

All of the author have contribution in concepts, design, definition of intellectual content, literature search, manuscript preparation, editing and review.

ACKNOWLEDGMENTS

The authors would like to thank to all staff of Department Periodontics, Faculty of Dentistry, Universitas Padjadjaran and Aceh International Dental Meeting 2 (AIDeM 2) committee.

REFERENCES

[1] Pavlic V Brkicc B, Marind S, Cicmil S, Vukelic MG, Aoki Gingival melanin depigmentation by Er:YAG laser: A literature review. J Cosmetic Laser Therapy 2018, 20(2):85–90

[2] Yang J Wang Li,Wu X, Cheng T, Jiang H. High peak power Q-switched Er:YAG laser with two polarizers and its ablation performance for hard dental tissues. 2014, 22(13) DOI: 10.1364/OE.22.015686

[3] Devishree, Gujjari SK, Shubashini PV. Frenectomy: A review with the report of surgical technique. Journal of Clinical & Diagnostic Research. 2012, 6(9): 1587-1592

[4] Mirko, P., Miroslav, S., & Lubor, M. (1974). Significance of the labial frenum attachment in periodontal disease in man. Part I. Classification and epidemiology of the labial frenum attachment. *Journal of periodontology*, *45*(12), 891–894. https://doi.org/10.1902/jop.1974.45.12.891

[5] Dummet CO, Barens G. Oromucosal pigmentation: An updated literary review. J Periodontol 1971,42:726-36

[6] Suryono. Incision below the clamp sebagai modifikasi teknik insisi ada freneltomi untuk minimalisasi perdarahan. Majalah kedokteran gigi Desember 2011:18(2) 187-190

[7] Naini, F. B. and D. S. Gill, London. Labial frenectomy: Indications and practical implications DOI: 10.1038/sj.bdj.2018.656 British Dental Journal, Volume 225 No. 3, August 10 2018

[8] Suproyo H. Penatalaksanaan penyakit jaringan periodontal edisi 2. Yogyakarta: Kanwa, Publisher,2009.H. 55-65

[9] Thahir H, Djais AI, Wendy S, Achmad MH, Akbar FH. Management of maxillary labial frenum and comparison between conventional techniques and incision-below the-clamp technique: case report. J Dentomaxillofac Sci 2018,3: 61–6

[10] Lioliou E, Kostas A, Zouloumis L. The maxillary labial fraenum - a controversy of oral surgeons vs .orthodontists. Balk J Stomatol 2012,16:141-6

[11] Akin R, Koes S. Studi kasus penatalaksanaan frenektomi dan depigmentasi gingiva pada regio anterior rahang atas anak perempuan usia 11 tahun. MKGK 2015, 1(1):5-8

[12] Thangavelu A, Elavarasu S, Jayapalan P. Pink esthetics in periodontics–gingival depigmentation: A case series. J Pharm Bioall Sci 2012, 4:186–90

[13] Gnanasagar WR. A comparative clinical study on gingival depigmentation technique using

scalpel and diode laser- a 6 [dissertation]. Chennai: The Tamilnadu Dr.M.G.R. Medical University, 2013.

[14] Wendy S, Djais AI. Perawatan perio-estetik dengan crown lengthening dan depigmentasi gingiva (laporan kasus). Makassar Dent J 2017,6(2): 59–65

[15] Rahma 2019, Penatalaksanaan frenektomi dan depigmentasi gingiva pada pasien preprostetik: laporan kasus Makassar Dent J 2019, 8(2): 83-86

[16] Kanakamedala AK, Geetha A, Ramakrishnan T, Emadi P. Management of gingival hyperpigmentation by the surgical scalpel technique-reportof three cases. Journal of Clinical and Diagnostic Research. 2010,4: 2341-2346

[17] Shah SS.Surgical esthetic correction for gingival pigmentation: Case series. J Interdiscip Dentistry.2012,2:195-200.

[18] Basir, Irmah, dan Hasanuddin Thahir, Treatment of labial frenal attachment and gingival hyperpigmentation in a 17-years-old patient Makassar Dental Journal 2020, 9(2): 110-113

[19] Newman, M. G., H.Tahei, H., Klokkevold, P. R. & Carranza, F. A. Newman and Carranza's Clinical Periodontology. *Elsevier.* 2019:918.

[20] Harpenau, L., Kao, R. T., Lundergan, W. P. & Sanz, M. *Hall's Critical Decisions in Periodontology and Dental Implantology*. BC Decker Inc., 2013: 218-19.

[21] Rakhewar PS, Patil HP, Thorat M. Identification of gingival pigmentation patterns and its correlation with skin color, gender and gingival phenotype in an Indian population. Indian J Multidiscip Dent [serial online] 2016 [cited 2021 Oct 17],6:87-92. Available from: https://www.ijmdent.com/text.asp?2016/6/2/87/197763