ATLANTIS PRESS
Advances in Health Sciences Research, volume 47
Proceedings of 1st International Conference on Health Sciences and Biotechnology (ICHB 2021)

Neurological Analysis of Brain Wave Disorders of Speech Delayed Child

Yulianita Yulianita[1*] , Rika Amran[2], Amrizal Arief [1]

[1]*Department of Public Health Faculty of Baiturrahmah University, Padang, West Sumatera*
[2] *Medical Faculty of Baiturrahmah University, Padang, West Sumatera*
**Corresponding Author, Email:* yulianita2478@gmail.com

ABSTRACT
The brain is the most important part of the control center of the human body. Inside the brain, millions of neurons coordinate in transferring electric signs to form orders. The signs are recorded as brain waves indicating normalities and abnormalities of brain work by using one of the brain recorders; Electroencephalograph (EEG). The research aimed to analyze brain waves work of speech delayed children based on lobes and areas function of the brain. For deeper analysis, the case study method of qualitative research was used. In conducting the research, some procedures were applied related to the EEG record. 17 electrodes were held on the scalp of area frontal, central, parietal, occipital, temporal, auricular or mastoid, vortex and electrode ground and connected to the computer as graphic data in form of Alpha, Betha, Theta and Delta. The object of the research was a three-year-old child diagnosed to suffer speech delay Based on the recorded result, the abnormalities occurred significantly for speech delayed children, especially in the left hemisphere as part of speech control. The frontal lobe, Parietal lobe and Temporal lobe were indicated to have brain wave delayed disorders related to personality, motoric sensory, expressive and responsive speech controls. Areas performed were FP1(concentration), FP2 (decision), F4 (planning), C3 (sensory integration), T3 (verbal memory), T5 (spelling). Brain wave delayed disorders for speech delayed children can be resolved by intensive stimulation and good nutrition.

Keywords: *neurological analysis, brain wave delayed disorders, speech delayed child*

1. INTRODUCTION

Every child may develop at a different own pace. When the child doesn't produce words as most children of the same age, the problem may be speech delay. A speech delay is when a child isn't developing speech at an expected rate. It's a common developmental problem that affects as many as 10% of preschool children [1] [2].

As a part of speech disorders in children, speech delays can be caused by organic disorders that interfere with several body systems such as the brain, hearing and other motor functions. Several studies have shown that the cause of speech disorders is a dominant hemisphere disorder. This deviation usually refers to the left hemisphere. Some children also found irregularities in the right hemisphere of the brain, corpus callosum and interconnected auditory pathways [3].

The brain is the most important part of the control center of the human body. Inside the brain, millions of neurons coordinate in transferring electric signs to form orders. The signs are recorded as brain waves indicating normalities and abnormalities of brain work by using one of the brain recorders; The electroencephalogram (EEG) remains the primary tool for diagnosis of abnormal brain activity in clinical neurology and for in vivo recordings of human neurophysiology in neuroscience research. The tool studies images of recorded electrical activity in the brain. The neurons in the cerebral cortex emit electrical waves with very small voltages (mV), which then make the EEG machinebe amplified, inconsequently, to record that are large enough to be captured by the EEG reader's eye as delta, alpha, beta, theta waves [4]. Mostly, EEG is used for recording abnormalities of brain waves for epilepsy, stroke, and seizure. In this research, speech delay was analyzed neuro diagnostically. Therefore, this tool can be used also to capture the brain waves figures of speech delay children that are correlated with personality, motoric sensory, expressive and responsive speech controls

There are some points of placing electrodes on scalp, correlated with brain functions as below [5]:

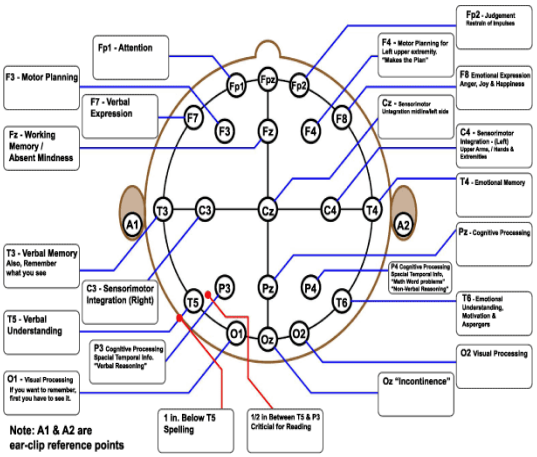

Figure 1 Placement points of EEG

The transformation of EEG signals into a model is a very effective way to help classify EEG signals, identify and estimate the spectrum of EEG signals. Frequency areas are significant, especially in the identification of waves in the brain ; (1) Alpha 8 – 13 Hz: Relax, eyes closed, (2) Beta > 14 Hz: Activity/thinking, (3) Teta 4 – 7 Hz: Light sleep/emotional stress, (4) Delta 0.5 – 3 Hz: Sleep well [6]. Below are the transformation of EEG signals of brain waves:

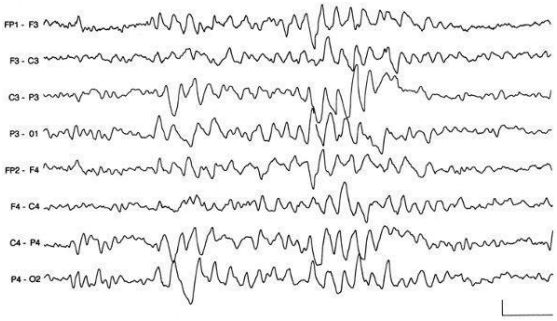

Figure 2 Brain Waves of Normal Children The waves indicates for normal children aged 3-5 years [7]. For speech delayed child, these waves were asssumed to be unsystematically.

2. METHOD

This was a descriptive qualitative research with a single case cross-sectional design with the purpose of analyzing the brain wave of speech delay child deeply. The subject in this research was a three-year-old child who suffered from speech delay. Primary data in this research were EEG images containing transformation signals of alpha, beta, theta dan delta of the child. The data were studied by using diagnostic analysis related to areas abnormalities in the brain, in accordance with dr. Hadril Busudin,Sp.S, MHA diagnosis. EEG recording was conducted in Integrated Diagnostic Installation Unit in RSUP M.Jamil Padang. In the recording process, the signals were transferred through the electrodes to the computer as graphic data displayed in the form of Alpha, Betha, Theta and Delta waves used minimum of 17 recording electrodes. All of these electrodes included frontal, central, parietal, occipital, temporal, auricular or mastoid areas, vortex and ground electrodes. The EEG machine calibrated at the beginning and at the end of the recording. Changes in device settings during recording were noted.

3. RESULT AND DISCUSSION

From the result of EEG record, following were the transformation signals. Abnormalities were indicated by circles.

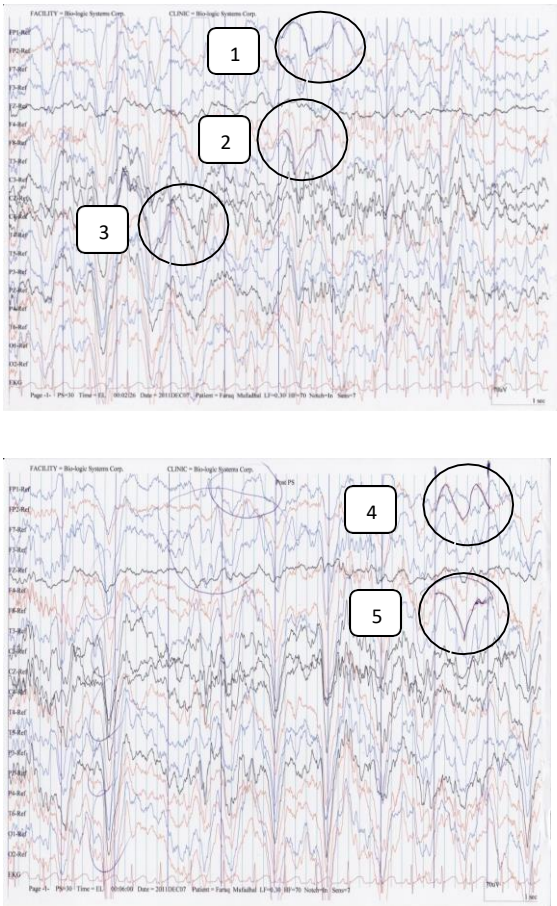

Figure 3 : EEG Images of Subject

Both hemispheres of the brain were recorded by this device. Odd numbers indicated the right hemisphere and even numbers for the left hemisphere. From the two pages of the EEG recording above, the circled area indicates delays occurred in the following areas:

I. Circles 1 and 4: Fp1 – Fp2

FP1 is an area associated with attention or concentration. FP2 is an area related to decision making. This showed that psychologically subject was slow in concentrating and paying attention to things. However, the waves that indicated this delay were considered as a mild abnormality and could be eliminated by training the child in games or lessons that require high concentration and make quick decisions.

II. Circles 2 and 5: F4 – C3

F4 is the area associated with planning motor and C3 is associated with sensory motor integration in the right hemisphere. This indicates that subject was a child who was slow to plan and to integrate his senses. This deceleration also looked mild because these were only found once in both recordings, or in other words, the deceleration waves were not continuous. Intensive exercise through games could also be done to reduce this delay.

III. Circle 3: T3 – Down T5

T3 corresponds to verbal memory and below T5 is the pronunciation area. Between the two areas are areas C3, Cz, C4, T4 and T5. C3 toC4 are areas of sensory motor integration, T4 are areas of emotional memory and T5 are areas of verbal comprehension. The wave shown was larger than some of the other waves indicating a delay. The complex delay occurred in these areas diagnosed as the main cause of speech delay for the subject. However, this delay was also not severe because the waves were still relatively small and had no continuity. This condition could be overcome with language therapy on the subject.

Based on the recording and the deceleration performed, the occurrence of areas indicated by even numbers were more than odd numbers. There was a tendency that the disorder was more likely to occur in the left hemisphere, which is the center of speech. The affected lobes were indicated by the following:

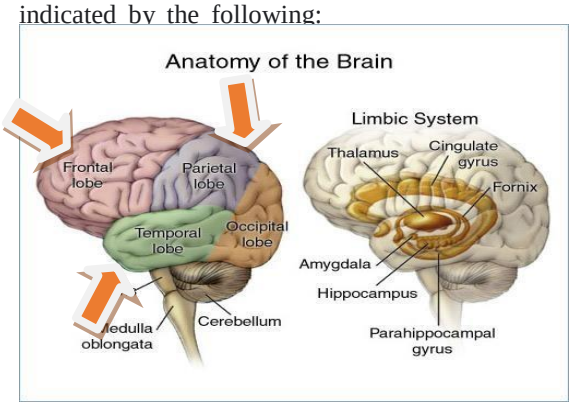

Figure 4 : Disordered Lobes in Subject's Brain

The frontal lobe is related to personality, the parietal lobe is related to the sensory motor which is the center of movement andsensibility, and the temporal lobe is related to the speech center of expression and reception. The disturbance occurred in these three lobes showed in the form of a delta wave slowdown on the EEG recording.

Comparing transformation EEG signals of normal children and the speech delay child performed a slight unsystematic wave. These indicated disorders suffered by speech delayed children. Therefore, intensive therapies and simultaneous exercises were needed for the treatment.

Nerve cells in the brain are basically plasticity, the ability of nerve cells to change and develop. Plasticity in children is higher than in parents. If there is a disturbance or minor damage unpermanently in children, then the chances of recovery are still possibly great. In addition, exercises or therapies provided can help accelerate the plasticity of the brain. Therefore, parents are expectedly not to be trapped by the perception that speech delays cannot be cured, in consequence, to feel hopeless. This perception is feared to lead to the wrong treatment of children and can cause interference or damage to get worse.

4. CONCLUSION

Some areas indicated delay, specifically in Fp1 (attention/concentration), F4 (planning motor), C3 (sensory motor), T3 (verbal memory), below T5 (pronunciation), Between the two areas are areas C3, Cz, C4, T4 and T5. C3 to C4 are areas of sensory motor integration, T4 are areas of emotional memory and T5 are areas of verbal comprehension.

The occurrence of areas indicated by even numbers were more than odd numbers. There was an tendency that the disorder commonly occurred in the left hemisphere, which is the center of speech.

Speech delay suffered by subject was a mild disturbance in the left hemisphere of the frontal, parietal, and temporal lobes. Of the three lobes, the temporal lobe had a greater slowing wave than the other lobes.

AUTHORS' CONTRIBUTIONS

1. Yulianita : The pilot reseacher, first author, presenter

2. Rika Amran : The second author, supporting clinical analysis

3. Amrizal Arief : The third author, supporting empirical analysis

ACKNOWLEDGMENTS

Greatful thanks addressed to the author team for the analysis. The most honourable acknowledgment are given to Dr. Gusdi Sastra, M.Hum (May rest in peace) and Prof. Dr. Jufrizal, MHum for the lingustic supervisions.

REFERENCES

[1] Sastra, Gusdi. Neurolinguistik; *Suatu Pengantar*. Bandung: Penerbit Alfabeta. 2011.

[2] Fieldman, Heidi.M. Evaluation andManagement of Language and SpeechDisorders in Preschool Children". American Academy of Pediatric. Pediatrics in Review 2005;26;131 *http://www.pedsinreview.aappublications.org.* DOI: 10.1542/pir.26-4-131. 2005.

[3] Obler, Loraine K. & Kris Gjerlow. Language and the Brain. UK: Cambridge University Press. 2006.

[4] Lepage, Kyle Q., Mark A. Kramer, and Catherine J. Chu. "A Statistically Robust EEG Re-Referencing Procedure to Mitigate Reference Effect." Journal of Neuroscience Methods 235.2014: 101–116. Journal of Neuroscience Methods. Web.

[5]Chudler, Eric. H. 10-20 Systems of Electrodes Placement; Neuroscience for Kids. https://faculty.washington.edu/chudler/1020.html. 2021

[6] Saby, Joni N, and Peter J Marshall. "The utility of EEG band power analysis in the study of infancy and early childhood." Developmental neuropsychology vol. 37,3. 2012: 253-73. DOI:10.1080/87565641.2011.614663

[7] "Normal EEG in children." ICNApedia. 23 Feb 2020, 17:28 UTC. 30 Oct 2021, 10:52 .https://icnapedia.org/wiki/content/normal_eeg_in_children?rev=1582478894.