ST-segment Elevation Myocardial Infarction with Left Ventricle Thrombus: Case Report

Doharjo Manullang[1](✉), Hadi Wijaya[2], Imran Soleh[1], Erwin Sukandi[1], and Taufik Indrajaya[1]

[1] Cardiovascular Division of Internal Medicine Department, Sriwijaya University, Mohamad Hoesin Hospital, Palembang, Indonesia
doharjomanullang19@gmail.com

[2] Internal Medicine Department, Sriwijaya University, Mohamad Hoesin Hospital, Palembang, Indonesia

Abstract. Acute myocardial infarction (AMI) occurs when there is evidence of myocardial injury (an increase in cardiac troponin values) and clinical evidence of myocardial ischemia. Data from the Jakarta Acute Coronary Syndrome Registry states that in 2014 there were 3015 patients with acute coronary syndrome (ACS); half of them were diagnosed with ST Elevation Myocardial Infarction (STEMI). Among patients with STEMI, 46% of cases did not receive reperfusion therapy. This case report aimed to describe the features, complications and management of ST segment elevation with left ventricular thrombus. A 44-year-old male patient came with complaints of chest pain that had been experienced for 8 h before entering hospital. The chest pain did not decrease with rest and radiated to the back of the chest. The patient is a heavy smoker and during electrocardiographic examination, ST elevation was found in leads V1-4. It was decided to perform primary percutaneous coronary intervention, but failed due to administrative matters. The patient, therefore, received Loading Aspilet 160 mg chewable, loading Ticagrelor 180 mg orally, Isosorbide dinitrate 5 mg Sublingual, repeated up to 3 times every 5 min, Glyceryl trinitrate 2 × 5 mg orally, Morphine 2 mg intravenously (after isosorbide dinitrate does not respond), Bisoprolol 1 × 2.5 mg orally, Atorvastatin 1 × 40 mg orally, Laxadyn syrup 3 × 10cc orally, Fibrinolytic with streptokinase 1.5 million units intravenous drip then followed by Injection enoxaparin 0.6 cc/12 h (for 5 days). After administering a streptokinase injection, a repeat electrocardiographic examination was performed and found a decrease in ST elevation in leads V1-4. Clinically, the chest pain began to decrease. The patient underwent echocardiography for the first time on 6 December, 2019 with Interpretation results: Segmental Wall motion abnormality at the apex, LV size: normal, LV muscle thickness: thickened, LV Function, normal diastolic function, normal systolic function, EF = 52%, VALVE, Mild mitral regurgitation. Further, a percutaneous coronary intervention was performed on December 11, 2019 The results are as follows: LAD: 70% eccentric proximal, LAD: 70% eccentric Middle, LCX: 50% eccentric proximal RCA: 60% concentric proximal, RCA: 50% proximal. After completing the coronary intervention, on 10 January 2019 patient was evaluated for echocardiography: segmental wall motion Abnormality at the EF apex 40%, Mild Mitral Regurgitation, Mild Tricuspid regurgitation, Mild Pulmonary Hypertension Thrombus at the apex size 1.69 cm × 3.5 cm. After finding

H. Nurdiyanto et al. (Eds.): ICCvD 2021, AHSR 52, pp. 183–190, 2023.
https://doi.org/10.2991/978-94-6463-048-0_21

a thrombus with echocardiographic evaluation, the patient was discharged with aspirin, clopidogrel, nitrate and atorvastatin. A few months later, echocardiography was repeated and the thrombus was no longer found at the apex of the left ventricle. This case report emphasizes the importance of optimal treatment of AMI cases with segment elevation to avoid heart failure and thrombus formation.

Keywords: Acute Myocard Infarct · Syntrom · Thrombus

1 Introduction

Acute myocardial infarction (AMI) is used when there is evidence of myocardial injury (there is an increase in cardiac troponin values) with clinical evidence consistent with myocardial ischemia. In European countries, especially Sweden, ST elevation myocardial infarction found 58/100,000 cases in 2015 while in other European countries the incidence was around 43-144/100,000 per year. Whereas in the USA the incidence of ST elevation myocardial infarction decreased from 133 cases in 1999 to 50/100,000 cases in 2008 while the cases of Non ST elevation myocardial infarction remained or slightly increased. And in general, ST elevation myocardial cases are more common in young people than in old age and are generally more common in men than women [1–3].

Based on data, the incidence, morbidity, and mortality of infarction myocardium in Indonesia is limited. However, nationally there is a 1.5% prevalence coronary heart disease (CHD) diagnosed by a doctor according to Health Research Base 2018 where the highest prevalence in the province of Kalimantan North, Gorontalo, Central Sulawesi, Yogyakarta, and DKI Jakarta [3]. Data from the Jakarta Acute Coronary Syndrome Registry states that in October 2014-July 2015, data in the emergency department from 56 health centers in Jakarta, there are 3015 patients with acute coronary syndrome (ACS), of which 1024 patients were diagnosed with ST Elevation Myocardial Infarction (STEMI). Of the patients with STEMI, as many as 46% of cases did not receive reperfusion therapy. As many as 61% of cases of patients who did not reperfusion occurs 12 h after the onset of the attack [4].

The most common complication in acute myocardial infarction is thromboembolic events that cause thrombus formation in the left ventricle, generally occurring in the first 3 months after acute myocardial infarction and there are some opinions that it occurs around 1–2 weeks (average 5–6 weeks). Day). In addition, the formation of a thrombus in the left ventricle can also be caused by akinetic or dyskinetic effects on the heart wall accompanied by an ejection fraction of 40% and accompanied by blockage of blood vessels in several places (multiple vessel disease). And one of the treatments for thrombus in the left ventricle is the administration of vitamin K antagonist drugs [5, 6]. A study conducted in a meta-analysis stated that oral administration of anticoagulants in this case vitamin K antagonists can reduce embolic complications. And based on these data the European Society of Cardiologists (ESC) and the American Heart Association (AHA) recommend vitamin K antagonist therapy in patients with left ventricular thrombus after myocardial infarction. Vitamin K Antagonist drugs are recommended for thromboembolic disease [7, 8].

2 Method

A male 44-year-old patient came with complaints of chest pain that had been experienced since 8 h before entering Muhammad Hoesin Hospital where the chest pain did not decrease with rest and the pain radiated to the back of the chest. Physical examination: BP 100/60 mmHg, HR 96 x/minute, RR 24 x/minute, normal weight. Laboratorium finding: hemoglobin 13,8 g/dL, Leucosyt 8900/mm^3, trombosit 243.000/μl, Ureum 21 mg/dL, creatinine 0,70 mg/dL, Cholesterol total 181 mg/dL, High Density Lipoprotein 29 mg/dL, Low Density Lipoproten 109 mg/dL, Triglycerida 105 mg/dL Troponin T 662 ng/L Blood Glucose adrandom 95 mg/dL, troponin T 662 ng//L, LDL 109 mg/dL. Chest X-ray: cardiomegaly (Fig. 1). The patient is a heavy smoker and during electrocardiographic examination, ST elevation was found in leads V1-4 (Fig. 2) and it was decided to perform primary percutaneous coronary intervention, but since the patient was constrained by administrative problems, the patient was decided to do Loading Aspilet 160 mg chewable, loading Ticagrelor 180 mg orally, Isorbide dinitrate 5 mg Sub-lingual, repeated up to 3 times every 5 min, Glyceryl trinitrate 2 × 5 mg orally, Morphine 2 mg intravenously (after isosorbide dinitrate does not respond), Bisoprolol 1 × 2.5 mg orally, Atorvastatin 1 × 40 mg orally, Laxadyn syrup 3 × 10cc orally, Fibrinolytic with streptokinase 1.5 million units intravenous drip then followed by Inj enoxapharin 0.6 cc/12 h (for 5 days).

After administering a streptokinase inj, a repeat electrocardiographic examination was performed and found a decrease in ST elevation in leads V1-4 (Fig. 3) and clinically, the patient's chest pain began to decrease.

The patient underwent echocardiography for the first time on December 6, 2019 with Interpretation results: Segmental Wall motion abnormality at the apex, LV size: normal, LV muscle thickness: thickened, LV Function, normal diastolic function, normal systolic function, EF = 52%, VALVE, Mild mitral regurgitation (Fig. 4).

The subsequent percutaneous coronary intervention was performed on December 11, 2019 with the results of LAD: 70% eccentric proximal, LAD: 70% eccentric Middle, LCX: 50% eccentric proximal RCA: 60% concentric proximal, RCA: 50% proximal (Fig. 5).

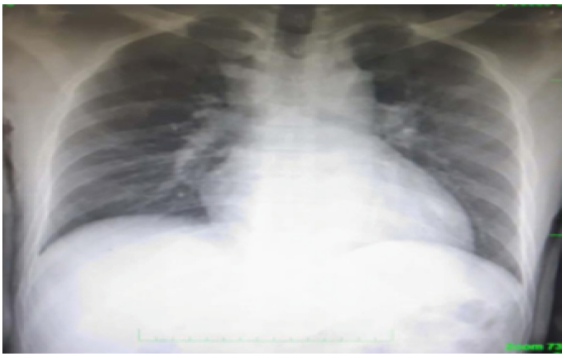

Fig. 1. Thorax Foto: Cardiomegaly

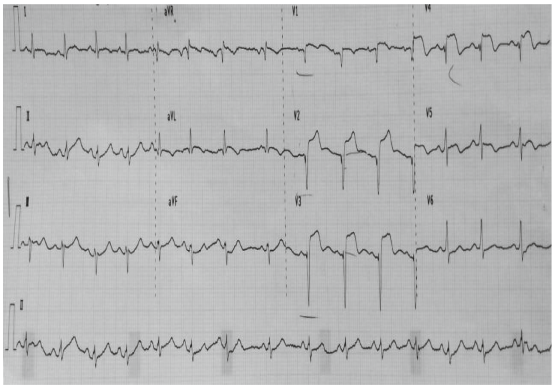

Fig. 2. ECG Pre Thrombolytic

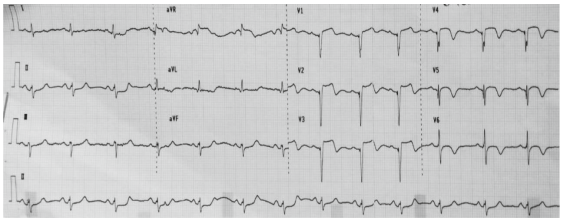

Fig. 3. ECG post Thrombolytic

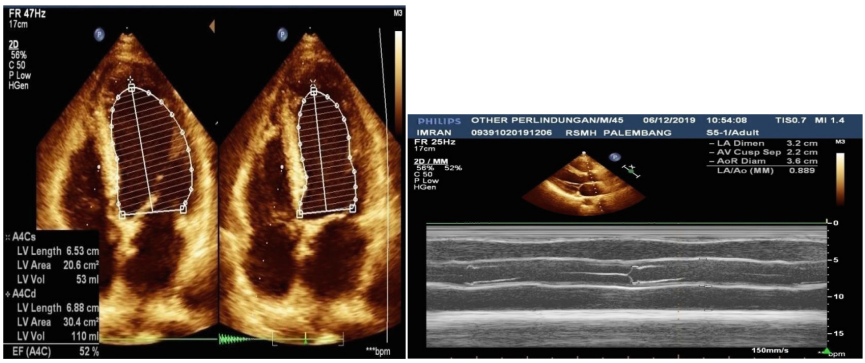

Fig. 4. Echocardiography precorangiography.

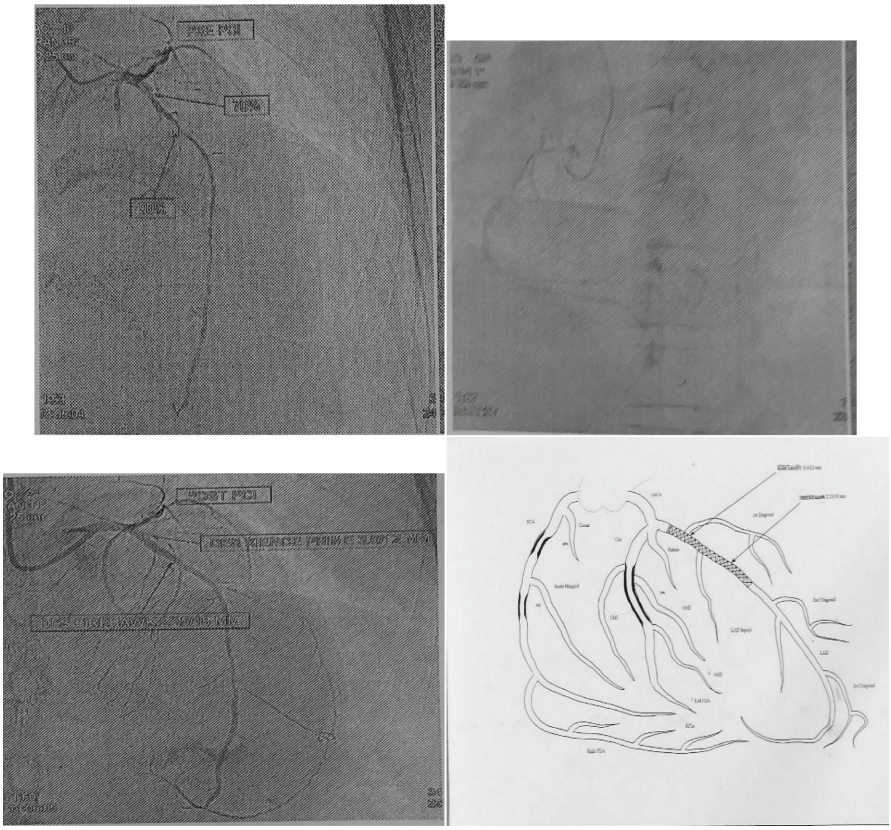

Fig. 5. Corangiography and corangioplasty

After completing the coronary intervention, on 10-01-2021 the patient was evaluated for echocardiography with the impression of Interpretation: Segmental Wall Motion Abnormality at the EF apex 40%, Mild Mitral Regurgitation, Mild Tricuspid regurgitation, Mild Pulmonary Hypertension Thrombus at the apex size 1.69 cm × 3.5 cm (Fig. 6).

After finding a thrombus on echocardiographic evaluation, the patient was discharged with syntrom drugs and dual antiplatelet drugs, namely aspirin, clopidogrel, nitrate and atorvastatin. And after taking the syntrom drug a few months later, echocardiography was repeated and it turned out that the thrombus was no longer found at the apex of the left ventricle (Fig. 7).

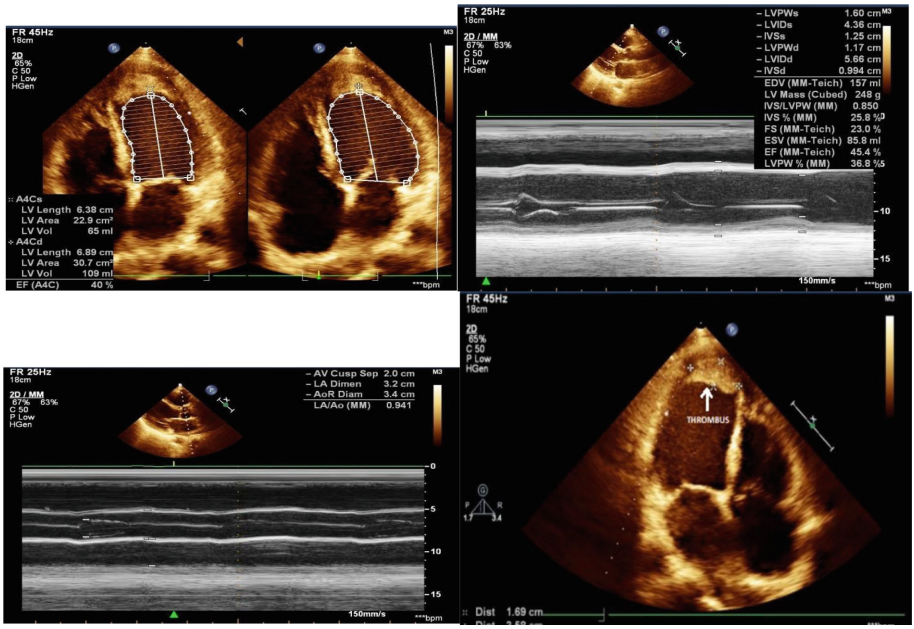

Fig. 6. Evaluation of echocardigraphy Post Corangiography.

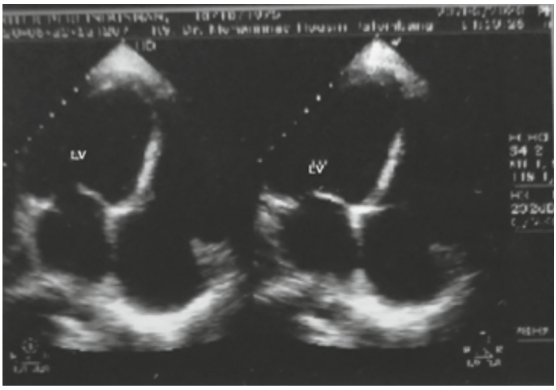

Fig. 7. Evaluation of echocardigraphy Post giving sintrom

3 Result and Discussion

Discussion

We report that a 44-year-old man presented with chest pain 8 h before arriving at the hospital, when he arrived at the hospital a blood test was performed and found elevated LDL and elevated Troponin T. The ECG examination found an increase in the segment in leads V1-4 and it was decided to do a Primary Percutaneous Coronary Intervention, but because of administrative problems the procedure was postponed and performed for

fibrinolytic action. After completion of the fibrinolytic procedure, the administration of enoxapharin was continued for 5 days and an echocardiographic examination was performed with a hypokinetic wall motion effect at the apex of the left ventricle with an ejection fraction of 52%. And after that, an elective percutaneous coronary intervention was performed. A few days later, echocardiography was repeated and found a thrombus at the apex with an ejection fraction of 40% (Simpson's method). After finding a thrombus on echocardiography examination, the patient was discharged with dual antiplatelet drugs, atorvastatin, Nitrocad retard, lansoprazole and syntrom. Increased ST segment myocardial infarction often occurs in young men compared to women where the most common complication of post myocardial infarction is the formation of a thrombus in the left ventricle which can occur in the first 3 months after post infarction. Thrombus occurs in the part of the heart wall that experiences akinetic or dyskinetic contraction movements and the part that often experiences movement disorders is at the apex. In addition, the incidence of thrombus is often found in patients with ejection fraction 40%. And one of the treatment for thrombus in the left ventricle is the Acenocoumarol (Vitamin K Antagonist) class where syntrom (Acenocoumarol) is a vitamin K antagonist drug class recommended in the treatment of thrombus in the left ventricle [5, 6].

4 Conclusion

Left ventricular thrombus is a complication that often occurs after acute myocardial infarction which can cause cerebral embolism. Giving syntrom (acenocoumarol) is one of the recommended treatments in the treatment of thrombus in the left ventricle.

Acknowledgment. I would like to express our deep gratitude to Dr Hadi Wijaya, Dr. Imran Soleh, Dr. Erwin Sukandi Dr. Taufik Indrajaya who has helped me in completing this case report and provided constructive input so that this case report becomes even better.

References

1. Thygesen, Kristian, Alpert, Joseph, dkk., Fourth Universal Definition of Myocardial Infarction, ESC/ACC/AHA/WHF Expert Consensus, 2018.
2. Ibanez Borja, James Stefan, Agewal Stefan et al. 2017 ESC Guidelines for the management of acute myocardial infarction in patients presenting with ST-segment elevation. European Heart Journal (2017) 00, 1–66.
3. Kementerian Kesehatan Republik Indonesia RI (2019). Riset Kesehatan Dasar 2018. Jakarta Badan Penelitian dan Pengembangan Kementerian kesehatan Indonesia .Republik Indonesia.
4. Dharma S, Andriantoro H, Rao S, dkk. Characteristics, treatment and in-hospital outcomes of patients with STEMI in a metropolitan area of a developing country: an initial report of the extended Jakarta Acute Coronary Syndrome registry, BMJ Open.2016; 6(9):e012193corr1.
5. Delewi R, Zijlstra F, Piek JJ. Left ventricular thrombus formation after acute myocardial infarction. Heart 2012; 98:1743–1749.
6. Potu CR, Reid EE T, Baugh DS, Madu EC. Left Ventricular thrombus in patients with acute myocardial infarction: case report and caribbean focused update. AMJ 2012, 5, 3, 178–183.

7. Trailokya A. Acenocoumarol in Thromboembolic Disorders. Trailokya Cardiovasc Pharm Open acces 2015, 4:4
8. Prescribing Information Sintrom 1mg and 4 mg, Oral Anticoagulant. Paladin Labs Inc. Date of Preparation: May 22, 2009.