Imaging Technology of CT Scan 128 Slice for Pulmonary Hypertension, Mitral Stenosis, Emphysema, and Pleural Effusion: Case Report

Lilik Lestari(✉)

Lung Hospital Dr. Ario Wirawan, Salatiga, Indonesia
liliklestarirspaw@gmail.com

Abstract. CT Scan 128 Slice can produce excellent images with good contrast and low radiation dose. Pulmonary hypertension CT Scan is able to imaging central arterial dilatation, while mitral stenosis on CT Scan 128 Slice imaging can be seen as well. The purpose of this paper is to report the diagnosis of patients with pulmonary hypertension, mitral stenosis, emphysematous, and pleural effusion using a CT scan of 128 slices. A case report of a 50 years old man with complaints of shortness of breath and cough, arrived to the CT Scan section of the lung hospital dr. Ario Wirawan to conduct a 128 Slice Chest CT Scan. The patient underwent a CT scan on chest with pre-contrast and post-contrast. Post-contrast of the patient is conducted by injection of non-ionic contrast, then pre-contrast lung window, pre-contrast mediastinum window, post-contrast lung window, and post-contrast mediastinum window were performed. The 128 slice CT scan technique was performed on the axial, coronal, and sagittal sections. At the time of contrast, the patient is injected with a non-ionic contrast drug. The result was expertise by a radiologist. The results of CT Scan 128 showed pulmonary artery dilatation, multiple calcifications of the mitral valve, diffuse centrilobular emphysema, and right pleural effusion. The results of this study portray that a thorax CT scan is capable of imaging patients with pulmonary hypertension, mitral stenosis, emphysema, pleural.

Keywords: Mitral Stenosis · Pulmonary Hypertension · Centrilobular Emphysema · Pleural Effusion

1 Introduction

The use of Computed Tomographic (CT) multi-slide is very broad because the radiation dose is low. Currently, the Multi-Slice 64 CT Scan can be used for CT radiography, while the 128 Slice Dual Source CT Scan (DSCT) is a better prospect because it used a very high spiral speed compared to the 64 Slice CT Scan. Radiation CT Scan Slice 128 is lower when compared to CT Scan 64 Slice [1]. A CT Scan with slice technology, the higher the radiation dose, the lower the radiation effect. This is because shorter time spent in irradiating [2].

H. Nurdiyanto et al. (Eds.): ICCvD 2021, AHSR 52, pp. 400–405, 2023.
https://doi.org/10.2991/978-94-6463-048-0_47

Pulmonary hypertension (PH) results in hemodynamic and vascular pathophysiological changes of the lungs which is a complex clinical condition [3]. PH can be caused by idiopathic or other clinical disease conditions characterized by increased pressure in the pulmonary circulation [4]. Idiopathic PH that affects the pulmonary circulation in the lungs is called primary pulmonary hypertension [5].

Magnetic Resonance Imaging (MRI) and Computed Tomography (CT) are helpful to establish the diagnosis and pathophysiology of pulmonary hypertension. Imaging plays an important role in the diagnosis of all forms of pulmonary hypertension and it is useful in the patient management [6]. The use of CT and MR imaging is increasing as well as awareness of CT and MR images of the mitral valve. Recent studies have enabled cardiac MD CT to provide high-quality valve imaging.[7] Technological advances have improved evaluation of mitral disease by computed tomography (CT) and magnetic resonance imaging (MRI) although echocardiography is the main non-invasive modality for visualizing the mitral valve echocardiography [7].

Mitral valve disease is the most common heart valve disorder affecting nearly 10 percentages of elderly people over 75 years [8]. Centriacinar or proximal is a preferential loss of alveolar septa in the center of the pulmonary acini and lung lobules, which are associated with the respiratory bronchioles [9]. Pulmonary emphysema is a chronic obstructive pulmonary disease characterized by damage to the lung parenchyma. Centrilobular emphysema usually affects the upper part of the lung in the apical and posterior segments of the upper or superior lower lobes [10].

Centrilobular emphysema (CLE) is common and strongly associated with cigarette smoking. The severity of emphysema correlated with length of time and amount a patient has smoked. Smoke indices lung destruction by causing chronic inflammation in and around small air ways [11].

2 Method

A 50-year-old male patient came to the hospital to conduct a CT Scan in Ario Wirawan Lung Hospital, Salatiga. Patient has history of smoking, and he has a complaint of shortness of breath. The patient underwent a CT scan on chest with pre-contrast and post-contrast. Post-contrast of patient is conducted by injection of non-ionic contrast, then pre-contrast lung window, pre-contrast mediastinum window, post-contrast lung window, and post-contrast mediastinum window were performed. The 128 slice CT scan technique was performed on the axial, coronal, and digital sections. At the time of contrast, the patient is injected with a non-ionic contrast drug.

3 Result and Discussion

The results of CT Scan Chest 128 Slice of the patient as shown in Figs. 1, 2, 3 and 4 found: pleural effusion (a), (b); pulmonary hypertension (c); emphysema centrilobular (d); centrilobular (e); pleural effusion (f); left atrium dilatation (g); multiple calcification (h); pleural effusion (i), (j), (k); emphysema centrilobular (l); aorta (m). The results of a 128 slice CT scan found multiple classifications in the mitral valve which resulted in mitral stenosis. Imaging results on the mitral valve revealed a dilated left atrium caused

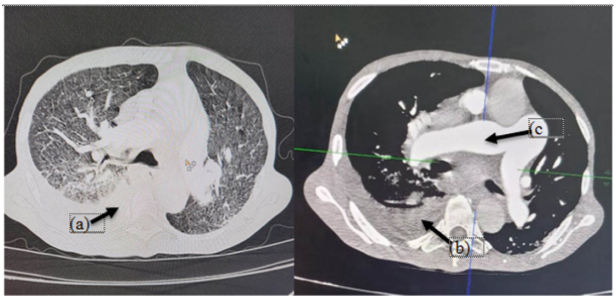

Fig. 1. Pleural effusion (a), (b), pulmonary hypertension (c).

by mitral stenosis. The 128 slice CT scan in this case report also found a right pleural effusion, whereas a left pleural effusion was not found. This can be seen on pre-contrast and post-contrast CT scans, as well as on lung and mediastina window techniques.

The results of a 128 slice CT scan showed emphysema of the type of central lobular emphysema. This is indicated by the finding of a small area of uniformly distributed (diffuse) centrilobular with low attenuation with unclear boundaries. Central lobular emphysema is a progressive lung disease. Emphysema as a form of Chronic Obstructive Pulmonary Disease (COPD) is characterized by difficulty in exhaling. This is in accordance with the condition of patients who experience shortness of breath repeatedly and have a history of smoking. Dose using this technique may be as low as 0.02 mSv to 0.2 mSv.

Pulmonary hypertension in this case report can be caused by narrowing of the small pulmonary arteries (arterioles) and narrowed capillaries. This situation causes blood to flow from the right side of the heart to be disrupted.

Based on the results of the study, it can be seen that the 128 Slice CT Scan is a CT Scan with multiple detectors. The higher the technology used in CT Scan, the better the resulting image. CT Scan, the higher the slice, the lower the radiation obtained.

The accurate interpretation of high resolution CT Scan in patient with lung disease is fundamentally based on high resolution CT Scan. The primary role of high resolution CT Scan is in the identification of specific abnormalities that allow a characterization of diffuse lung disease. High resolution CT Scan using variable mA of about 100. Radiation dose is directly related to the mA choice. Decreased radiation dose is associate with increased image noise and decreased resolution.

Emphysema reflects lung destruction that may be the end result of several different processor including cigarette smoking, enzyme deficiency, and drug abuse. Emphysema is categorized by the part of the secondary pulmonary lobule that is involved as centrilobular, panbular or paraseptal.

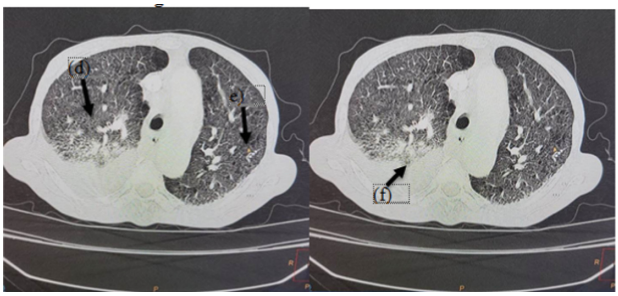

Fig. 2. Emphysema centrilobular (d), emphysema (e), pleural effusion (f).

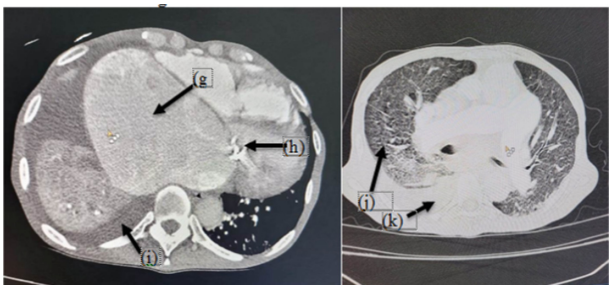

Fig. 3. Left atrium dilatation (g), multiple calcification (h), pleural effusion (i), (j), emphysema (k).

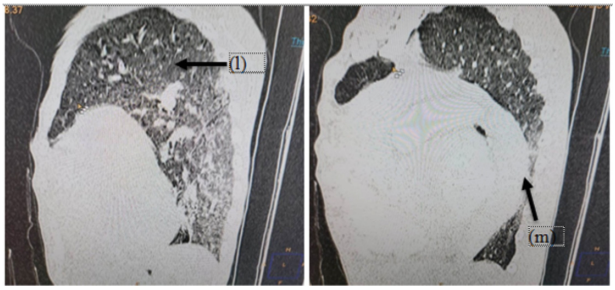

Fig. 4. Emphysema centrilobular (l), aorta (m).

4 Conclusion

Imaging technology CT Scan 128 Slice can diagnose pulmonary hypertension, mitral stenosis, central lobular emphysema, and pleural effusion. In diagnosing disease, CT Scan meets the standard examinations, namely: axial, coronal, and sagittal. This is to complement each other in establishing the diagnosis of a disease. The more advanced the technology used in CT Scan, the better the resulting image. CT Scan, the higher the slice, the lower the radiation obtained.

Acknowledgment. The author thanks all workers in the CT Scan section of the lung hospital dr. Ario Wirawan for their contribution to this study. We also thank the head of the lung hospital dr. Ario Wirawan and staff for valuable support during the study.

Author's Contribution. LL planned the study design, the data collection, analysed, interpreted the findings, wrote and organized the manuscript, and the manuscript review.

References

1. J. R. Ghadri, S. M. Küest, R. Goetti, M. Fiechter, A. P. Pazhenkottil, R. N. Nkoulou, et al., "Image quality and radiation dose comparison of prospectively triggered low-dose CCTA: 128-slice dual-source high-pitch spiral versus 64-slice single-source sequential acquisition," The international journal of cardiovascular imaging, vol. 28, pp. 1217-1225, 2012.
2. P. Purwatiningsi and H. E. Prasetio, "Analisis Sebaran Radiasi Hambur Ct Scan 128 Slice Terhadap Pemeriksaan Ct Brain," Sainstek: Jurnal Sains dan Teknologi, vol. 8, pp. 50–55, 2017.
3. E. Altschul, M. Remy-Jardin, S. Machnicki, R. Sulica, J. A. Moore, A. Singh, et al., "Imaging of Pulmonary Hypertension: Pictorial Essay," Chest, vol. 156, pp. 211–227, 2019/08/01/ 2019.
4. F. Aluja Jaramillo, F. R. Gutierrez, F. G. Díaz Telli, S. Yevenes Aravena, C. Javidan-Nejad, and S. Bhalla, "Approach to pulmonary hypertension: from CT to clinical diagnosis," Radiographics, vol. 38, pp. 357–373, 2018.
5. A. Resten, S. Maitre, M. Humbert, A. Rabiller, O. Sitbon, F. Capron, et al., "Pulmonary hypertension: CT of the chest in pulmonary venoocclusive disease," American Journal of Roentgenology, vol. 183, pp. 65-70, 2004.
6. B. H. Freed, J. D. Collins, C. J. François, A. J. Barker, M. J. Cuttica, N. C. Chesler, et al., "MR and CT imaging for the evaluation of pulmonary hypertension," JACC: Cardiovascular Imaging, vol. 9, pp. 715–732, 2016.
7. M. F. Morris, J. J. Maleszewski, R. M. Suri, H. M. Burkhart, T. A. Foley, C. R. Bonnichsen, et al., "CT and MR imaging of the mitral valve: radiologic-pathologic correlation," Radiographics, vol. 30, pp. 1603-1620, 2010.
8. J. R. Weir-McCall, P. Blanke, C. Naoum, V. Delgado, J. J. Bax, and J. Leipsic, "Mitral valve imaging with CT: relationship with transcatheter mitral valve interventions," Radiology, vol. 288, pp. 638-655, 2018.
9. Y. Sharma, P. Bansal, S. Saran, and S. R. Verma, "Clinical and Radiological Evaluation of Emphysematous Chest-A Prospective Study."
10. S. Jonathan, T. Damayanti, and B. Antariksa, "Pathophysiology of Emphysema," Jurnal Respirologi Indonesia, vol. 39, pp. 60-69, 2019.
11. B. M. Elicker and W. R. Webb, Fundamentals of High-Resolution Lung CT: Common Findings, Common Patterns, Common Diseases, and Differential Diagnosis 1st Edition: Wolters Kluwer Health/Lippincott Williams and Wilkins, 2013.