Secundum Atrial Septal Defect Severe Pulmonary Hypertension in Pregnancy: A Case Report

Welly Oktaviandani[1](✉), Nuswil Bernolian[2], Imran Soleh[1], Andi Wahyudi[3], Ahmat Umar[4], Ali Ghanie[1], Fredi Heru Irwanto[5], Erwin Sukandi[1], and Taufik Indrajaya[1]

[1] Cardiovascular Division of Internal Medicine Department of Sriwijaya University, Mohammad Hoesin Hospital, Palembang, Indonesia
oktaviandaniwelly@yahoo.co.id
[2] Obstetrics and Gynaecology Department of Sriwijaya University, Mohammad Hoesin Hospital, Palembang, Indonesia
[3] Internal Medicine Department of Sriwijaya University, Mohammad Hoesin Hospital, Palembang, Indonesia
[4] Thoracic and Cardiovascular Surgery Division of Surgery Department of Sriwijaya University, Mohammad Hoesin Hospital, Palembang, Indonesia
[5] Anesthesiology and Intensive Therapy Department of Sriwijaya University, Mohammad Hoesin Hospital, Palembang, Indonesia

Abstract. Atrial septal defect (ASD) is the most common form of congenital heart disease. Left-to-right shunting leads to right ventricular (RV) volume overload with excessive pulmonary blood flow. In the absence of pulmonary hypertension, pregnancy is generally well tolerated in the setting of an ASD. This case report aimed to describe the features and the multidisciplinary approach management in secundum ASD, severe pulmonary hypertension in pregnancy. A 31 years old woman, pregnant with her second child at 35 weeks gestational age came with a primary complaint of increased shortness of breath a day before being admitted to the hospital. Three months before being admitted to the hospital she complained of shortness of breath when walking ± 20 m. The complaint was felt when her pregnancy was 23 weeks. The shortness of breath got worse with increasing gestational age. She suspected she had a heart problem. The first child was born in 2013, 33 weeks gestational age, spontaneously, weighing 1400 g. Specific examination revealed a pan systolic murmur, maximum punctum ICS 2–3 left parasternal, grade 5/6, spreading medially, wide fixed splitting S2. Echocardiography found right atrial dilatation, interatrial septal defect left to right shunt, severe tricuspid regurgitation, severe pulmonary hypertension, and ejection fraction 73%. The patient had pregnancy termination, right heart catheterization and surgical closure. The patient has clinical improvement without any complications. In conclusion, pregnancy remains contraindicated in patients with ASDs associated with severe pulmonary hypertension due to poor maternal and fetal outcomes. Cardiology follow up during pregnancy should be adapted to clinical symptoms. Pulmonary hypertension associated with an ASD is associated with high morbidity and mortality. Patients should be monitored closely and specialized by a multidisciplinary team approach to achieve optimum outcomes.

H. Nurdiyanto et al. (Eds.): ICCvD 2021, AHSR 52, pp. 308–314, 2023.
https://doi.org/10.2991/978-94-6463-048-0_35

Keywords: Atrial septal defect · pulmonary hypertension · congenital heart disease · surgical closure

1 Introduction

Atrial septal defect (ASD) is characterized by a defect at the atrial level that allows pulmonary venous return to enter the right atrium directly. It is the most prevalent type of congenital heart disease (13% of all congenital heart defects) and one of the most commonly recognized congenital cardiac anomalies in adulthood [1, 2]. There are four types of ASDs: ostium secundum (75% of cases), ostium primum (15–20% of cases), and sinus venosus (5–10% of cases), and less commonly, an unroofed coronary sinus [3]. Pulmonary hypertension is a relatively common complication of congenital heart disease, with adult prevalence between 5 and 10% [4]. Atrial septal defect (ASD) is one of the most frequent CHDs also in pregnant women. Pregnancy is associated with additional volume loading, producing a circulatory burden that consequently aggravates the right ventricular volume overload caused by defects [5]. In the absence of pulmonary hypertension, pregnancy is generally well- tolerated in the setting of an ASD. Nevertheless, hemodynamic changes throughout gestation may increase the risk for complications, particularly in those with unrepaired ASDs. Cardiology follow up during pregnancy should be adapted to clinical circumstances and includes transthoracic echocardiography during the second trimester and arrhythmia monitoring in the event of symptoms [1].

2 Case

A 31 years old woman came to the emergency department with a main complaint: shortness of breath since a day before admission. Three months before admission, she complained of shortness of breath when walking ±20 m and doing daily household work. Shortness of breath relieved by rest. Sometimes shortness of breath was felt when lying down. The complaint was felt when her second pregnancy was 23 weeks. The patient checked her womb at the midwife and was given supplementation every month. About two weeks before being admitted, the patient complained of shortness of breath getting worse, especially when doing light activities and increasing gestational age. The patient came to gynecology, and an ultrasound examination was performed. Ultrasound examination results showed the baby was healthy but low weight and suspected heart disease. An internist consulted the patient with an internist, and echocardiography was performed. Echocardiography revealed congenital heart disease. The patient got medicine and recommended a daily check to gynecology and internist sub cardiovascular for observation and evaluation of pregnancy and heart conditions.

A day before being admitted, the patient complained of shortness of breath getting worse. Patient planned termination and management of congenital heart disease. Physical examination revealed blood pressure 110/70 mmHg, pulse 104 x/m regular, respiratory rate 26 x/m. Specific examination revealed murmur pansistolik, maximum punctum at ICS 2–3 left parasternal, grade 5/6, spreading medially, gallop (-), wide fixed

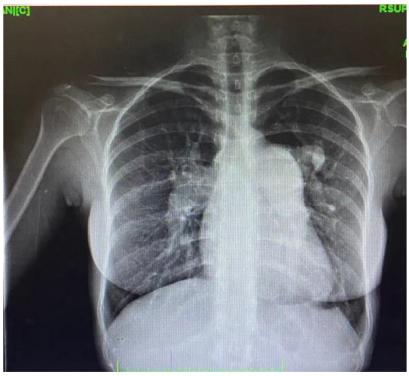

Fig. 1. Chest x-ray showed pulmonal hypertension.

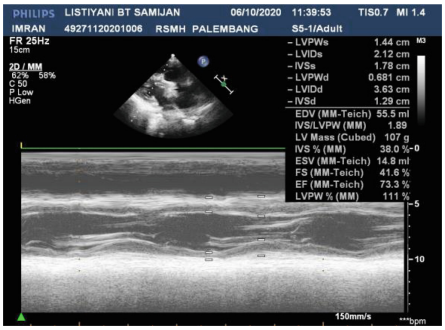

Fig. 2. Echocardiography showed global normokinetik, left ventrikel hypertrophy, ejection fraction 73, 3%.

splitting S2. Obstetric gynaecologist examination revealed fundus uteri 1/2 umbilicus - processus xiphoideus (24 cm), elongate, right back presentation, head position, his (–), U 5/5, fetal heart rate 142 x/min, estimated foetal weight 1705 g. Inspection and VT were not done. The results of laboratory tests are normal. The electrocardiogram results were sinus, incomplete RBBB, right axis deviation, right ventricular hypertrophy, right atrial enlargement, left atrial enlargement, ischemic anteroseptal inferiority. Chest x-ray revealed pulmonary hypertension (Fig. 1). Echocardiography examination was global normokinetic, right atrial and right ventricular dilatation, severe tricuspid regurgitation/ pulmonary regurgitation, ejection fraction 73%, interatrial septal defect (+) with left to right shunt, severe pulmonary hypertension (Figs. 2, 3, 4, 5, 6). The echocardiography result was secundum ASD and severe pulmonary hypertension. Obstetric ultrasonography examination showed 33 weeks live single fetus, head presentation, increasing umbilical arterial resistente, suspected intrauterine growth restriction. The patient was managed, and the pregnancy was terminated with a surgical procedure. The neonatus is alive, female, weighing 1800 g, body length 42 cm, head circumference 30 cm. After the placenta was complete, tubal ligation was performed. Six months after pregnancy termination, right heart catheterization was performed for preparation of ASD closure.

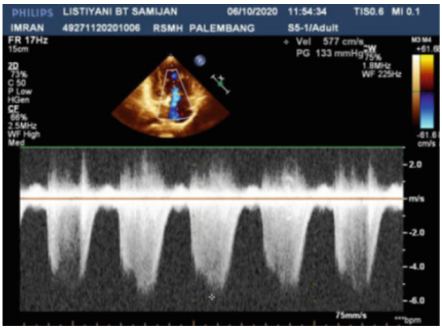

Fig. 3. Echocardiography showed tricuspid regugitation with pressure gradient 133 mmHg

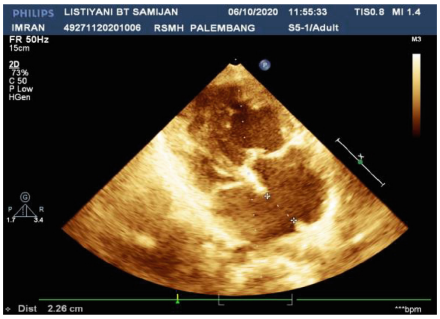

Fig. 4. Echocardiography showed right ventricle dilatation, right atrial dilatation, atrial septal defect.

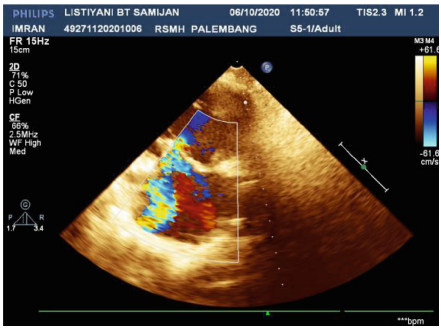

Fig. 5. Echocardiography showed pulmonal regurgitation.

After ASD closure, complaints of shortness of breath significantly reduced. There was an improvement in pulmonary hypertension. In addition, echocardiography showed improvement of ejection fraction and pressure gradient of tricuspid regurgitation 133 mmHg to 73 mmHg. (Fig. 7, 8).

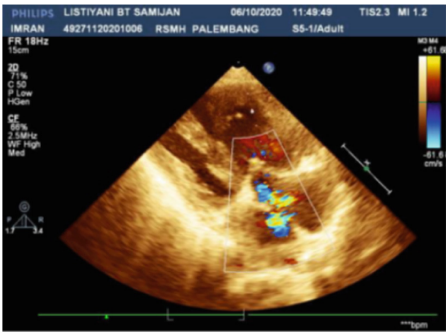

Fig. 6. Echocardiography showed atrialseptal defect left to rght shunt.

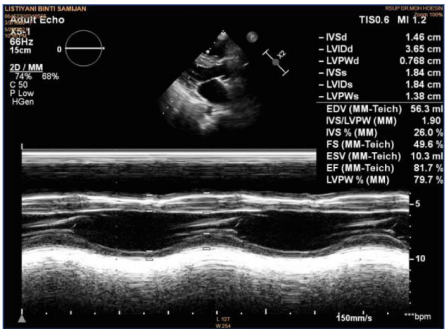

Fig. 7. Echocardiography showed ejection fraction after ASD closure

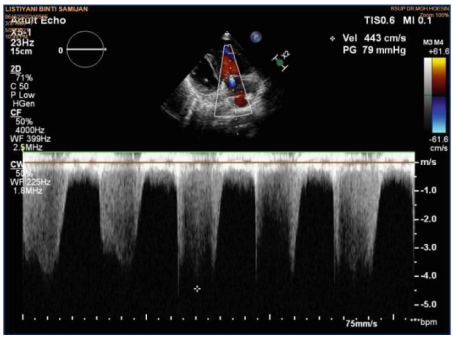

Fig. 8. Echocardiography ASD showed tricuspid regurgitation with pressure gradient 79 mmHg after ASD closure

3 Discussion

The researchers reported a case of a 31 years old woman with a main complaint of shortness of breath since a day before admission. Three months before admission, she complained about shortness of breath since three months ago when walking ±20 m and

when doing daily household work. The complaint was felt when her second pregnancy was 23 weeks and worsened significantly when increasing gestational age. She came to gynecology, and an ultrasound examination result showed the baby was healthy but low weight and suspected heart disease. She was consulted by an internist, and an echocardiography was performed. Echocardiography revealed congenital heart disease. The echocardiography examination results were global normokinetic, right atrial and right ventricular dilatation, severe tricuspid regurgitation/ pulmonary regurgitation, ejection fraction 73%, interatrial septal defect (+) with left to right shunt, severe pulmonary hypertension. The conclusion of echocardiography was secundum ASD, and severe pulmonary hypertension. The electrocardiography was sinus, incomplete RBBB, right axis deviation, right ventricular hypertrophy, right atrial enlargement, left atrial enlargement, ischemic anteroseptal inferiority. Chest x-ray revealed pulmonary hypertension.

Several hemodynamic changes during a normal pregnancy contribute to the overall increase in cardiac workload [1, 6]. The two predominant changes consist of a reduction in vascular resistance and an increase in cardiac output. Hormonal alterations in early pregnancy lead to a reduction in both systemic and pulmonary vascular resistance, accompanied by a decrease in blood pressure by 5–10 mmHg in the first two trimesters. From the onset of pregnancy until the end of the second trimester, plasma volume increases progressively by up to 50%, and it is associated with a 20–30% rise in the red blood cell volume. Additionally, the increased plasma volume initially contributes to a higher cardiac output, which peaks between 28 and 30 weeks of gestation. At this point, cardiac output may be 30–50% higher than the baseline pre-pregnancy value [1]. Women with pulmonary hypertension poorly tolerate the normal physiological changes of pregnancy. In women with pulmonary hypertension, pulmonary vascular disease prevents a rise in pulmonary artery pressure with increased cardiac output. Ultimately, the necessary increase in cardiac output can not be achieved resulting in right heart failure. Several signs of right heart failure, such as hepatomegaly, ascites, and ankle oedema, may be hard to identify during pregnancy or resemble normal pregnancy. Right heart catheterisation is required to confirm the diagnosis and gives useful information on pulmonary vascular resistance and cardiac output. It can be performed with relatively low fetal risk since radiation can be avoided [7].

Closure of an ASD is rarely required during pregnancy. Transcatheter closure of an ostium secundum ASD should not be performed in the context of an elevated pulmonary vascular resistance. Surgical ASD closure should be avoided during pregnancy and delayed until after delivery whenever possible [1]. Thus we decided for ASD closure after the termination of pregnancy and re-evaluation of pulmonary hypertension. After ASD closure surgery there was an improvement in pulmonary hypertension. Echocardiography showed improvement of ejection fraction and pressure gradient of tricuspid regurgitation 133 mmHg to 73 mmHg.

4 Conclusion

Pregnancy in women with ASDs is generally well tolerated, with good maternal and fetal outcomes. Nevertheless, an unrepaired ASD is associated with a higher risk of maternal and neonatal events. Although there is no definitive evidence demonstrating

superiority, ASD closure may be considered. Right heart catheterization is the gold standard investigation to confirm the diagnosis of pulmonary hypertension to support closure. Cardiology follow up during pregnancy should be adapted to clinical symptoms.

Author's Contribution. The authors performed an echocardiography examination to establish the diagnosis of pulmonary hypertension, ASD, participated in joint treatment and right heart catheterisation. The author collected patient data and described it in case reports with a literature review. The author and all co-authors contributed to the writing of the manuscript.

References

1. Bredy C, Mongeon FP, Leduc L, Dore A, Kahiry P, "Pregnancy in adults with repaired/unrepaired atrial septal defect," J Thorac Dis, vol.10, no. 24, 2018, S2945-S2952
2. Nashat H, Montanaro C, Li W, Kempny A, Worth SJ, Dimopoulos K, Gatzoulis MA, Babu-Narayam SV,"Atrial septal defects and pulmonary arterial hypertension," J Thorac Dis, vol. 10, no. 24, 2018, S2953-S2965
3. Warnes CA, Williams RG, Bashore TM, et al,"ACC/AHA 2008 Guidelines for the management of adults with congenital heart disease: a report of the American College of Cardiology/American Heart Association Task Force on Practice Guidelines (writing committee to develop guidelines on the management of adults with congenital heart disease)," Circulation, vol. 118, 2008, e714-833
4. Pascal E, Tulloh RMR,"Pulmonary hypertension in congenital heart disease," Future Cardiol, vol. 14, no. 4, 2018, 343–353
5. Udholm S, Udholm L, Nyboe C, Kesmodel US, Hjortdal V,"Pregnancy outcome in women with atrial septal defect: associated with in vitro fertilisation and pre-eclampsia," Open Heart, vol.6, no.2, 2019, e001148
6. Ouzounian JG, Elkayam U,"Physiologic changes during normal pregnancy and delivery," Cardiol Clin, vol.30, 2012, 317-29
7. Pieper PG, Hoendermis ES,"Pregnancy in women with pulmonary hypertension,". Neth Heart J, vol.19, 2011, 504–508