Management of Canine Crossbite with Combination of Expansion Screw and Labial Button: A Case Report

Puspitarini Nindya Wardana[1](✉), Maula Almira[2], and Hanisa Juliawati[2]

[1] Professional Program, School of Dentistry, Faculty of Medicine and Health Sciences, University of Muhammadiyah Yogyakarta, Yogyakarta, Indonesia
puspitarini@umy.ac.id

[2] School of Dentistry, Faculty of Medicine and Health Sciences, University of Muhammadiyah Yogyakarta, Yogyakarta, Indonesia

Abstract. Anterior crossbite is a malrelation in which one or more anterior teeth are malpositioned palatally or lingually in a centric occlusion with the mandibular anterior teeth. An alternative treatment to correct the anterior crossbite is by using a removable orthodontic appliance. This case report aims to report the management of canine crossbite using removable orthodontic appliances for a 25-year-old male patient with class I Angle's dental malocclusion with canine crossbite and deep overbite malrelation. The treatment used a removable orthodontic appliance in the form of an expansion screw combined with a labial button. Within 7 months, the canine crossbite was corrected and the deep overbite was reduced. Proper case selection and patient compliance are needed to achieve a successful removable orthodontic treatment.

Keywords: Canine crossbite · labial button · expansion screw

1 Introduction

Malocclusion is an abnormal relationship between the teeth of the arch outside the normal acceptable range. Malocclusion is not a life-threatening disorder, but it can cause problems with self-confidence, speech, chewing and swallowing disorders and periodontal disease [1]. Malocclusion can be caused by several factors, including hereditary factors, trauma, and bad habits [2]. Hereditary is the main factor in the causation of malocclusion, for example a difference between the shape, size, number of teeth and the arch which cause crowding of teeth [3].

Deep overbite is a common malrelation in both children and adults. Deep overbite is a condition in which the crowns of the mandibular incisors overlap vertically with the maxillary incisors when the teeth are in centric occlusion [4]. Anterior crossbite or single tooth crossbite is a malposition towards the palate or lingually one or more anterior teeth in a centric relationship with the mandibular anterior teeth [5].

I. Permana and E. Rochmawati (Eds.): ICOSI-HSN 2022, 55, pp. 350–357, 2022.
https://doi.org/10.2991/978-94-6463-070-1_43

Orthodontic treatment in simple cases can be handled using removable or fixed orthodontic appliances [6]. Success in the treatment of removable orthodontic appliances is strongly influenced by the motivation of the patient in using.

The appliance [7]. One of the active components of removable orthodontic appliances to obtain space without extraction is expansion screw, which is divided into two: dental arch expansion and skeletal expansion [8, 9]. The other active component in orthodontic appliances is elastic, which can move teeth individually. This appliance can also be used in cases of canines that shift to the palate because it has a combination of labial buttons to align the canines in an ideal arch [10]. This article is a case report on the use of orthodontic removable to resolve the main problem from patient with canine crossbite.

2 Case Report

A 25-year-old male patient complained of crowding and disturbing appearance of his maxillary front teeth. The complaint was first felt approximately 5 years ago. The patient admitted that his primary teeth (deciduous teeth) had no cavities and were neatly arranged. Loose primary teeth could fall out on their own. However, during the permanent teeth period, the patient had an accident that caused the maxillary canines to fracture and shift. The accident occurred when the patient was 12 years old. The patient claimed to have a habit of propping his chin, but had stopped it around 4 years ago. The patient routinely brushed his teeth twice a day, in the morning after breakfast and in the evening before bed.

On extraoral examination, it was found that the patient had a brachicephalic head shape, a leptoprosop face shape, and a convex facial profile. His temporomandibular joint was normal and his freeway space was 4 mm. On intraoral examination, the patient's OHI was in good condition with dewey modified 1 dental type Class I angle malocclusion with canine crossbite (tooth 23), deep overbite malrelation and individual maxillary and mandibular dental malpositions. The patient's overjet was 2.4 mm and the overbite was 5 mm.

The maxillary arch showed a discrepancy of 1.6 mm on the left and 1.3 mm on the right, while the lower arch showed a discrepancy of 1.3 mm on the left and 1.1 mm on the right (Fig. 1).

3 Case Management

The treatment given to the patient consisted of providing education and correction of teeth using removable orthodontic appliances. First, the dentist educated the patient about the causes of the complaints and the treatment that would be provided. Then the patient used asymmetrical radial expansion plate on the maxilla and lateral expansion on the mandible with a combination of grinding. The use of the appliance after insertion expansion screw was not performed during the first week to allow the patient's oral cavity to adapt to the appliance. He was instructed to use the appliance throughout the day except when eating and brushing teeth. He was also taught how to clean the plate by brushing the plate under running water without using toothpaste and instructed to return for a checkup once a week. The first appliance was an asymmetrical radial expansion

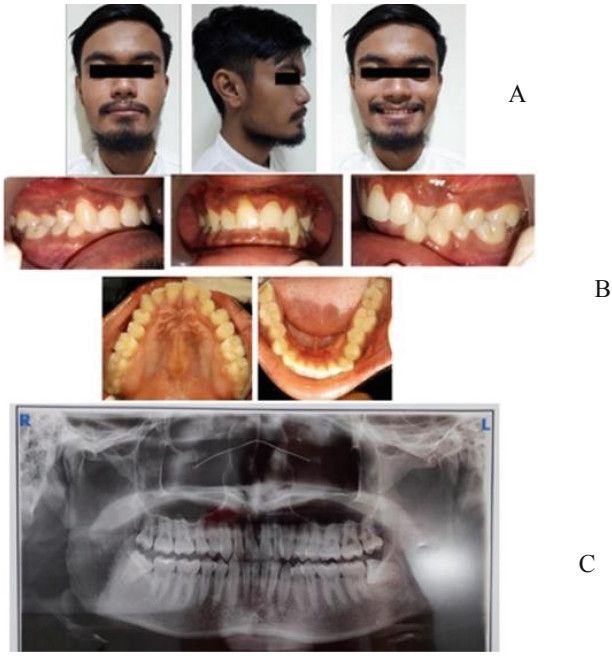

Fig. 1. **A.** Facial Photographs; **B**. Intraoral photographs of the patient before treatment; **C.** OPG examination showed that the patient's periodontal tissue was in good condition.

Fig. 2. Insertion of the first appliance. **A.** Occlusal view**; B.** Frontal view.

plate with a combination of anterior bite height for the maxilla and lateral expansion for the mandible. The use of this appliance was to get space and deep overbite correction. This appliance was used for 10 weeks (Fig. 2).

The second appliance was inserted on week 11 by using expansion screws on teeth 23, and using a separator between teeth 23 and 24. In addition, this appliance was equipped with a simple spring to correct tooth 12, and there was an anterior bite elevation. For

Fig. 3. Insertion of the second appliance on week 11. **A.** Occlusal view; **B.** Frontal view; **C.** Lateral view

Fig. 4. Combination of treatment using labial button and elastic

mandible, it was continued by using an active plate with a simple spring on tooth 43 and the labial arch to retract the anterior region. The use of this appliance was combined with a grinding strip and followed by the application of topical flour. This appliance was used until week 20 of the treatment (Figs. 3 and 4).

On week 21, a labial button was added on tooth 23, and a hook was attached to the labial arch, which was connected with an elastic. Checkup of patient was seen every week which involved changing the elastic and rotating the expansion screw one turn. The combination of appliances was carried out until week 28.

4 Treatment Results

On the 10th week after the treatment using the first appliance, there was a change in the maxillary inter canine arch from 2.9 mm to 35.2 mm, and the diastema between teeth

Fig. 5. Treatment results on week 10 using the first appliance. **A** Extraoral photo; **B** Intraoral photo

Fig. 6. Treatment results on week 20 using the second appliance. **A.** Extraoral photo; **B.** Intraoral photo

22 and 23 was 3 mm. The diastema was used to correct the crossbite of tooth 23. There was a deep overbite reduction from 5.5 mm to 4 mm. The use of the second appliance on week 11 to week 20 resulted in a reduction in the deep overbite to 3.5 mm. Tooth 31 which was originally labioverted had been corrected to the ideal arch, and so had tooth 33. Tooth 23 moved slightly towards the labial, but had not been in the ideal arch yet. On week 21, several appliances were combined: a labial button, hook, and elastic. Significant changes were clearly seen on week 28 when tooth 23 was in the ideal arch. During the use of the appliance, the patient did not complain about feeling pain in the TMJ (Figs. 5, 6, and 7).

Fig. 7. Treatment results on week 28 with modified labial button and elastic. **A**. Extraoral photo; **B.** Intraoral photo

5 Discussion

The use of an asymmetrical radial plate in this case was to obtain space for correcting tooth 23. After the space was obtained, the use of expansion screw in the second appliance was used to push tooth 23 in a labial direction. Expansion screw has several advantages over springs. It can be activated using a key, is more stable, and the pressure exerted on the teeth can be controlled. Activation of the expansion screw one quarter turn will produce a pressure of 3–10 lb. This will compress the tooth in the socket by.

0.12 mm, while the width of the periodontal ligament is 0.25 mm. The reduction in the width of the periodontal ligament does not interfere in blood circulation, so ideal tooth movement and bone formation can be achieved [11]. Expansion couplers provide intermittent force on removable orthodontic appliances that function to move teeth [12].

In this case, the use of expansion screw on tooth 23 did not show significant results; therefore, a combination with labial button and elastic was used to increase the tensile force. The use of removable orthodontic appliances combined with labial buttons and elastic in the treatment of anterior tooth crossbite is also described in a case report by Beycan and Nevzatoglu. The results of their study showed that during the 5 months of treatment, the crossbite was successfully corrected, crowding of the upper and lower anterior incisors was resolved, the occlusal trauma was removed, normal overjet and overbite were achieved, and smile aesthetics was significantly improved. In this case, apart from labializing tooth 23, the combination of labial button and elastic also aims to correct dystolabioversion in tooth 23. Orthodontic correction of a dental crossbite can also lead to spontaneous repair of the periodontal tissues since repositioning of the tooth into the proper alveolar foundation allows a better improvement in the distribution of forces as well as bone remodeling [13].

Deep overbite is a condition in which there is a large vertical distance between the incisal sides of the maxillary and mandibular incisors in a centric relation. One of the causes of deep overbite is bad habits such as propping the chin [14]. One of the ways to treat deep overbite is by using modified bite heights on removable orthodontic

appliances. Anterior bite risers will provide space for extrusion of the posterior teeth [15]. In this study, a removable orthodontic appliance with modified anterior bite height was used after considering the results of the Thombsond-Brodie deep overbite etiology analysis.

The results of the treatment showed that the patient's deep overbite was originally 5 mm and was then reduced to 3.5 mm. The anterior bite plane in the first stage of the removable appliance was used with a thickness of 2.5 mm. The thickness of the acrylic on the anterior bite riser was further increased to 3 mm, taking into account that there was sufficient space to move tooth 23 and was not excessive. Excessive use of a bite lift can cause a change in the vertical relationship, decrease patient co-operation and TMJ disturbances [16].

6 Conclusion

Canine crossbite and deep overbite were successfully corrected within 7 months. The treatment in this case study used a removable orthodontic appliance in the form of an expansion plate with a combination of labial buttons and elastic. Proper case selection and patient compliance are needed to achieve successful removable orthodontic treatment.

References

1. R. M. Sharaf and H. S. Jaha, "Etiology and treatment of malocclusion," International Journal of Scientific & Engineering Rese, vol. 8, no. 12, pp. 101-114, 2017.
2. S. Premkumar, Textbook Of Orthodintics-, Elsevier Health Sciences; 2015.
3. W. Farani and M. I. Abdillah, "Prevalensi Maloklusi Anak Usia 9–11 Tahun di SD IT Insan Utama Yogyakarta," vol. 10, no. 1, pp. 26–31, 2021.
4. S. Doakar and G. Agrawal, "Deep Bite Its Etiology, Diagnosis and Management: Review," Journal of Orthodontics & Endodontics, vol. 2, no. 4, 2016.
5. H. J. Alswairki and M. K. Alam, "Orthodontic Management of Moderate Crowding, Anterior Crossbite and Dental Midline Shift," International Medical Journal, vol. 26, no. 5, pp. 440-441, 2019.
6. Beycan, K., & Nevzatoglu, S. (2016). Treatment of Simple Anterior Crossbite with a Removable Appliance in the Permanent Dentition: A Case Report. Clinical and Experimental Health Sciences, 6(2), 98-100.
7. A. Hafiz, A. Haneem and M. Ikram, "Patient's Compliance on Removable Orthodontic Appliance," Journal of Research and Student, vol. 5, no. 1, pp. 1- 6, 2021.
8. A. Bakar, Kedokteran Gigi Klinis, 2 ed., CV. Quantum Sinergis Media, 2012
9. Proffit W and Fields H, Contemporary Orthodontics, 4 ed., St. Louis: Mosby Elsevier, 2007.
10. Davies, C. (2020). Textbook for Orthodontic Therapists. Wiley & Sons Ltd.
11. Manoharan M., P. Disha, Nagaveni N B, Roshan N M and Poornima P, "Correction of Anterior Crossbite with Different Approaches: A Series of Three Cases," International Journal of Oral Health and Medical Research, vol. 3, no. 3, pp. 41-43, 2016.
12. A. N. Candraningtyas, I. R. Sunaryo and A. Laviana, "Perubahan profil jaringan lunak bibir sebelum dan setelah perawatan ekspansi lengkung gigi menggunakan alat ortodonti lepasan," Padjajaran Journal of Dental Research and Student, vol. 5, no. 1, pp. 1-6, 2021.
13. ANDRADE, R. N., TÔRRES, F. R., FERREIRA, R. F., & CATHARINO, F. (2014). Treatment of anterior crossbite and its influance on gingival recession. RGO - Revista Gaúcha de Odontologia, 62(4).

14. K. Moharamzadeh, Diseases and condition in Dentistry An Evidance- Based Reference, Wiley Blackwell, 2018.
15. B. S. Iyyer, Orthodontics The Art and Science, 5 ed., Arya Media Publishing House PVT. Ltd, 2012.
16. J. Kotadiya, S. Fernandes, Y. Bafna, S. Soni and J. Patel, "Anterior Cross Bite Correction with Three Different Approaches: A Series," Journal of Medical Science And Clinical Research, vol. 07, no. 01, pp. 176-181, 2019.