CASE REPORT: Paget's Disease with Secondary Encephalopathy

Alfansuri Kadri(✉) and Eko Yandra

Department of Neurology, Faculty of Medicine, Universitas Sumatera Utara, Medan, Indonesia
alfansurikadri@yahoo.com

Abstract. Introduction: Paget's disease is a metabolic disorder of bone in which osteoclasts are more active than osteoblasts, resulting in increased bone resorption and compensated by excessive formation of new bone contributed by osteoblasts. Bones affected with Paget's Disease stimulate hypervascularization, leading to diversion of blood circulation to that area that can be accompanied by neurological diseases such as cerebral disorders or secondary encephalopathy and other complications such as anaemia.

Case Report: A 68-year-old woman (MG) was admitted to our hospital after suddenly becoming unconscious two hours earlier. Neurological examination revealed a sensorium sopor with a GCS (Glasgow Coma Scale) score of E1M2V2. Chest X-ray showed the impression of cardiomegaly, and plain radiographs of the lumbar vertebrae were radiolucent, indicating increased bone density on the first lumbar. A non-contrast head CT scan showed lytic lesions in the right parietal and temporal-occipital bones, indicating Paget's disease. The patient suffered from respiratory acidosis and anaemia; hence metabolic correction was initially addressed. The patient was also planned for a serum alkaline phosphatase check-up for bisphosphonate therapy.

Discussion: Paget's disease is a disorder of bone metabolism that can occur together with neurological diseases such as cerebral disorders or secondary encephalopathy with anaemia. The diagnosis of Paget's disease is made based on the history, clinical symptoms, serum alkaline phosphatase, and radiological examination. Therefore, disease management is more likely to focus on supportive approaches and medical care.

Keywords: Paget's Disease · Secondary Encephalopathy · Anaemia

1 Introduction

Paget's disease is a disorder of osteoclasts in which osteoclasts are more active than osteoblasts, resulting in excessive bone absorption followed by excessive new bone formation performed by osteoblasts. The bones become larger than normal, but the bone structure is extremely chaotic. This can cause bone pain, deformity, and bone fragility. Normal bone has a tight cross-shaped structure, like a regular brick wall. However, in Paget's disease, the internal structure of the bone changes to a mosaic and irregular structure, like a pile of bricks mixed with cement but thrown away without being correctly

M. M. Amin et al. (Eds.): ICoNaP 2022, AHSR 59, pp. 4–10, 2023.
https://doi.org/10.2991/978-94-6463-120-3_2

arranged. This causes the bones to thicken and enlarge, but they are very brittle and may break easily. The bones also become prone to bending and deforming because they are filled with fibrous tissue and blood vessels [1, 2].

Paget's disease is suspected to be related to ethnicity and geographic distribution. It is a fairly common disease in North America, England, Western Europe, and Australia (prevalence is more than 3% in people over 40 years of age). There is a tendency for familial aggregation. The cause is unknown, although the discovery of inclusion bodies in osteoclasts suggests a possible viral infection. This disease is rare in Scandinavia, India, China, Japan, and countries in Southeast Asia. This observation shows that genetic factors and environmental factors influence susceptibility to Paget's disease [3–5].

Neurological deficits such as paraparesis can be found in patients with Paget's disease if there is spinal stenosis. This is undoubtedly related to deformities in the lumbar region. In addition, as a result of increased resorption and bone formation performance in Paget's disease, hypervascularization occurs in the affected bone area. This will cause a diversion of blood circulation from internal organs to the surrounding bone circulation, which can cause cerebral disorders and spinal cord ischemia.

2 Case Report

A 68-year-old female patient came to the ER brought by her family with the chief complaint of loss of consciousness. The patient had experienced this for ±2 h before entering Mitra Sejati Hospital, which happened suddenly, around 05.30 AM after the dawn prayer, before the dawn prayer, the patient was still communicating with his child. The family denied a history of headaches, vomiting, and convulsions. The patient had shortness of breath and was diagnosed with heart disease in 2011. In 2016, she was also diagnosed with osteoporosis and received a second treatment in November 2021. During the patient's stay in Kabanjahe in early October 2021, the patient routinely received dexamethasone, ranitidine, and calcium drugs. Hypertension, DM, and gout were not indicated. The patient experienced hearing loss in December 2020 without any history of trauma, prolonged cough, weight loss, double vision, morning vomiting, or malignancy. The patient started using a single- point cane for regular activities in 2016 due to her physical condition, which has become difficult to walk. Three years later, the patient started to use a quad cane, and in 2021, she finally used a wheelchair for mobilization. Upon admission to the ER, neurological examination showed decreased consciousness with E1 V2 M2 (sopor) sensorium without other neurological deficits.

Chest X-ray examination showed cardiomegaly. Figures 1 and 2 of the thoracolumbar vertebrae show an increased density or radiolucent ivory-like image on the first lumbar. Figure 3 showed a non-contrast Head CT scan, indicating that lytic lesions on the right parietal and temporal-occipital bones most likely are due to Paget's disease.

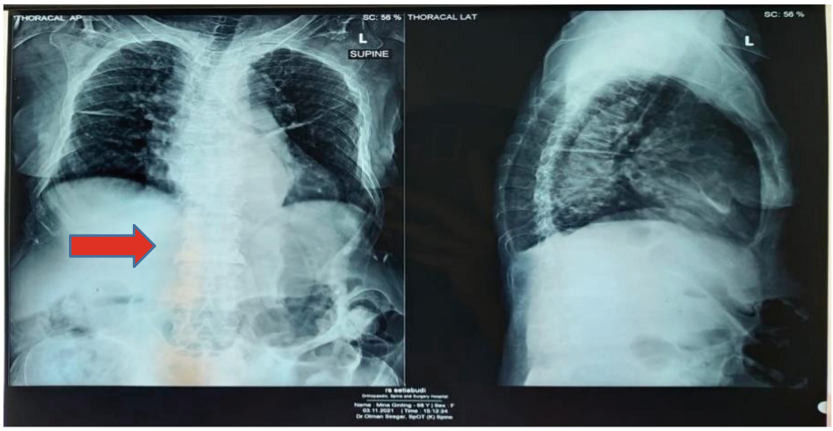

Fig. 1. Antero-posterior/Lateral thoracic vertebra radiograph showing peripheral thickening of the trabeculae and central radiolucency of the L-1 region.

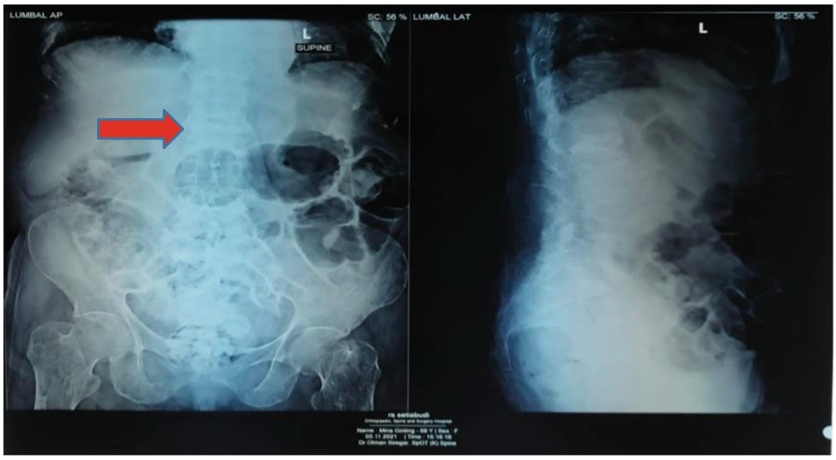

Fig. 2. Antero-posterior/Lateral lumbal vertebra radiograph showing peripheral thickening of the trabeculae and central radiolucency of the L-1 region.

The patient suffered from respiratory acidosis and anaemia; hence metabolic correction was initially addressed. The patient was also planned for a serum alkaline phosphatase check-up for bisphosphonate therapy and will be referred to the orthopaedic department. However, the patient died during the second day of treatment due to cardiac arrest suspected of septic shock.

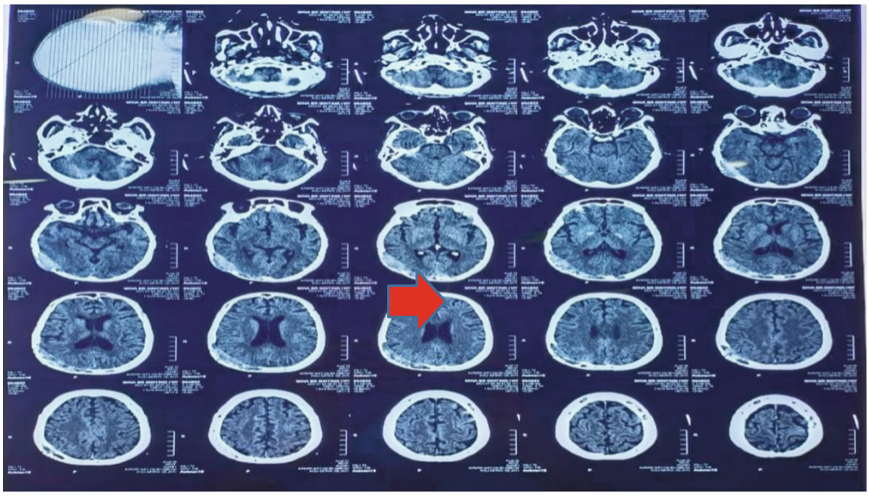

Fig. 3. Non-contrast Head CT showing lytic lesion on the right parietal and temporal-occipital bones.

3 Discussion

This case occurred in a 68-year-old woman, which is consistent with epidemiological studies for Paget's disease, which is rare in people younger than 55 years two and its prevalence increases with age [6]. Evidence from autopsy studies has shown that Paget's disease occurs in 3 percent of people older than 40. Approximately 15 percent of people with Paget's disease also have a family member [3]. The disease is familial, inherited in an autosomal dominant chromosome. Therefore, diagnosis and therapy at an early age are very important. Individuals older than 40, relatives or children of individuals who suffer from Paget's Disease should be checked for alkaline phosphatase levels every 2–3 years. In addition, other tests such as bone scans and x- ray are recommended.

In our case, Paget's disease was found in the first lumbar region with ivory and cranium features with sclerotic lesions in the right parietal, temporal and occipital bones. This is in line with epidemiological studies, stating that Paget's disease often affects the pelvis (70%), femur (55%), lumbar spine (53%), skull (42%), and tibia (32%). The patient came with a sudden loss of consciousness brought by the family to the ER, with no history of headache, enlargement of the skull, or any bone deformities in the upper and lower extremities. Therefore, this case is classified as asymptomatic Paget's disease, with no clinical symptoms prominently occurring. According to the literature, most people are diagnosed with Paget's disease incidentally during medical evaluation for other medical conditions. From the literature, there are many of Paget's patients who are asymptomatic, and the diagnosis is assumed to be coincidental based on findings on x-rays, CT scans, or an elevation of alkaline phosphatase (ALP). In this case, it was found incidentally that there was a head CT scan in the form of sclerotic lesions in the parietal, temporal, and right occipital bones that lead to Paget's disease. CT scans provide better visualization of bone, while MRI provides more detailed images of the brain, spinal cord, cauda equina, and soft tissues. In most cases, there is little evidence that further imaging with

computerized tomography, Magnetic Resonance Imaging (MRI), or Positron Emission Tomography (PET) is of any benefit over plain radiography; exceptions may include situations where there is concern about complications [6].

Decreased consciousness in our patient is due to secondary encephalopathy and respiratory disorders, which are known from blood gas analysis results, indicating impaired oxygen supply to the brain. Based on the patient's medical history, it is suspected that the patient had Paget's disease started one year ago when hearing function began to decline due to sclerosis of the ear bones (otosclerosis). Therefore, a plain radiograph of the skull was recommended. In addition, tuck SP et al. suggested plain cranium radiographs as patients often experience hearing loss in one or both ears due to narrowing of the auditory foramen and resulting compression of the nerves in the inner ear.

Several radiological supporting images strongly indicating Paget's disease in this patient were obtained; an ivory image on the lumbar-1 on plain radiographs of the AP/Lateral lumbar thoracal spine and head CT scan showing lytic lesions on the right parietal and temporal-occipital bones. Radiologic features are often pathognomonic, particularly in the lytic phase. Therefore, CT-Scan and MRI are very useful for evaluating complications of Paget's disease. Sclerotic lesions show a marked increase in the rate of bone resorption in localized areas due to a large number of osteoclasts. This local area of pathological destruction of bone tissue (osteolysis) is seen radiologically as a lytic wedge in the long bone or skull. Osteolysis is followed by a compensatory increase in bone formation induced by bone-forming cells, called osteoblasts, recruited to the area with a radiolucent appearance. It is associated with accelerated lamellar bone deposition irregularity. This intense cellular activity produces a chaotic appearance of the trabecular bone (a "mosaic" pattern) instead of the normal linear flattened pattern. The reabsorbed bone is replaced, and the bone marrow space is filled with excess fibrous connective tissue with markedly increased blood vessels, causing the bone to become hypervascular.

Our patient has been experiencing CHF since 2011 and osteoporosis since 2016, which is comorbid to her condition. CHF is associated with complications from Paget's disease, and this patient's history of CHF since ten years ago only aggravated the patient's hemodynamics and worsened the patient's condition, characterized by the patient's vital signs upon admission to the emergency room in a state of hypotension, tachycardia, and tachypnea which show signs of shock. Heart failure is an infrequently reported consequence of severe Paget's disease (i.e. more than 40% bone involvement). Abnormal bone formation is associated with abnormal blood vessel recruitment, forcing the cardiovascular system to work harder (pump more blood) to ensure adequate circulation. Heart failure occurs due to increased blood flow over a long period. The heart works hard to pump blood due to increased vascularity in the bones affected by Paget's disease, so that over time, the heart becomes weak, especially in patients who have narrowing of the arteries. This patient is assumed to have more than 40% bone involvement. A follow-up radionuclide bone scan can assess this to detect overall bone with Paget's disease. A radionuclide bone scan is a very sensitive diagnostic tool for evaluating the extent of bone lesions affected by Paget's disease. Abnormalities in bone scintigraphy appear earlier than radiological changes in the active phase. This patient did not undergo a radionuclide bone scan examination because the patient's general condition was unstable and not transportable.

Paget's disease is not associated with osteoporosis. Although Paget's disease and osteoporosis can occur in the same patient, they are different disorders. Despite the stark differences, several treatments for Paget's disease are also used to treat osteoporosis [7].

Differential diagnoses of this patient are hemorrhagic stroke and ischemic stroke. From the patient's complaints, there was a sudden decrease in consciousness and a history of heart disease. After that, a head CT scan as carried out to see if there were structural lesions in the brain or not. From the head CT scan, there is no hyperdense lesion that indicates a hemorrhagic stroke, and a hypodense lesion does not appear that leads to an ischemic stroke. Based on the anamnesis, no signs of malignancy were found, so the differential diagnosis of cranium metastases or skull metastases can be ruled out. Bone biopsy examination is very useful for the differential diagnosis of tumours or malignancies because skull metastases have the same radiological appearance as bone metastases elsewhere and in 90% of the most common causes of lytic lesions. The most characteristic pattern of Paget's disease is the presence of abnormal trabeculae, irregular cementation lines with a mosaic appearance, increased vascularity, number and size of osteoclasts. In contrast to cranium metastases, early destructive lesions are lytic lesions, with cortical destruction, periosteal new bone formation, soft tissue masses, or non-healing fractures [4, 8–10].

After examining serum alkaline phosphate, we planned to give alendronate, a bisphosphonate drug. Unfortunately, the examination was declined as the instrument had not been calibrated. Based on the literature, alendronate sodium is given in tablet form once a day at a dose of 40mg for six months. Patients should wait at least 30 min after drinking and before eating.

The patient's prognosis was poor because of her advanced age and comorbidities. For our patient, the possibility of her being able to carry out activities and complete recovery remains very unlikely.

At the time of initial admission, the patient showed signs of shock, such as hypotension, tachycardia, and tachypnea, so the patient was admitted to the ICU. While in the ICU, the patient was put on a ventilator and given medication to treat shock with fluid therapy and drugs to support the heart and blood vessels while the patient was followed up with vital signs every 30 min. Finally, the patient died on 5 January 2022, at 00.47 AM, suspected of having septic shock according to the SIRS criteria, namely leukocytes > 13,000, HR > 90x/min, and RR > 20x/min and the qSOFA criteria, namely RR 22x/min, systolic blood pressure 100 mmHg and loss of consciousness.

The limitation of this case report is that clinical and diagnostic follow-up could not be continued because the patient passed away after one day of hospitalization.

4 Conclusion

Paget's disease diagnosis is based on the history, clinical examination, neurological examination, and investigations. Management is mainly focusing on improving metabolic and symptomatic. Surgery may be considered in cases of bone instability or progressive neurologic symptoms with compression or deformity. Secondary encephalopathy is one of the neurological symptoms found in Paget's disease patients that still requires further research. Prognosis depends on the clinical factors of the disease.

The treatment outcome will be suitable without severe spinal deformities and apparent neurologic deficits.

Author's Statement. The author states that he has obtained the consent of the patient's family and maintains the confidentiality of the patient's identity.

References

1. Tuck SP, Layfield R, Walker J, Mekkayil B, Francis R. Adult Paget's disease of bone: a review. *Rheumatology*. December 2017: 56 (12); 2050–2059.Ralston, Stuart
2. H. Paget's Disease of Bone. *New England Journal of Medicine.* 14 February 2013: 368 (7); 644–650.
3. Alonso N, Paniagua IC, Pino-Montes JD. Clinical and Genetic Advances in Paget's Disease of Bone: a Review. *Clinical Reviews in Bone and Mineral Metabolism.* 19 December 2016: 15 (1); 37–48.
4. Charles JF, Siris E, Romain PL. Clinical manifestations and diagnosis of Paget disease of bone. Wolters Kluwer. 2020: 1–2
5. 4. Gruener G, Camacho P. Paget's disease of bone. Neurologic Aspects of Systemic Disease Part I. 2014: 529–540.
6. 5. Tan A, Ralston SH. Paget's disease of bone. QJM. 2014: 107(11); 865–869.
7. Sathyakumar S, Kapoor N, Hephzibah J, Paul TV. Unusual presentation of Paget's disease of bone. BMJ Case Reports. 2016: 1–2.
8. 7. Balani A, Marda SS. Paget's Disease of Bone. New England Journal of Medicine. 2016: 374(13); 1264–1264.
9. Alikhan MM. Paget Disease: Practice Essentials, Pathophysiology, Etiology. Medscape. 2020: 1–7.
10. Gaillard F, Sharma R. Skull metastases. Reference article, Radiopaedia.org. Mar 2022: https://doi.org/10.53347/rID-17904.