Diagnosis of Melanoma Using Thermography: A Review

Nazneen Akhter[1](✉), Ramesh Manza[2], Sana Shaikh[3], Bharti Gawali[2], Pravin Yannawar[2], and Shazia Shaikh[1]

[1] Maulana Azad College of Arts, Science and Commerce, Aurangabad, India
getnazneen@gmail.com
[2] Babasaheb Ambedkar Marathwada University, Aurangabad, India
plyannawar.csit@bamu.ac.in
[3] Rafiq Zakaria Centre for Higher Learning and Advanced Research, Aurangabad, India

Abstract. Cases of skin cancer have become very common in many parts of the world due to modernization in all aspects of life along with many other contributing factors. So it becomes important to study and evolve better and more efficient techniques for the early detection of cancer for faster and higher chances of recovery. Of the three types of skin cancers, melanoma is the deadliest and is characterized by changes in the colour, size or shape of a mole. The major focus lies in studying the evolving melanoma diagnostic techniques that are non-invasive and cause lesser discomfort to the patient. Various emerging technologies are enhancing the diagnostic approaches for melanoma detection out of which one promising technology is thermography. Currently, the assessment of thermography's effectiveness is in the research phase and studies are still being reported to substantiate its accuracy in the diagnosis of melanoma. This review analyzes the thermal imaging-based experimental studies conducted for melanoma detection with respect to factors like the experimental set-up, performance rates of the approaches, their limitations, and future scope.

Keywords: Thermography · Thermal imaging · Skin cancer · Melanoma detection · Non-invasive diagnosis of melanoma · Dynamic thermal imaging

1 Introduction

Skin cancer is a serious skin disorder that is caused due to the uncontrolled growth of abnormal skin cells. This abnormal growth is a result of damaged DNA molecules present in the cells that remain unrepaired. The damaged abnormal skin cells grow uncontrollably leading to the formation of malignant tumours. Of the three types of skin cancers, the deadliest is melanoma which begins in the melanocytes which are the cells within the epidermis. Melanoma accounts for less than two per cent of skin cancer cases, but the vast majority of skin cancer deaths [1]. The estimation of new cases of melanoma for the year 2022 is 99,780 out of which 57,180 and 42, 600 are the estimated counts for men and women respectively [2]. As per the Surveillance, Epidemiology, and End

S. Tamane et al. (Eds.): ICAMIDA 2022, ACSR 105, pp. 466–473, 2023.
https://doi.org/10.2991/978-94-6463-136-4_40

Results (SEER) Program, US, the estimated number of deaths due to melanoma in 2022 is 7650 which accounts for 1.3% of all cancer deaths [2].

Melanoma is known to be caused by exposure of the skin to Ultra Violet rays from all kinds of sources. Early signs may include new growth on the skin or changes in the mole. These changes are assessed clinically using the ABCDE (Asymmetry, border, colour, diameter, evolution) criteria. An abnormal neoplasm may qualify as a malig-nant one based on the applicability of all or some of the mentioned parameters.

Preliminary approaches for assessing a mole for any possible abnormality include self-examination followed by digital photography for assessment of the suspected region based on quantified clinical parameters. Since malignant melanoma in its early stages is similar to benign melanoma, the clinical diagnostic approach by assessing a lesion with ABCDE (Asymmetry, border, colour, diameter, evolution) criteria may sometimes prove inadequate. A neoplasm's chances of malignancy are evaluated by dermoscopy as it is one of the most commonly used digital screening methods for mole examination. But a concrete diagnostic approach for melanoma detection is the morphological examination by means of tissue excision called a biopsy. Non-invasive screening methods offer advantages over the methods that cause discomfort, pain and side effects to a suspected patient being examined. The utility of any diagnostic method can be evaluated in terms of its ability to deliver a correct diagnosis, the side effects and the associated cost [3]. Hence thermal imaging technology has long been associated with skin cancer studies and to date being examined for its possible usefulness in evaluating abnormal neoplasms while providing a safe and non-invasive means of screening. The study of diagnostic technologies that may aid in early diagnosis, improvement in survival rates and reducing the associated costs while providing accurate results, becomes valuable research. Both physicians and patients would benefit from the accurate and reliable technology that is able to yield objective and quantitative assessment of skin lesions [4].

Thermography is a non-invasive technology that is proving its efficiency in the medical field for the diagnosis of melanoma. Thermography is an imaging technique that incorporates infrared imaging technology to detect variations in temperature across the body. Thermography uses thermographic cameras to derive diagnostic indications (having a high level of detail and sensitivity) from infrared images of the human body. Medical thermography is used to determine areas of the body that have abnormal temperature variations. As the malignant tumours of the skin depict abnormal temperatures as compared to the normal skin area, thermography can be used as an adjunctive method to aid existing skin cancer detection procedures.

Similar to the criterion which states that the illness of a febrile person may be identified based on increased body temperature, a change of a quantitative measure, using a criterion developed based on infrared measurement of temperature distribution on the skin surface and its evolution as a function of time, can serve as an indication of cancer [5]. Cancerous lesions, such as melanomas are characterized by increased metabolic activity and have a varying thermal recovery rate as compared to the surrounding healthy skin, thereby creating a marker for the detection of melanoma [4]. Figure 1(a) is the digital light image and Fig. 1(b) is the thermal image of the melanoma lesion on a patient's right foot plant [6]. It can be observed that the thermal profile of the melanoma-affected region is visibly different from the surrounding region.

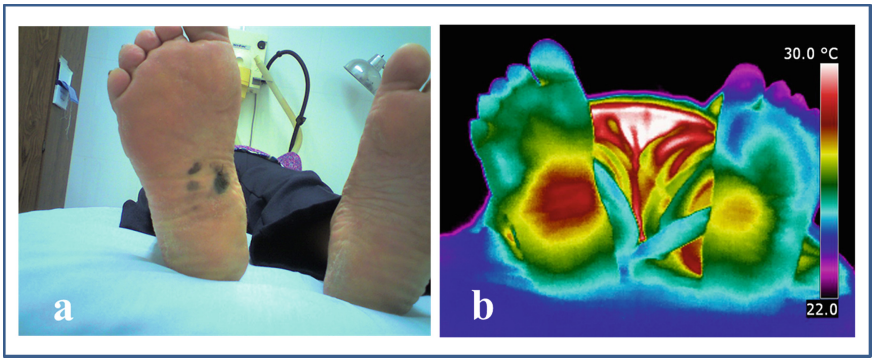

Fig. 1. Digital light image (a) and the thermal image (b) of the melanoma lesion on the right foot plant

2 Thermal Imaging-Based Diagnostic Approaches for Melanoma Detection

A useful criterion for detecting a suspected malignant neoplasm as a malignant one is by means of detecting the temperature difference between the neoplasm and the surrounding skin region. As stated by Kudrin et al. [7], passive thermal imaging (done with a Thermal Expert TE-V1 portable thermal camera) was not useful in discerning the temperature differences as the lesions were not visible in the thermal images and the lesions were visible in the white light digital images. Their conclusion is based on experimenting with a complex imaging setup for studying neoplasms that included thermal imaging as an additional imaging modality. The reported sensitivity and specificity are above 90%. For investigating a comparative assessment of artificial intelligence-based methods for skin cancer diagnosis using thermal imaging, Magalhaes et al. [8], used 14 thermal parameters of skin lesions as input vectors to the machine learning algorithms- ensemble learning and deep learning. Based on the precision, recall, f1-score and ROC (AUC) - the deep learning model performed better than the learning ensemble model, the tradeoff being fast computation. For the distinction between melanoma and seborrheic keratosis, Stringasci M. D. et al. [9] studied 310 thermal images of skin cancer out of which 20 lesions were melanoma. They developed a MATLAB program routine to assess the statistical histogram values and the filtering metrics which formed the base lesion classification by means of the support vector classifier. They reported support vector as an effective classifier serving the aimed purpose and also reported the malignant lesions as lesser defined at their borders as compared to the benign lesions. Their study is conclusive and highlights two important observations. First, the malignant lesions are comparatively challenging areas to define in thermal images due to lowly defined borders. Another fact supporting the first observation is that the benign and malignant lesions exhibit similar temperatures which defy the basis of differentiation of both using the temperature variation criterion. However, in comparing pigmented seborrheic keratosis with melanoma, no significant differences were observed in their thermal properties other than the definition of their borders.

Cruz et al. [10] initiated a program aimed to investigate the suitability of dynamic infrared imaging for following-up two nodular melanoma patients treated with BNCT. The investigation setup consisted of an IR camera (Raytheon PalmIR 250, L3 Comm. Systems) with a focal plane array of 320 x 240 uncooled ferroelectric detectors that are sensitive to IR radiation in the 7–14 mm wavelength band along with a double-cavity black body, used for temperature calibration. Before the beginning of the thermographic procedure, the patients were made to rest for a period of 15–20 min so that the region to be examined reached an approximate steady physiologic state of thermal equilibrium. After that period a 30-s basal study was performed to record the initial temperature distribution followed by a cold stimulus that was applied and another video acquired for 3 min or more. IR studies were carried out before BNCT and were later followed by a clinical inspection, CT and high-resolution Doppler ultrasound. Additionally, an algorithm was applied to extract minor variations in skin colour during these procedures. It was observed that the skin temperature 1 min after the cold stimulus within the irradiation field was actually higher than its basal temperature. The temperature of the tumour was still higher than the normal tissue temperature. It was concluded that DIRI has higher sensitivity than Doppler and is similar to CT and that it could prove to be a sensitive tool to study skin toxicities and tumour control in BNCT melanoma treatments. DIRI can help to locate abnormally high-temperature regions as well as melanoma nodules that are virtually invisible in CT images, owing to their minor-contrast differences with respect to normal tissue.

Çetingül and Herman [11] compared data obtained by imaging benign and malignant pigmented lesions, measured surface temperature distributions for characteristic time instants as well as temperatures of selected points on the surface of healthy skin were compared as a function of time. 35 Patients with a pigmented lesion that was suspicious of malignancy were chosen as subjects for this study and later for biopsy. The pigmented lesion was marked and its white light image was captured with a digi-tal camera (Canon PowerShot G11). Following this, a polarized light picture was recorded using a dermatoscope connected to a digital imaging device. To obtain the confocal microscopy images, the surface of the involved skin was examined with the CSLM (Vivascope 1500). The infrared images were recorded with a Merlin (35 mm) infrared camera (MWIR). A directed Cold air was applied to the patient's lesion area and its surrounding area of 50 mm diameter for up to 60 s. For image analysis, a multimodal image analysis system was designed, which involved calibration as well as correction steps, such as motion estimation, image registration and segmentation. A Landmark detection algorithm, quadratic motion model and random walker (segmentation algorithm) were applied for localizing the corners of the marker, aligning the IR image sequence during the recovery phase to compensate for involuntary body/limb movement of the patient and spatially guiding the segmentation, respectively. From the data of 35 subjects, only 2 mol were found to be malignant melanoma and both were detected in a very early stage. After the application of cooling excitation, the cold regions were found to have warmer sub-regions suggesting increased metabolic activity and possibly malignancy. It was observed that a malignant lesion emitted a higher temperature than the surrounding healthy tissue indicating a marker for melanoma.

Herman and Çetingül [12] explored the feasibility of IR imaging as a cost-effective, non-invasive in vivo optical measurement technique for the early detection of melanoma. The subjects chosen for IR imaging were having pigmented lesions and were candidates for biopsy. The setup for this study included a temperature-controlled room having an IR camera and a personal computer to which a data acquisition card was connected. The setup also incorporated thermocouples connected to a data acquisition card for monitoring the room temperature and skin surface temperature. Since the cooling effect is required for the lesion in the thermal image to be detected, a square adhesive marker was used to localize the pigmented lesion of interest and its surroundings. For image acquisition, bright light images (taken with Canon PowerShot G11 digital camera), and polarized light images (taken with the dermatoscope, DermLite Foto System) of the pigmented lesion and the adhesive window were taken initially. A stream of cold air was applied to the same region and along a 50 mm diameter surrounding it for a minute. After this, the region under cooling stress was allowed to re-warm for 3–4 min which is called the thermal recovery phase during which the IR images were captured every 2 s. The software used to save and study all these images was Labview. Image analysis was done using a dedicated MATLAB code and a multimodal image analysis system. Landmark detection algorithm, quadratic motion model and random walker (segmentation algorithm) were applied for localizing the corners of the marker, aligning the IR image sequence during the recovery phase to compensate for involuntary body/limb movement of the patient and spatially guiding the segmentation respectively. After locating the lesion in the IR images, the lesion's thermal response was compared with that of the healthy skin. The results clearly suggested that the cooling effect gave rise to the temperature difference between the malignant lesion and healthy skin which became a clear indicator of melanoma thereby proving the benefits of dynamic thermal imaging for melanoma detection.

González et al. [6] investigated the thermal signature of melanoma and non-melanoma skin cancers in order to be used as a non-invasive aid in the diagnosis and vascular assessment of these types of skin cancers. 30 patients were studied for ob-taining temperature profiles using a FLIR T400 infrared camera. The thermal images were analyzed in order to obtain the temperature difference between the cancer lesion and the unaffected reference skin area. The diagnosis of skin cancer was also done clinically and by histopathology with hematoxylin-eosin-stained sections. The pathological slides were studied by two dermatopathologists individually for locating the tumour blood vessel. The captured IR images were processed using the public domain software ImageJ v1.44. It was observed that in the case of melanoma even though the local temperature increases, there is no increase in vascularity of the tumour, which indicated that in the case of melanoma, there is higher variation in metabolic heat produced by the tumour compared to the variation in its vascularity. The thermal signatures of melanoma and non-melanoma cancers vary and it is indicative that in the case of melanomas, metabolic heat production is more relevant in assessing aggressiveness than the vascularity, which basically remains constant. The results were a step forward in the design of a thermal model for skin neoplasms.

Shada et al. [13] studied the possibilities of differentiating benign and malignant melanoma lesions using thermal imaging. Seventy-four patients (36 females and 38 males) above the age of 18 with 251 palpable lesions were imaged for this pilot study. Clinical diagnosis, in the form of pathological testing, was used for the cross-confirmation. Lesion assessment was graded by lesion diameter (strata a – d that falls in the range 0 to > 3). A total of 251 lesion regions were marked with hypothermic triangular frames for the purpose of imaging. Amber Radiance 1-T IR imager was used for imaging the lesion region and its surrounding healthy region for comparison when required. The same regions were imaged with a digital camera to obtain white light images. A co-registration was done for both types of images for identifying the suspected region as a lesion. The parameters taken into consideration were the body region, lesion's diagnosis, diagnosis method, depth, colour and diameter. A scoring system was used starting from -1 to + 3 for lesions indicating possibilities ranging from no difference between healthy and suspected lesions to significantly warmer lesion areas as compared to surrounding skin respectively. Statistics such as mean, standard deviation and other measures were computed to support the evaluation. The results highlighted that melanoma lesions were subcutaneous in most cases as compared to non-melanoma lesions. A positive predictive value of 88% onwards and a negative predictive value of 95% for larger lesions were obtained. Through their study, they highlighted the observation that lesions with diameters greater than 15mm were hyperthermic in nature. Smaller melanoma lesions were also reported to be hyperthermic as compared to non-melanoma lesions. They reported a very high specificity ranging from 89% - 100% for all sized lesions. But the sensitivity was high (95%) for the lesions that were greater than 1.5cm in diameter. As a limitation, it was found that clinical diagnosis was still required for most lesions.

Magalhaes, C. et al. [14] used static and dynamic thermal imaging to differentiate melanoma from melanocytic nevi lesions. Using FLIR E60sc thermal imager, the lesions were imaged for subjects in the age range of (18 years and above). This was done by recording images beginning from the static state to the dynamic state at an interval of one minute, resulting in 5 images for each lesion. They concluded that the Support Vector Machine provided more relevant results, with an accuracy of 84% and a sensitivity of 91.3%. This method outperformed the performance of dynamic thermal imaging coupled with the application of sequential minimal optimization, multilayer perceptron and instance-based k-neighbour classifiers.

Benjumea, E. et al. [15] proposed a non-invasive diagnostic tool for melanoma detection on basis of their study on thermal images of melanoma lesions. They per-formed segmentation and then computed histogram-based statistical features of lesion areas that were extracted by means of manual extraction from the thermal images. Using the k-means clustering technique they differentiated the cancerous lesion by bifurcating it from other colours and observed that the lesion regions tend to have higher average values of red colour compared to the blue and green colours. Their experimentation was an extension to the work reported by S. Shaikh et al. [16] for skin cancer characterization using thermal images of the malignant lesions, where they highlighted the prominence of the red component in the clustered images of cancerous lesions using histogram-based statistical computation.

3 Conclusion

Thermal imaging is increasingly being studied and applied for its non-invasive nature and for its ability to deliver quantified thermal indicators that help in studying malignant lesions like melanomas through dynamic and passive thermal screening of the lesion sites. Despite using different approaches and experimental setups as part of the investigations, thermography provided a significant success rate in identifying malignant lesions from benign ones. For most of the presented studies, the dynamic thermal imaging of the suspected lesion was observed to provide significant results which lead to the differentiation in the thermal responses of the malignant lesions and benign lesions. Through the reported works, it is also highlighted that the thermal recovery factor, after thermal stimulation of the suspected site is a primary factor that leads to the detection of malignant neoplasms. The AI-based machine learning models can also help to classify a lesion into malignant or benign classes with the help of carefully selected input vectors derived from thermal quantifications. The quality and reliability of achieved outcomes may be further enhanced with the implementation of the standard and universal thermal imaging protocols that are specifically outlined keeping the medical application as the prime consideration. Though, currently, a biopsy is the most reliable diagnostic method to detect melanomas, the inclusion of dynamic thermal imaging along with the biopsy for each test may play a useful role in assessing all suspected cases with regard to the comparison of the diagnostic results provided by both. A long-term execution of this combination testing may help to establish the usefulness of thermal imaging as a safe and preferable diagnosis method for skin cancer detection in the future.

References

1. Skin cancer information, https://www.skincancer.org/skin-cancer-information/, last accessed 2022/09/17.
2. Melanoma of the skin - cancer stat facts SEER, http://seer.cancer.gov/statfacts/html/melan.html, last accessed 2022/09/21.
3. Faust, O., Acharya, U. R., Ng, E. Y. K., Hong, T. J., Yu, W.: Application of infrared thermography in computer aided diagnosis. Infrared Physics & Technology 1(66), 160-175 (2014).
4. Herman, C.: Emerging technologies for the detection of melanoma: Achieving better outcomes. Clinical, Cosmetic and Investigational Dermatology 5, 195 (2012).
5. Herman, C.: The role of Dynamic Infrared Imaging in melanoma diagnosis. Expert Review of Dermatology 8(2), 177-184 (2013).
6. González, F. J., Castillo-Martínez, C., Valdes-Rodríguez, R., Kolosovas-Machuca, E. S., Villela-Segura, U., Moncada, B.: Thermal signature of melanoma and non-melanoma skin cancers. In: CONFERENCE 2012, 11th International Conference on Quantitative InfraRed Thermography, pp. 11–14, Naples Italy (2012).
7. Kudrin, K. G., E. N. Rimskaya, I. A. Apollonova, A. P. Nikolaev, N. V. Chernomyrdin, D. S. Svyatoslavov, D. V. Davydov, I. V. Reshetov.: Early diagnosis of skin melanoma using several imaging systems. Optics and Spectroscopy 128(6), 824–834 (2020).
8. Magalhaes, C., Tavares, J. M. R., Mendes, J., Vardasca, R.: Comparison of machine learning strategies for infrared thermography of skin cancer. Biomedical Signal Processing and Control 69, 102872 (2021).

9. Stringasci MD, Salvio AG, Sbrissa Neto D, Vollet-Filho JD, Bagnato VS, Kurachi C.: Discrimination of benign-versus-malignant skin lesions by thermographic images using support vector machine classifier. Journal of Applied Physics 124(4), 044701 (2018).
10. Santa Cruz, G.A., Bertotti, J., Marín, J., González, S.J., Gossio, S., Alvarez, D., Roth, B.M.C., Menéndez, P., Pereira, M.D., Albero, M., Cubau, L.,: Dynamic infrared imaging of cutaneous melanoma and normal skin in patients treated with BNCT. Applied radiation and isotopes 67(7–8), S54-S58 (2009).
11. Çetingül, M.P., Herman, C.: Quantification of the thermal signature of a melanoma lesion. International Journal of Thermal Sciences 50(4), 421–431 (2011).
12. Herman, C., Cetingul, M.P.: Quantitative visualization and detection of skin cancer using dynamic thermal imaging. JoVE (Journal of Visualized Experiments) 5(51), e2679 (2011).
13. Shada, A.L., Dengel, L.T., Petroni, G.R., Smolkin, M.E., Acton, S., Slingluff, Jr. C.L.: Infrared thermography of cutaneous melanoma metastases. Journal of Surgical Research 182(1), e9-e14 (2013).
14. Magalhaes, C., Vardasca, R., Rebelo, M., Valenca-Filipe, R., Ribeiro, M., Mendes, J.: Distinguishing melanocytic nevi from melanomas using static and dynamic infrared thermal imaging. Journal of the European Academy of Dermatology and Venereology 33(9), 1700-1705 (2019).
15. Benjumea, E., Morales, Y., Torres, C., Vilardy, J.: Characterization of thermographic images of skin cancer lesions using digital image processing. Journal of Physics: Conference Series 1221(1), 012076 (2019).
16. Shaikh, S., Akhter, N., Manza, R.: Application of image processing techniques for characterization of skin cancer lesions using thermal images. Indian Journal of Science and Technology 9(15), 1-7 (2016).