Influence of Mangrove Leaf Extract Rhizophora Apiculata Blume on The Number of Spermatogonium Cells in White Rats (Rattus Norvegicus L.)

Amiruddin[1], Sriyana Herman[2]*, Tiani[1], Lili Darlian[1], Dwi Nurhidayah[1], Wa Ode Harlis[1], Rusli Rusli[3]

[1]Department of Biology Education, Faculty of Teacher Training and Education, Universitas Halu Oleo, Kendari, Indonesia
[2]Department of Reproductive Health, Faculty of Health Technology, Universitas Megarezky, Makassar, Indonesia
sriyanah@unimerz.ac.id
[3]Department of Physiotherapy, Faculty of Sport and Health Sciences, Universitas Negeri Makassar, Makassar, Indonesia

Abstract. Many cases of infertility are caused by several things, one of which is a disruption of the hormone cycle, which results in a decrease in the levels of hormones produced. Objective: To determine the effect of Rhizophora apiculata Blume mangrove leaf extract on the number of spermatogonium cells of white rats (Rattus et al.). Method: Using the Tru-experiment with a completely randomized design (CRD), followed by a simple random sampling technique and analyzed using the ANOVA test and the Tukey-HSD follow-up test (α=0.05) with IBM SPSS version 26. The study population consisted of 50 rats. White male, then randomized into 24 tails with criteria of 8-10 weeks old, healthy body, and average weight of 150-200 grams. Results: The higher the concentration of the extract given, the less the number of spermatogonium cells produced, with the average number of spermatogonium cells obtained being P0: (71 cells), P1: (47 cells), P2: (30 cells), and P3: (19 cells). Conclusion: Mangrove leaf extract has a significant negative effect on decreasing the number of Spermatogonium cells in white rats ($p<0.05$). This is due to the content of active metabolite compounds such as tannins, alkaloids, saponins, and flavonoids, which work as antifertility through hormonal effects, which can reduce the number of cells in spermatogonia..

Keywords: Mangrove Leaf Extract, Spermatogonium Cells, White Rats.

1. Introduction

Reproduction is the process of multiplying offspring to preserve and maintain the life of living things. Every living thing has different reproductive abilities. Some produce one child at a time and reproduce and have to wait a long time to get one. However, there are also living things that are able to reproduce by producing many children within a relatively short period, thus increasing the population of living things in an area, especially humans.

Infertility is one of the leading cases in the male reproductive system, which can have an impact on reproductive difficulties. Infertility can be caused by several things, one of which is malnutrition. Malnutrition can also cause hormonal disturbances with clinical manifestations in the form of decreased libido and damage to the genital tract, such as obstruction, causing ejaculatory disorders and even testicular degeneration, which leads to permanent damage to the main male reproductive organs [1].

B. Bustang et al. (eds.), *Proceedings of the Second Makassar International Conference on Sports Science and Health (MICSSH 2023)*, Advances in Health Sciences Research 74,
https://doi.org/10.2991/978-94-6463-354-2_25

The testes are the primary reproductive organs where spermatozoa are produced. As in general mammals, pangolin testicles have adjacent arteries and veins that function as a mechanism for exchanging heat and cold so as to minimize the effect of rising temperature in the abdominal space on the process of spermatogenesis. The testes are composed of seminiferous tubules separated by interstitial tissue. The tubule basement membrane, germinal epithelial cells (spermatogonia, spermatocytes, and spermatids), and Sertoli cells form the walls of the seminiferous tubules. In the interstitial tissue (seminiferous intertubules), there are Leydig cells and blood vessels. In the mediastinum of the testis, the seminiferous tubules join to form the rete testis, then through different ducts to the epididymis through the proximal end of the testis, which is directly connected to that part of the head epididymis

Spermatogenesis is the process of forming spermatozoa that occurs in the testes, through the process of differentiation of spermatogonia (*diploids*) into spermatozoa (*haploid*) produced continuously and dynamically Spermatogenesis goes through three stages phase: first (mitosis), spermatogonia proliferate and produce spermatocytes primary; second (meiosis), primary spermatocytes undergo genetic recombination and produce secondary spermatocytes which will then differentiate into spermatids; third (spermiogenesis) undergo a process of differentiation cells, resulting in a characteristic sperm morphology for each species [2].

Mangrove is a tropical forest plant that is easy to grow, and not much has been exploited for its bioactive substance. Mangrove plants have many benefits for human life, ranging from ecological benefits to benefits as a source of food and medicine. The reason for the importance of studying the bioactive substances of mangrove plants is that mangroves are one of the tropical forest vegetation that is easy to grow and has yet to be widely utilized. The potential bioactive substances of mangroves have medical value, one of which is from the Avicennia genus, which is a type of plant that is widely spread in Indonesia, including those found growing in the coastal waters of Sulawesi. Mangrove species Avecenia Sp, especially Avicenna marina mangrove, is known to contain secondary metabolites in the form of saponins, alkaloids, tannins, flavonoids, triterpenoids, phenolics, and glycosides. From the mangrove content, it is known to have benefits as an anti-microbial, anti-inflammatory malaria, anti-cancer, and anti-oxidant [3].

Various studies have been conducted to see the influence exerted by extracts from various plants on the structure of animal reproductive organs. Harris and Septiana [4], in their research on the effect of giving brotowali plant extract on the reproductive system of male mice, stated that giving brotowali extract had an apparent effect in the form of a decrease in the number of spermatogenic cells in each section of the seminiferous tubules of mice. Pranadya et al., [5], in their research on the number of spermatogenic cells and testicular histology after administration of red calliandra leaf extract, stated that the given calliandra leaf extract caused a decrease in the number of spermatogenic cells in the seminiferous tubules of white rats (Rattus norvegicus L.) Yasmin et al., in their research on the effect of giving bitter gourd ethanol extract to seminiferous tubule tissue in male mice, stated that giving bitter gourd ethanol extract could reduce the thickness of the seminiferous tubules with the optimal dose of 1,120 mg/kgBB day. While Anzila et al., [6] concluded that the administration of basil extract on mouse males (Rattus norvegicus L.) Balb-c strain with 200 mg/kg BW has the potential to enhance the process of spermatogenesis or as a fertility agent.

2. Method

This type of research is an experiment (True-Experiment t) using a Completely Randomized Design [7]. This research was conducted from October 2022 to March 2023 (6 months) and took place at the Biology Education Laboratory, Teaching and Education Faculty, Halu Oleo University, Kendari, Southeast Sulawesi. The population of this study is 5 0 white mouse tail (Rattus norvegicus L.). The sample of this research was obtained by simple random sampling of 24 white rats (Rattus norvegicus L.), with the criteria of sample weight 150-200 grams, 8-10 weeks old, sex (male), and in good health. The procedures in this study include:

2.1 Preparation of Test Animals

The Animals used are 12 white rats (Rattus norvegicus L.) male aged 12-13 weeks with an average body weight of 25 – 3 0 g. White rats were obtained from the Halu Oleo University Biology Laboratory and acclimatized for two weeks. White rats were kept in groups (three mice in a cage)—round cages covered with wire. Bedding in the cage is in the form of wood shavings, which are replaced twice a week during the maintenance of the feed given as much as five g/day in the form of pellets given in the morning after administration of the extract. Drinking water is provided ad libitum through drinking bottles.

2.2 Manufacture of Mangrove Leaf Extract

Preparation of mangrove leaf extract Rhizophora apiculata Blume starting from taking mangrove leaves Rhizophora apiculata a Blume on the third and fourth leaves in the Mangrove area of the Kendari Al-Alam Mosque. Mangrove leaves are cleaned of dust, drained, and air-dried, then baked in an oven at 70 º C until the leaves are dehydrated for 48 hours. Then, the mangrove leaves are crushed using a blender and sieved into a fine powder. In the next stage, mangrove leaf flour was macerated with absolute ethanol for 1x2 hours. The ratio of the ingredients to the ethanol solvent is 5:1, that is, 5 liters of ethanol mixed with 1 kg of mangrove leaf flour. The macerated material was filtered three times to obtain an extract solution without dregs. The filter results are mixed, and the solvent is evaporated using a rotary vacuum evaporator at 70 º C [8].

2.3 Treatment

Mangrove leaf extract was administered in the morning at 07.00 with different doses, namely 20 mg/Kg, 25 mg/Kg, and 30 mg/Kg, and the extract was administered for 49 days on day 50 (Santi et al., 2018). Mice were sacrificed by anesthetizing them to death using 2 ml of chloroform. Mice were dissected from the abdomen to the chest. Then, the testicles were taken and separated from the adhering fat, after which they were cleaned with NaCl before making testicular histology preparations.

2.4 Making Histology Preparations

The steps in making histological preparations are:

2.4.1 Fixation

The testes taken are fixed with Bouin's solution for approximately two days. After approximately two days, the organs are then washed (washed) with 70% alcohol (1 x 60 minutes).

2.4.2 Dehydration

The process then soaked the testicles with 90% alcohol solution for one night, then transferred to 96% alcohol and absolute alcohol for 1 x 60 minutes each. After the dehydration process is complete, proceed with the cleaning process, namely soaking the testicles using a solution of toluol for one night and then infiltrating with paraffin by immersing the testes in a mixture of toluol and paraffin with a ratio of 1:1 (30 minutes) then followed by pure paraffin I, II, III for 45 minutes.

2.4.3 Embedding

This process is by implanting the testicles in paraffin, positioning them so that the cutting direction is transverse, and then allowing them to freeze and form blocks ready to be sliced with a microtome.

2.4.4 Cutting

The paraffin block was then attached to the microtome and sliced 3µm thick, resulting in a row of slices to form ribbons. A good one is selected from these slices and placed on a slide smeared with Mayer's albumin left in a slide warmer for 24 hours for stronger adhesion.

2.4.5 Staining and Mounting

1) Deparaffinization: The glass object containing the testicles was dipped into xylol solution until all the paraffin dissolved (15 minutes) and then dried on filter paper. 2) Hydration, the glass object that has been dried earlier is put into alcohol with a decreasing concentration starting from absolute alcohol, 96%, 90%, 80%, 70%, 60%, 50%, 40%, 30%, and distilled water respectively for one minute each. 3) Put it in the staining jar containing Hematoxylin Eosin for 7 seconds, then wash with running water for 10 minutes. 4) Put it in 30%, 40%, 50%, 60%, and 70% alcohol for one minute each, then put in Eosin-Y for 2 minutes, then rinsed with 70%, 80%, 90%, 96% alcohol and absolute alcohol for one minute each. 5) The preparations were put into xylol solution for 15 minutes, dried on filter paper, mounted with Canada balsam, covered with a cover slip, and dried on a hot plate at 44°C for two days. 6) Observations were made under a microscope to obtain a histological picture of the testicular seminiferous tubules.

2.5 Observation of Histological Preparations

Histological preparations of the testes were observed under a light microscope with a magnification of 400 times to obtain an overview of the number of testicular spermatogonium cells of white rats (Rattus norvegicus L.). The data collected is quantitative and presented as tables and diagrams. Spermatogonium cells were observed using a microscope field of view and counted using a hand counter. Data on the number of spermatogonium cells was obtained and then analyzed using SPSS statistics software version 26.

3. Result

3.1 Descriptive Analysis

3.1.1 Temperature

Table 1. Average Cage Temperature during the Study

Week-	Average Temperature (°C)			
	Morning (08.00)	Afternoon (12.00)	Afternoon (16.00)	Evening (21.00)
1	27	30	28	26
2	26	30	28	25
3	26	30	28	25
4	26	29	27	25
5	25	30	27	24
6	25	30	28	24
7	25	30	27	24

Based on Table 1. A comparison diagram of the average cage temperature during the study can be seen in Figure 1.

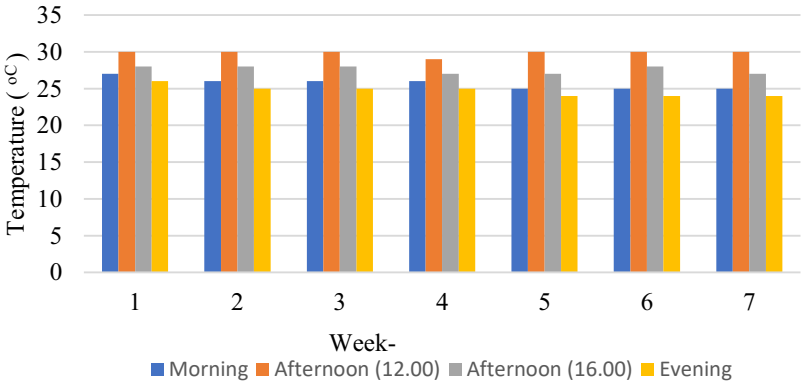

Fig. 1. Histogram of average ambient temperature during the study

Based on Table 1 and Figure 1, it was concluded that the average temperature of the rat cage (Rattus norvegicus L.) during the study in the morning was around 25-27 0 C. During the day, it was around 29-30 0 C. In the afternoon, it was between 27-280 C, and around 24-26 0 C at night. The temperature was still within the normal range, and there was no significant change in temperature during the research process.

3.1.2 Humidity

Table 2. Average Humidity of Cage during Research

Week-	Average Humidity (%)			
	Morning (08.00)	Afternoon (12.00)	Afternoon (16.00)	Evening (21.00)
1	71	57	60	71
2	74	55	60	72
3	74	56	59	73
4	74	55	60	74
5	74	52	59	72
6	73	56	59	74
7	73	53	59	72

Based on Table 2. A comparison diagram of the average humidity of the cage environment during the study can be seen in Figure 2.

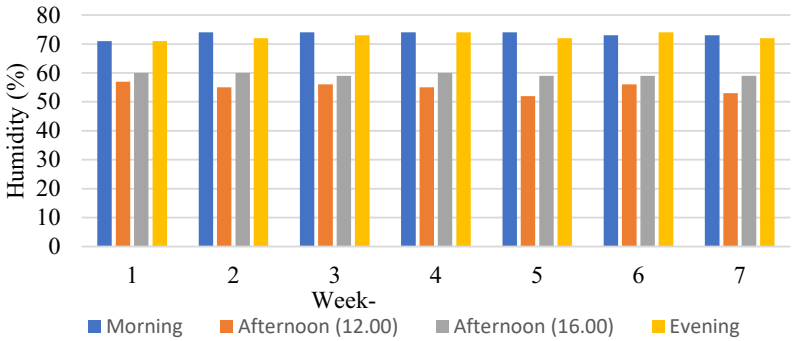

Fig. 2. Histogram of Mean Environmental Humidity during Study

Based on Table 2 and Figure 2, it can be seen that the average humidity of rat cages (*Rattus norvegicus* L.) during the study in the morning was in the range of 71-74%, in the afternoon it was in the range of 52-57%, in the afternoon was in the range of 59-60%, at night it was in the range of 71-74%. Environmental humidity is still within the normal range, and there is no significant change in humidity during the research process.

3.1.3 Average Number of Spermatogonium Cells

Based on research that has been carried out, the average number of spermatogonium cells of white rats (*Rattus norvegicus* L.) after administration of mangrove leaf extract at P0 (control), P1 (20 mg/kg BW), P2 (25 mg/kg BW), P3 (30 mg/kg BW) can be seen in Table 3.

Table 3. Average Number of Cells Spermatogonia White rat (*Ratus norvegicus* L.)

Treatment (mg/kg BW)	Test						Total	Average± SD
	1	2	3	4	5	6		
Control	72	70	73	69	70	72	426	71.00 1.54 [d]
P1	53	44	47	49	46	47	286	47.67 3.07c –
P2	27	28	30	33	34	32	184	30.67 2 .80 [b]
P3	19	18	16	19	22	20	114	19.00 2 [a.m]

Based on table 3. A comparison diagram of the average number of spermatogonia cells can be seen in Figure 3 below.

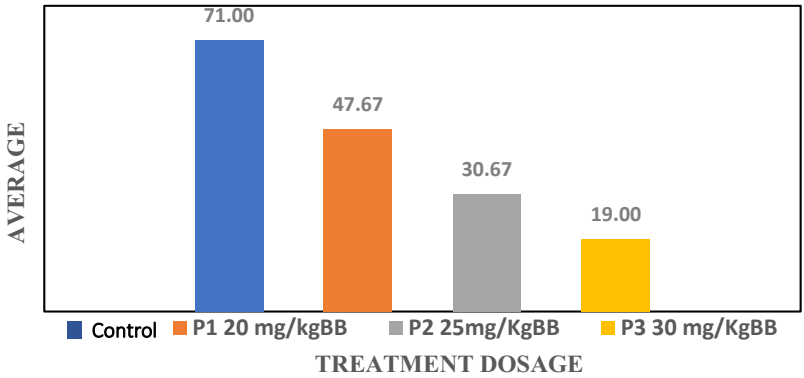

Figure 3. Diagram of the Mean Number of Spermatogonium Cells in White Rats after Administration of Mangrove Leaf Extract *Rhizophora apiculata* Blume

Figure 3 shows that the administration of mangrove leaf extract is inversely related to the decrease in the number of white rat (Rattus norvegicus L.) spermatogonium cells. It can be seen that the number of spermatogonia cells in the control group that were not given mangrove leaf extract showed the highest number, namely an average of 71 spermatogonia per seminiferous tubule in white rats (Rattus novergicus L.). Spermatogonia with around 47 spermatogonia in the seminiferous tubules in the 20 mg/Kg BW treatment, 30 spermatogonia per seminiferous tubules in the treatment 25 mg/Kg BW, and the lowest was 19 spermatogonia per seminiferous tubule at 30 mg/Kg BW treatment.

3.1.4 *Rattus norvegicus* L. Spermatogonium Cell Count

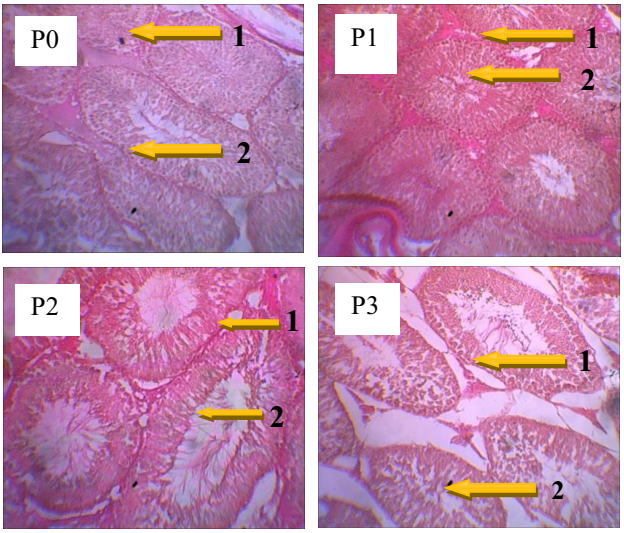

Figure 4. Spermatogonium cells. (1) Spermatogonium cells P0: (71 cells), P1: (47 cells), P2: (30 cells), P3: (19 cells). (2) Seminiferous Tubular Cells

3.2 Inferential Analysis

3.2.1 Hypothesis Test Results

The hypothesis test in this study is a parametric test Analysis of Variance (ANOVA).

Table 4. Test the ANOVA hypothesis of research data

ANOVA						
Number of Spermatogonium Cells						
Source of Diversity	Sum of Squares	db	Middle square	F_{count}	F_{table}	Sig.
Treatment	9183.167	3	3061056	11 5908	3.02	.000
Error	118,667	20	5,933			
Total	9301833	23				

Based on Table 4, it can be seen that the calculated F value > F table = 115,908 > 3.02 and sig. = 000 < α (0.05), then H0 is rejected and H1 accepted, it means extract of Mangrove leaf Rhizophora apiculata Blume has a negative effect on the number of Spermatogonium cells of white rats (Rattus norvegicus L.). Based on the results of the hypothesis test, it is continued, where the hypothesis test is proven to have an effect, it is continued with the Tukey-HSD follow-up test.

3.2.2 Tukey-HSD follow-up test

Table 5. Tukey's Further Test Results

Spermatogonia cells				
Tukey' All Pairs Comparison				
comparison	Mean Differences	| q |	P	95% CL
P0 vs. P1	23,333	32.6202	<.0001	19,397 to 27,296
P0 vs. P2	40,333	27.4108	<.0001	36,397 to 44,296
P0 vs. P3	52,000	24.7714	<.0001	48,063 to 55,936
P1 vs. P2	17,000	7.6155	<.0001	13,063 to 20,963
P1 vs. P3	28,666	2.4161	<.0001	24,730 to 32,602
P2 vs. P3	11,666	5.1541	<.0001	7,730 to 15,602

Based on Table 5, it is known that P0 has a significant effect on P1, P2, P3, and P1 (20 mg/Kg BW) has a significant effect on P2 and P3, and P2 (25 mg/Kg BW) has a significant effect on P3 (30 mg/Kg BW).

4. Discussion

Based on the results of research that has been carried out, the average number of spermatogonia cells in the histological appearance of the rat testes white (Rattus norvegicus L.) showed a decrease in the number of spermatogonia cells from each treatment compared to the control. The average number of Leydig cells in the P1, P2, and P3 groups was statistically significantly different from the control group. Mangrove leaf extract Rhizophora apiculata Blume was given to rats at doses of 20 mg/Kg BW, 25 mg/Kg BW, and 30 mg/Kg BW, and the control group reduced the number of Spermatogonium cells due to the presence of metabolites. The metabolites contained in the mangrove leaf extract of Rhizophora apiculata Blume, such as flavonoids, steroids, alkaloids, tannins and saponins [9], including other secondary metabolite compounds such as phenolics, chlorophyll and carotenoids, which have the potential to be antibacterial, antimalarial, antiviral and antioxidant and can treat the degenerative disease diabetes mellitus [10]. Tambengi et al., [11] that the metabolite content has the potential as an antifertility agent. Apart from that, mangrove plants also have a role as plants that can cure various diseases, including being used as medicine for stomach aches and heartburn. The parts of the plant used are the leaves, flowers and fruit [12].

The decrease in spermatogonium cells was thought to be due to compounds found in mangrove leaves. Flavonoids and alkaloids have estrogenic ability to inhibit the hormonal process of spermatogenesis. These compounds cause inhibition of the release of Luteinizing hormone (LH) and Follice Stimulating Hormone (FSH) in the anterior pituitary, thereby affecting the function of spermatogonium cells in producing testosterone [13]. This is to the research of Nurlely et al., that alkaloids are thought to have anti-fertility properties. Antifertility compounds have a working mechanism through cytotoxic effects and hormonal effects so that they inhibit the rate of metabolism of spermatogenic cells due to disturbances in the balance of the hormonal

system [14]. Alkaloids can inhibit antioxidant activity in Leydig cells, thereby reducing the production of the hormone testosterone [15].

The decrease in spermatogenesis in the treatment was also thought to be due to the inhibition of the production of the hormone testosterone. In this case, the Flavonoid compounds in the extract stimulate estrogen synthesis in mammals because their chemical structure is similar to that of estrogen. So that it can cause a decrease in FSH and LH production, and a decrease in LH synthesis will trigger a decrease in hormone synthesis by the Leydig cells in the testes [5].

The seminiferous tubules start from the spermatogonia in the basal layer to the spermatid head in the distal lumen. The active substance, cucurbitacin, has a structure similar to a steroid. So that it can reduce testosterone levels and affect spermatogenesis, decreasing spermatogenic cells causes a decrease in the thickness of the seminiferous tubules [16]. The content of mangrove leaf extract can reduce high blood glucose and can repair damage to the thickness of the spermatogenic cells of the seminiferous tubules [17].

This is to the research of Susetyarini [18], concluding that the number of spermatogenic cells is the number of spermatogonia cells, primary spermatocytes, secondary spermatocytes, spermatids and spermatozoa which are located in the seminiferous tubules which indicate the process of spermatogenesis is the number of spermatid cells and spermatozoa.

Spermatogenesis disorders can be caused by internal factors (age, psychology, hormones and genetics) or external factors, while external factors (temperature, nutrition, and environmental pollution. Moreover, one of the leading causes of disruption of the process of spermatogenesis in the testes is the presence of free radicals. There are two sources of free radicals: endogenous and exogenous [6]. This is to the research of Harlis et al., that giving mangrove stem bark extract is the part that has the most potential as the highest antioxidant in mangrove stem bark can capture free radicals. Free is a tannin compound [4].

Furthermore, free radicals, including the testes, will participate in blood circulation and circulate throughout the body. There are two ways that free radicals can damage gonadal cells, namely by damaging the cell membrane. The gonadal cell membrane contains a lot of unsaturated fatty acids, which are prone to lipid peroxidation, besides that, the cytoplasm in the gonad cells contains only a few enzymes that can neutralize free radicals. Lipid peroxidation will cause loss of membrane integrity, inactivation of cellular enzymes, damage to DNA structures, and cell apoptosis [19].

The results of the ANOVA test with a confidence level of 95% showed differences between each treatment group. Analysis of the average number of white rat spermatogonium cells obtained Fcount 1 15,908 > Ftable 3,02. This shows that there are differences between each treatment group. Then, the LSD and Duncan follow-up tests were carried out with a 95% confidence level contained in the appendix to see whether there was a significant difference or a significant difference between each treatment group.

The observational picture shows that the number of white rat spermatogonium cells experienced differences between each treatment, where the highest difference was seen in the P0 treatment without being given a dose, and it can also be seen that it decreased compared to the treatment along with the added dose of mangrove leaf extract given. This statement is to the results of research where there was a decrease in the highest number of spermatogonia cells in the treatment P0 with an average number of 71.00.

This supports the success of the reproductive process, namely the reproductive organs and normal reproductive hormone levels. The presence of free radicals can cause a decrease in the hormone estrogen. Free radicals are reactive oxygen compounds with

unpaired electrons [20]. His research stated that mangrove leaves contained a lot of triterpenoid-type terpenoids, containing Na, K, Ca, Mg, phenols, steroids/triterpenoids, saponins and tannins [21]. Inhibition of spermatogenesis cells through the action of toxic compounds, which cause the death of spermatogenic cells, resulting in a decrease in the number of spermatogenic cells. The mechanism of hormonal action is inhibiting the secretion and action of reproductive hormones, namely LH and FSH. Sertoli cells have a characteristic pyramidal shape, with the cell base attached to the lamina basalis and the apical end protruding into the tubular lumen [22].

5. Conclusion

Based on the results of the research that has been done, it can be concluded that the administration of Rhizophora apiculata mangrove leaf extract Blume has a significant negative effect on decreasing the number of spermatogonium cells of white rats (Rattus norvegicus L.). The decrease in the number of spermatogonia cells is made possible by the presence of substances such as flavonoids, saponins, alkaloids and tannins, which work as antifertility through hormonal effects which reduce the number of spermatogonia cells.

Acknowledgements

The authors wish to thank and acknowledge, first, the Head of Laboratory Universitas Halu Oleo for generously supporting this project and, second, thank Laboran Universitas Halu Oleo for supporting the volunteers and data collection team.

References

1. Khozin FA., Fadillah BC., Purnama MQE., Malnutrition Can Reducing Male Mice Libido Frequency, Journal of Veterinary Medicine, Vol. 1(1), pp. 28, 2017.
2. Akmal, Y., and Mahfud, Spermatogenensis and Testicular Histology of Male Pangolin (Manis kavanica), Journal of veterinary medicine, pp. 570-57, 2019.
3. Wahyudi, D., Zakinah, A., Alhaddad., and Alexander, WT., Bioactivity Antibacterial From Leaf Extract Mangroves Avicennia SP. Marine Journal, Vol. 12(1), pg. 12-13, 2019.
4. Harlis, WO., and Septiana, A., Histology of Mice Testes (Mus muscle L.) After Administration of Brotowali Plant Extract (Tinospora crispa L.), Biowallacea. Vol. 4(1), pp. 558–565, 2017.
5. Pranadya, NME., Setyawati. I., and Hastuti, YDA., Number of Spermatogenic and Histological Cells in Mice (Mus musculus L.) Testes After Administration of Red Calliandra Leaf Extract (Calliandra calothyrsus Meissn) at Different Doses and Time Intervals, Udayana Biology Journal, vol. 23(1), pp. 34-41, 2019.
6. Anzila, I. Agung PWM Aris S. Sri R., The Effect of Ethanol Extract of Basil (Ocimum canum Sims.) on the Histological Structure of Male Mice (Mus musculus) Testes, Journal of Biotropica,vol. 5(1), pp. 25, 2017.
7. Sugiyono, Research Methods Quantitative, Qualitative and R&D, Alphabet, Yogyakarta, 2014.
8. Kristanti, Y., Wayan, IRW., Dewa, IGMP., The Effect of Extraction Time and Ethanol Concentration Using the Microwave Assisted Extraction (Mae) Method on the Anti-Oxidant Activity of Corn Hair Extract (Zea mays L.), Journal of Food Science and Technology, Vol. 8(1), pp. 95-96, 2019.
9. Saputra MY., Zakaria MR., Silalahi D., Sartika W., Hasibuan HFZ., Kurniawan R., Sukrasno S., Potential Antioxidant Constituent from Leaf of Rhizophora apiculata an Typical Mangrove at Lempasing, South Lampung Coast, Stannum: Jurnal Sains dan Terapan Kimia, vol. 4(2), pp. 60-67, 2022.

10. Usman U., Fildzania D., Fauzi I., Uji Aktivitas Antioksidan dan Antidiabetes Ekstrak Daun Mangrove Rhizopora mucronata: Antioxidant and Antidiabetic Activity Testing of Mangrove Leaf Extracts (Rhizopora mucronata). Jurnal Sains Dan Kesehatan, vol. 4(1), pp. 28-35, 2022
11. Tambengi RA., Naki MI., Abdullahet A., Bioaktifitas Senyawa Metabolit Sekunder yang Berpotensi Sebagai Antifertilitas, FAJR: Jurnal Riset Kefarmasian, vol. 1(1), pp. 49-56, 2023.
12. Wiwi Y., Irma L., Populasi Rhizophora apiculata BI di hutan mangrove, Jurnal ekosistem mangrove, vol. 3(1), pp. 2, 2017.
13. Alghazeer R., Elgahmasi S., Aljazzaf B., Alansari WS., Al Griw M., Sidati M., Altarrah D., elhensheri M. Elnfati AH., Investigation of the potential anti fertility activity of Arbutus pavarii in male mice, Acta Poloniae Pharmaceutica and Drug Research, vol. 77(5), pp. 725–735, 2020.
14. Nurlely N., Aslama, AI., Cahaya N., Srikartika, VM., Efektivitas Ekstrak Etanol Kulit Batang Pakan Banyu (Croton argyratus Blume) terhadap Kualitas dan Kuantitas Spermatozoa sebagai Antifertilitas. *Jurnal Pharmascience*, vol. *9*(1), pp. 29-39, 2022.
15. Ruspawan DM., Bakta IM., Karmaya INM., Satriyasa BK., Arijana IGKA., Ethanol extract of young papaya seeds (Carica Papaya L) lower the level of testosterone, spermatozoa count and expression of androgen receptors in sertoli cells of adult mice (Mus Musculus). Biomedical and Pharmacology Journal, vol. 14(1), pp. 207–213, 2021.
16. Yasmin, N., Dewi, MK., Ekowati, RAR., Purbaningsih, W., and Herdiningrat , RBS, Influence Provision of Bitter Gourd Ethanol Extract (Momordica charantia L) Against Seminiferous Tubular Network in Male Mice (Mus musculus L.), Journal of Health and Science Integration, vol. 1(2), pp. 161–165, 2019 .
17. Larasati D., Sutyarso NN., Hendri B., Pengaruh Ekstrak Daun Sukun (Artocarpus altolis (Park Fosberg) Terhadap Populasi Sel Spermatogenik, Diameter dan Tabel Epitel Tubulus Semineferus Mencit (Mus musculus L.) yang Diinduksi Aloksan, Jurnal Prosiding Seminar Nasional Perhimpunan Biologi Indonesia, vol. 1, pp. 148-149, 2019.
18. Susetyarini, E., Latifa, R., Zaenab, S., Nurrokhman, E., Animal Embryology and Reproduction. UMM Press: Malang, vol. 15(2), pp. 463, 2020.
19. Nabilah, H., and Witjahjo, B., Influence Extract Skin Fruit Dragon White (Hylocereus Undatus) Against Description Microscopy Testicles Mice strain Balb/C Which given exposure Drug Mosquito Burn, Journal Medical Diponegoro, vol. 5(4), pp. 982–993, 2016.
20. Simatauw, AZ., Adrien Jems, AU., Description of the Estrus Cycle of Rats (Rattus norvegicus) Exposed to Cigarette Smoke After Being Treated with Ethanol Extract of Kebar Grass (Byophytum Petersianum Klotzsch), Journal Biological Pattimura Rumphius, vol. 1(1), pp.1, 2019.
21. Guntara, S., Analysis of Compound Content of Mangrove Leaves in Tanjung Sebauk Village, Vol. 2(1), pp. 7, 2019.
22. Avycena, S,. Agung, JS., Siti, MM., Structure of the Semineferal Tubules of Mice (Mus musculus L.) After Exposure to Ethanol Extract of Neem Leaves (Azadirachta Indica A Juss), Journal of Pro-Life, vol. 7(1), pp. 42-43, 2020.