



# Importance of Using Natural and Synthetic Sutures in Wound Healing in Gastrotomy Surgery in Dogs

Botir Ulmasov\*<sup>1</sup>, Baxtiyor Narziev<sup>2</sup>, Asadulla Mamatkulov<sup>1</sup>, Faxriddin Boltayev<sup>1</sup>, Ismoil Abdurahimov<sup>1</sup>

<sup>1</sup>Tashkent State Agrarian University, Tashkent, 100140, Uzbekistan

<sup>2</sup>Samarkand State University of Veterinary Medicine, Animal Husbandry and Biotechnology, Samarkand, 140103, Uzbekistan

doc-ulmasov@mail.ru

**Abstract.** It is known that among pets, dogs are regularly used in the activities of kennel service bodies, and the health of service dogs and dogs in the care of the population, most of the internal non-communicable diseases among them are related to diseases of the digestive organs. This type of disease also leads to a decrease in the quality of service for dogs. This article discusses the impact of foreign bodies on the body of domestic animals, including dogs, the effect on the physiology of the digestive system, the ineffectiveness of traditional treatments, the advantages of surgical methods, surgical techniques, and the effect of various suture materials on wound healing, adhesion of sutured tissue in international veterinary practice. scientific research, use of international experience in the veterinary field of Uzbekistan in the treatment and prevention of diseases of the digestive organs, literature on the treatment of diseases of the digestive system using surgical methods, as well as operations on the stomachs of dogs. At the end of the article, the expected results of the use of sutures used in gastrotomy surgery in the stomach of dogs and the importance of scientific research in this regard are summarized.

**Keywords:** obstruction, gastrotomy, foreign bodies, diagnostics, surgery, operation, Shimiden-Lambert, sutures, pathology, regurgitation, intrathoracic esophagostomy, intraabdominal gastrotomy

## 1 Introduction

In recent years, the role of the Uzbek canine industry in maintaining the inviolability of state borders in Uzbekistan is invaluable. The role of veterinary specialists is also important in maintaining the health of animals serving in the field of cynology and overcoming various adverse conditions in their quality care [1]. In recent years, it is

noteworthy that not only in the state canine service, but also in the care of our population, pets, especially dogs, are taken care of [2]. As a result of the increase in the number of pets and the shortcomings in the care and maintenance of dogs, there are cases of iodine consumption by animals in the digestive system of dogs. The use of surgical methods in the elimination of such cases achieves good results. Such operations are performed in the gastrointestinal tract, which is part of a series of operations performed in the abdominal area [3].

Today, several methods have been developed in veterinary surgery to prevent the occurrence of purulent processes in wounds after surgical procedures. These include the use of quality and non-invasive suture materials in wound suturing [4]. The success of abdominal surgery in dogs depends on the materials used to suture the wounds. In this case, it is necessary to know the properties of welding materials and follow the requirements for them [5]. The training literature on veterinary surgery provides information on the main sutures, nodular, horny, circular, Plakhotin-Sadovsky, Schmiden, Lambert, and Pirogov-Cherni used in several different surgical practices. They are used in abdominal surgery [6].

The use of new synthetic surgical suturing materials with postreocytogenic properties is a pressing problem of modern veterinary surgery. Most of the more than 50 local and foreign suture materials currently used by surgeons do not meet the general requirements. According to such scientists [7, 8], increasing the number of stitches does not reduce the number of complications. Therefore, in order to obtain short-term and long-term results, it is necessary to master the methods of suturing and use methods that do not affect the physiological processes in the tissues.

During the closure of the body, the surgeon's task is to ensure the wound healing, the anatomy of the organ, the maintenance of the blood vessels, and its functioning. The current trend is to use an "anatomical" closure of the organ, which allows wounds to heal without provoking secondary inflammation. The mucous layer of the hollow organs plays a major role in wound closure [9].

Absorbent materials in gastrointestinal and urogenital surgery replace non-absorbable monofilament materials (i.e. polyamides or polypropylene) (Bernard Bouvy DrMedVet, MS, DipECVS, DipACVS Gilles Dupry DrMedVet, DipECVS "Soft tissue suture technique: current Frege V guidelines for Paris and cats", France 2020) [9]. It is not recommended to use non-absorbable materials and catgut when suturing internal organs, as this type of suture material can cause inflammatory reactions. The methods of examination currently used in the diagnosis of animal diseases and the degree of accuracy of these methods in the diagnostic process are important [10]. The importance of diagnosing animal diseases is to eliminate the factors and conditions that can cause disease in animals by expanding the possibilities of early detection of diseases occurring among animals and early detection of general and local changes in the organs [11]. The examination methods were performed on an ultrasound machine apparatus, in which the area of the dog's abdomen was seen at a frequency of 4.5 migo Hertz in a dachshund adapted for external examination of the internal organs. During the examination, the dunes on the skin around the abdomen were shortened, treated with antiseptic, and the internal organs were examined by imaging using a special gel.

## 2 Materials and methods

The experiments were conducted in the veterinary clinic of the Department of Zootechnics, Faculty of Zooengineering at Tashkent State Agrarian University in Uzbekistan. Dogs with peptic ulcer disease or ingestion of foreign bodies kept in the kennel of the canine service of the Tashkent province police were selected as material. During the experiments, gastrotomy was performed in 6 dogs of different breeds. The experimental dogs were divided into 2 groups of 3 heads. The gastric injury of the dogs in the first group was stabbed with a two-ply Schmiden and Lamber stitch. We used synthetic lavsan stitching materials as the stitching material. The Schmiden suture was a continuous suture, and the first layer of wounds in the stomach and colon was sutured, and the second layer was applied Lamber suture (Table 1).

The injuries of the dogs in the second group were stabbed with a single-layer Lamber stitch. Silk stitching material was used as the stitching material. Based on the results of our personal experience, we recommend that the methods used for suturing during operations on the gastrointestinal and urogenital organs are described. Monofascial closure of the abdominal wall is considered.

**Table 1.** Dog breeds and chopping materials and methods obtained in the experimental group.

№	Dog breeds	Number of dogs taken into the experimental group	Group 1	Group 2
1	German Shepherd	1	+	
2	Central Asian Shepherd	1		+
3	Belgian Shepherd	1	+	
4	Kokker spaniel	1	+	
5	East European Shepherd	1		+
6	Local dog breed	1		+
<b>Total</b>		<b>6</b>	<b>3</b>	<b>3</b>

The number of stitches that are important to sew in the organ should be sufficient, but it is advisable that the length of the wound is not too large. At present, we mainly use synthetic charcoals that are absorbed by hydrolysis processes. These materials are non-capillary (i.e. monofilament) or slightly capillary (sheathed polygonal) and also inert - i.e. they cause minimal inflammation and retain their strength in a confined environment. In accordance with the rate of soft tissue healing, the suture materials are important. The round atraumatic needle, combined with the high strength of the synthetic sutures, allows the use of thin threads to help ensure an atheromatic and reliable closure of the wound. The number of nodes present in a wound suture formed

in the stomach wall depends on the suture material selected and the type of suture used.

The hollow organs usually consist of four layers of tissue: the submucosal layer, the muscular layer, and the outer serous membrane. Scientific studies show that for all hollow organs (including the stomach), the mucous membrane plays a key role in wound closure because it contains large amounts of collagen [10, 11].

The suture should attach to the mucous layer for tight contact between the wound edges until complete recovery. To achieve this, there is often a risk of penetration into the inside of the organ cavity (excluding the bladder) and use of an unreliable mucosa rather than remaining “outside the mucosa” (Bernard Bouvy DrMedVet, MS, DipECVS, DipACVS Gilles Dupry DrMedVet, DipECVS “Soft tissue suture technique: current guidelines for dogs and cats” Frege Veterinary Clinic, Paris, France 2020) [9].

Over the last 10-15 years, there has been a trend to simplify suture techniques using the direct addition of different tissue layers. This method is designed to optimize the healing process by properly aligning different anatomical layers and minimizing stenosis after wound healing. A “classic” operation on the gastrointestinal tract requires two reverse layers (Cushing, Conell, and Lembert methods).

The use of conventional suture methods in operations on the gastrointestinal tract causes inflammation, does not ensure the formation of strong scar tissue after 5 days, and causes partial necrosis of the mucous membrane before its recovery. The usual stitching technique is designed to increase the final diameter of the wound. The stitches are less severe, they stimulate inflammation and stickiness around the post-operative tissue scar, and often slow the recovery of the mucous membrane.

Numerous studies by scientists from international experience have shown that direct side-by-side (joining) without crushing the cut edges of the hollow organ quickly leads to the formation of waterproof tissue adhesion, good histological treatment and minimal inflammation. The current technique of closing wounds in the abdomen follows the same rule. If possible, an omentum should be used to close the scar, so “mentalization” should be applied. It helps to thicken blood vessels, lymphatic drainage and wounds. In partial opening of the wound, the omentum often prevents local bacterial contamination from becoming a more widespread infection [6-8].

In a recent article, it was reported a method of wound closure with a two-layer simple joint suture. According to this method, a good compression was formed from the beginning, along with the anatomical covering of the various tissue layers [11]. Closure of the wound was done by carefully closing it and not allowing the edges to bulge. The stitches are rectangular, consisting of four nodes, located at a distance of 2-3 mm from each other. In the first layer, the sutures penetrated the mucous and submucosal membranes; the sutures were located in the wall of the esophagus. The second layer covered the muscles and the outer shell, the nodes facing outwards. If short-term anesthesia is critical to the animal’s survival, then an alternative is to close the wound in one layer with simple-style sutures along the entire thickness of the esophagus. This ensures a good balance between effective treatment and the choice of tissue fusion method. Conversely, conventional sutures should be avoided because they do not provide the same level of healing and as a result the tissue closes less satisfactorily. The reverse suture technique, although clinically accepted, is not anatomical and is therefore less satisfactory.

### 3 Results

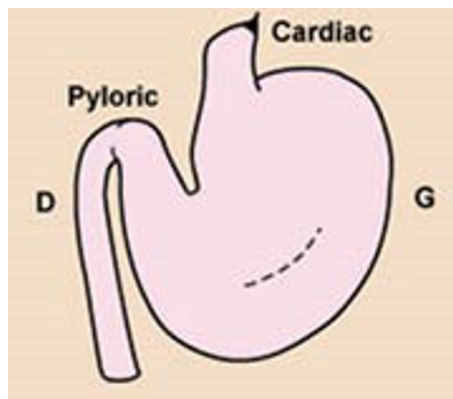
Gastrotomy is one of the most common abdominal surgeries in animals with a single-chamber stomach in veterinary practice, the main purpose of surgery is to detect gastric diseases, remove foreign bodies, wounds and tumors from the stomach.

The operating table is fixed on the back of the animal in a supine position. Anesthesia is performed by neuroleptanalgesia. To do this, a solution of 2.5% aminazine and 2% ketamine is injected intravenously or intramuscularly. Local anesthesia is performed by infiltration (saturation) with 0.5% novocaine solution along the incision line. A laparotomy is performed to penetrate the abdominal cavity. To do this, we made a medial incision in the anterior part of the umbilicus.

The use of a soft suture technique only makes sense if the atrophic surgical technique has been used before. These guidelines require careful handling of tissues to prevent thrombosis and necrosis at the wound edges, as well as careful maintenance of homeostasis, which reduces the likelihood of hematoma formation, which can lead to infection and enhance collagenolysis.

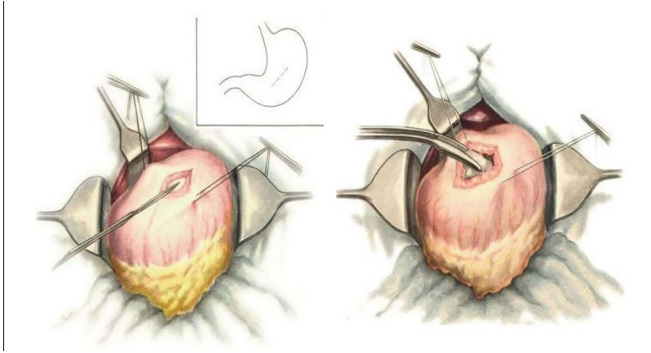
The recommended suture material to close gastric incisions should be inert, absorbent, and well stretchable. Recoverable multifilament polyglycolic acid or polyglactin-910 coated materials, as well as polyglyconate or polydioxanone impregnated monofilaments, are very suitable. It is preferable to use round needles or small-diameter conical needles with an inner thread, suitable for cats and dogs of almost all sizes, 2 or 3 decimal sizes (USP3-Oili2-0).

The gastric incision is made in the midline at an equal distance from the small and large curves of the stomach, on its ventral surface (Figure 1).



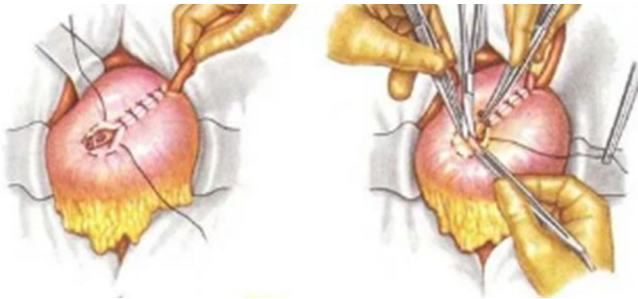
**Figure 1.** Determination of the ventral surface of the stomach of dogs.

Supportive sutures should be placed at the site of the gastric incision or gastrotomy so that the incised tissue is lifted over the abdomen and then removed with absorbent compresses (Figure 2).



**Figure 2.** Surgery in the stomach of dogs.

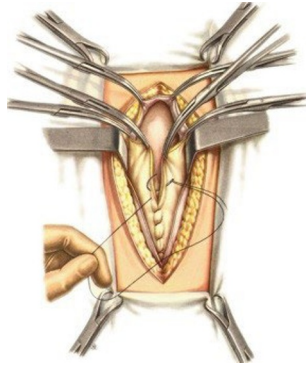
Although normal intermittent sutures can be used in the stomach, as in all small-diameter hollow organs, tissue stenosis does not make gastrotomy or partial resection too difficult. However, most surgeons, including the authors, prefer a 2-layer closure of the wound to prevent bleeding and hemorrhage. Closing the wound is done without wrinkling the tissues, only by carefully touching them. A simple continuous suture (Capella type) is passed through all four layers, and then the Lember suture method on the sero-muscular membrane is applied to the second layer (Figure 3).



**Figure 3.** Chapel and Lamber stitching.

For the gastrointestinal anastomosis technique, wound closure in two layers has been shown to increase the risk of tissue adhesions and significantly increase the duration of surgery. It is recommended to use simple, continuous, nodular sutures throughout the thickness, as it has been shown that there is no difference between a gastric anastomosis performed in one layer and suture in two layers (leakage of wound edges or difference between wound edges) (Figure 3). The site of the gastric suture should be covered with a second layer connected by several single sutures in the serous- muscular layer placed at the surgical site.

Almost all procedures involving the abdominal cavity are performed by incision along the ventral midline at a distance to the white line of the abdomen. It may be helpful if the subcutaneous fat separates from the external abdominal fascia during the initial incision and is cut 0.5-1 cm; this ensures that not only the oil itself but also the outer fascia enters the wall seam (Figure 4).



**Figure 4.** Stitching of facies.

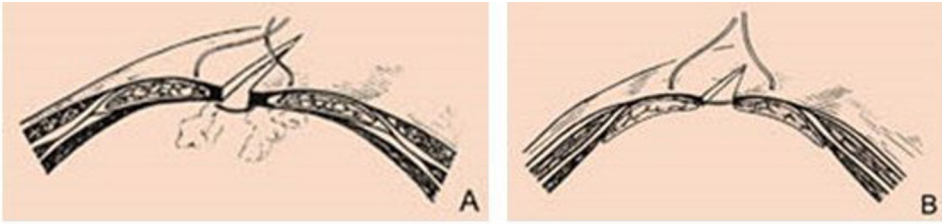
The standard method of closing a wound in the abdominal wall is to connect these hollow layers and the inner and outer fascia with a single suture. This approach is adequate and safe, but it is time consuming and involves inserting a large amount of suture material into the wound. In addition, suturing of the internal fascia poses a risk of adhesions in the peritoneum. The stimulus for this is not only damage to the peritoneum, but it can also facilitate ischemia caused by peritoneal sutures. Biomechanical studies in dogs have shown that the strength of the abdominal scar is the same when suturing the inner and outer fascia and only when suturing the outer fascia.

Extensive clinical experience and scientific research by Crowe and Rosins has led to the widespread use of suturing techniques to close the wound in only one fascia when suturing the abdominal cavity. This method is simple and safe, leaving less suture material in the wound than those described above [8-11]. According to this technique, only permanent suturing is applied to the outer section of the abdomen (Figure 4).

For implementation, both absorbent coated polyglycolic acid or polyglactin-910 multilayer yarns, as well as absorbable polyglycate or polydioxane monofilament yarns are suitable. Non-absorbent nylon or polypropylene sutures can also be used, but they remain in the wound forever even after they have lost their mechanical properties. Catgut should be avoided with steel wire or non-absorbent multifilament wire.

The size of the stitching material used varies depending on the weight of the animal: for example, for cats and small dogs, the size of the stitching is ten (LISP 3-0), for medium-sized dogs - 3 with the size of the stitch (LISP 2-0). Decimal size 4 (LISP O) is used for large dogs and finally for very large dogs 5 (USP 1) for fractional size.

Knots at the beginning and end of a continuous seam should be done very carefully. The first suture is attached to the edge of the fascia without twisting. Additional knots (knot 4 at the beginning of continuous stitching, 6 to its end) are tightly tied and the loose ends are cut, leaving a length of 4 mm (1) (Figure 5).



**Figure 5.** Starting point of continuous stitches.

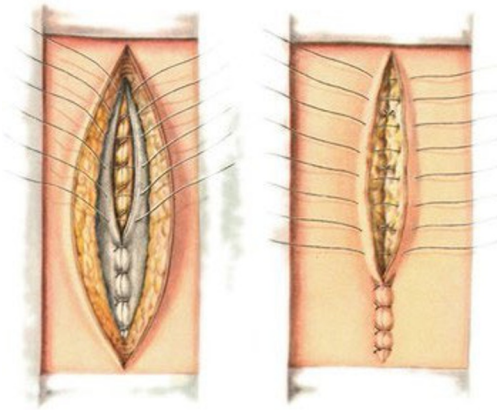
In the front two-thirds of the suture, sutures are made along the entire thickness of the white line, and avoid touching the edge of the white line, as this may prevent the wound from healing. In the caudal third, the sutures cover only the outer fascia of the abdomen without touching the muscle fibers to prevent abdominal necrosis. The width of the stitches is 3-10 mm; they are located at a distance of 5-10 mm depending on the size of the animal. When performing continuous stitching, the fascia folds are closed only without tension. If the fascia is sutured too tightly, the strength of the scar will decrease.

The skin and the layers beneath it were cut to the peritoneum. Care should be taken when cutting the peritoneum, for which the abdominal wall is raised using surgical forceps and cut 1-2 cm with a scalpel, two fingers or apricot probes are inserted into the resulting hole and enlarged to the length of the incision [5]. The length of the wound can be 10 centimeters or more, depending on the size of the animal. Once the path to the abdomen is opened, the fat on the stomach is absorbed. A site or foreign body is then found with the ulcer and the stomach is removed to the outside on a pre-sealed napkin against the abdominal wall. The foreign body is absorbed into the area where the stomach is less vascularized, with the exception of ulcers. In order to prevent bleeding from the stomach wall, a bowel incision is placed under the foreign body or wound. The stomach wall is cut using a scalpel or scissors, and in the case of a wound larger than a foreign body, it is cut in a spatial manner at the border of healthy tissue. After removal of the foreign body and the wound, the area around the wound is cleaned with a swab with 0.9% sodium chloride solution, especially the fluid in the stomach and blood clots are removed. This results in gastric ulcer [4].

The subcutaneous tissue is sutured with a simple continuous suture or Kushin suture, and the size of the absorbable sutures should be smaller than the size of the fascia suture material. The skin is sutured with a single continuous suture using simple cut sutures, non-absorbent material (e.g., nylon, polypropylene, or oiled silk threads) or surgical staples (Figure 6).

The injuries of the dogs in the first group were continuously stabbed by Schmiden and Lamber methods. Lavsan synthetic yarn was used as the sewing material. For the dogs of the second group, we used #2 silk thread made in Uzbekistan. The wound in the dogs' stomach was punctured with a single-layer serous-muscular lumbar puncture. After the surgery, the dogs were given warm water and a decoction of rice 4 hours later. Dogs were observed to have general condition, behavior, appetite, and littering for 7 days. However, symptomatic treatment was carried out for 7 days, for which 2 g of 4% gentamicin, 2 g of cerucal, 2 g of subcutaneous ascorbic acid and 1 teaspoon of phospholugel were given intramuscularly 2 times a day for 15-20 days before

meals. One of the dogs in each group underwent a laparotomy every 5 days to check the condition of the injury, and the dog in the first group was found to have significant redness and tissue swelling around the wound.



**Figure 6.** Stitching of the subcutaneous and subcutaneous layer.

In the second group of dogs, the tissues around the wound were red, and the swelling was noticeable. Within 10 days after surgery, all dogs underwent diagnostic laparotomy and were found to be recovering from gastric ulcers. Smooth in dog injuries in the first group; the pain from the scar was not felt, the general condition of the dogs was satisfactory. The dogs in the second group had a scar formed around the wound, but it was relatively rough and some areas were swollen. It was concluded that this condition was the result of suturing the wound with a single-layer Lamber method and the use of silk thread.

#### 4 Conclusion

It is advisable to use Copella, Schmiden, and Lamber sutures to suture the wound in the practice of gastrotomy surgery in dogs. Synthetic lavsan and silk threads are recommended for surgical use as a suture material. A comparative evaluation of the suture method and suture materials revealed that the wound scar was smooth, strong and had a low level of adhesion when using two-layer Kopella, Schmiden, Lamber suture and lavsan synthetic material. The use of natural tissue yarns in the binding of gastric wall wounds and other types of polymers, synthetic, PGA, LISP 3-0, LISP 2-0, LISP O, USP 1, the importance of wound healing in silkworms has been recommended.

**Disclosure of Interests.** The authors have no competing interests to declare that are relevant to the content of this article.

## References

1. A. S. Kashin, *J. Veterinary*, **4**, 9 (2001)
2. B. D. Narziev, *J. Veterinary medicine*, **2**, 11 (2019)
3. B. Bouvy, *Bovine Surgery and Lameness*, **12**, 8 (2005)
4. L. V. Medvedeva, *On the issue of using a single-row intestinal suture*, 119 (Nauka Press, Novosibirsk, 2004)
5. KH. K. Rustamov, YA. A. Akhbutaev, B. D. Narziev, *Operative Surgery*, **7**, 14 (1997)
6. L. P. Troyanovskaya, *Experience of using new suture material for veterinary medicine*, 142 (Nauka Press, Moscow, 1995)
7. K. I. Shakalov, I. A. Kalashnik, G. S. Mastyko, I. E. Povazhenko, B. A. Bashkirov, *Private veterinary surgery*, 297 (Kolos Press, Saint Petersburg, 2005)
8. B. Bouvy, *Frege Veterinary Clinic*, **2**, 8 (2020)
9. J. A. Au Yong, S. E. Kim, J. B. Chase, *Veterinary Surgery*, **48**(3), 343-351 (2019)
10. Z. Schwartz, B. R. Coolman, *Veterinary Surgery*, **47**(2), 285-292 (2018)
11. A. Atilla, *Companion Animal*, **22**(6), 332-337 (2017).

**Open Access** This chapter is licensed under the terms of the Creative Commons Attribution-NonCommercial 4.0 International License (<http://creativecommons.org/licenses/by-nc/4.0/>), which permits any noncommercial use, sharing, adaptation, distribution and reproduction in any medium or format, as long as you give appropriate credit to the original author(s) and the source, provide a link to the Creative Commons license and indicate if changes were made.

The images or other third party material in this chapter are included in the chapter's Creative Commons license, unless indicated otherwise in a credit line to the material. If material is not included in the chapter's Creative Commons license and your intended use is not permitted by statutory regulation or exceeds the permitted use, you will need to obtain permission directly from the copyright holder.

