Clinical Value of Ultrasonography in Screening Turner Syndrome(45,X) During the Second Trimester

PAN Yu-ping[1, 2,a]

[1]Medical College, Eastern Liaoning University, Dandong , Liaoning118003 China

[2]Department of Ultrasound, Shengjing Hospital of China Medical University, Shenyang ,Liaoning110004 China]

[a]email :Panxy900@sina.com

Keywords: Amniocentesis,Karyotypes analysis,Ultrasonography,Turner syndrome.

Abstract: Objective To investigate the clinical value of ultrasonography in screening Turner syndrome(45,X) during the second trimester.**Methods** Amniocentesis were performed on 3,948 pregnant women with indications for prenatal diagnosis to detect karyotype of the fetus during second trimester , The detection rate of Turner syndrome(45,X) was compared in pregnant women of different indications. To analyze the relationship between the ultrasonography abnormalities and Turner syndrome(45,X). **Results** In chromosomal karyotypes analysis of 3,948 pregnant women by amniocentesis,8 Turner syndrome were detected, the detection rate of Turner syndrome was 0.20%， There were 120 in 3,948 pregnant women with ultrasonography abnormalities.2 Turner syndrome(45,X) were found of them and the detection rate of Turner syndrome (45,X)was 1.67%, the detection rate of Turner syndrome (45,X)detected by ultrasound (1.67%) was higher than advanced age group(0.11%)， the Down's syndrome high risk group(0.06%)(P ＜0.05). **Conclusions** During the second trimester, ultrasonography has great value in screening Turner syndrome (45,X).

Introduction

Turner syndrome is a rare malformation,the incidence of1/3500～1/2500,a higher mortality rate,at present ultrasound has become the main means of screening. To explore the clinical value of ultrasonography in screening Turner syndrome(45,X) during the second trimester through the analysis of 3,948 cases of pregnant women's amniotic fluid cell karyotype.

Clinical data and Methods

Clinical data all subjects are pregnant women sought medical examination or consultation in Shengjing Hospital of China Medical University. Three thousand nine hundred eighty seven patients with amniocentesis indications were included from January 5, 2008 - October 22, 2010, aged 19~48 years, with a mean age of (31.9 ± 5.8) years old and 17 ~ 24 weeks of gestational age. Indications of amniotic fluid puncture ,that is indications of prenatal diagnosis, including: advanced maternal age (35 years old and above), high risk of Down syndrome (rate≥1/270), abnormal ultrasound findings, high risk of neural tube defects (NTD) and 18-trisomy syndrome, abnormal pregnancy history, history of chromosomal abnormalities of the parents. All pregnant women signed informed consent for post-puncture karyotyping analysis.

Methods

Sample collection and cell culture: ultrasound-guided amniocentesis was performed and 20~30 ml amniotic fluid was drawn for laboratory culture.

Chromosome karyotype analysis: after G-band staining, cultured cells were observed and 15~30 metaphase images were counted. Three to five karyotypes were analyzed and abnormal karyotype was carefully observed and analyzed.

I have obtained permission from my institution's ethics committee to perform this study and approval

from my institutions review board or ethics committee.

Instruments and ultrasound methods: Voluson E8 ultrasound diagnostic apparatus by GE company was used, with probe frequency of 4~6 MHz. Through abdominal multiplanar scanning, fetal head, face, neck, chest and abdomen, internal organs, limbs and spine etc. were scanned and suspicious sites were carefully observed. During follow-up, routine measurement of relevant data was performed including fetal biparietal diameter, limb length, amniotic fluid volume and placental thickness etc. Results were recorded.

Statistical analysis: SPSS13.0 software was used for statistical analysis. Count data of each group were compared using χ^2 test and P <0.05 was considered statistically significant.

Results

Cell culture: 3987 pregnant women received amniocentesis, and amniotic fluid cell culture was succeeded in 3948 patients, with a success rate of 99.02%.

Chromosome karyotyping of pregnant women: amniotic fluid cell karyotyping was analyzed in 3948 patients, and Turner syndrome was detected in 8 patients, with a detection rate of 0.20%. The detection rate of Turner syndrome in patients with amniotic fluid puncture indications was shown in Table 1.

Table 1.Amniotic fluid puncture indications and the detection rate of Turner syndrome in 3948 pregnant

Amniotic fluid puncture indications	Patients Number (n)	Other karyotype besides Turner syndrome(45,X) (n)	Turner syndrome(45,X)(n)	the detection rate of Turner syndrome(45,X)
Abnormal ultrasound	120	118	2	1.67
Advanced maternal age	910	909	1	0.11
High risk of Down syndrome	1,564	1,563	1	0.06

χ^2 test found that the detection rates of Turner syndrome among groups were significantly different (χ^2=18.773 and P＜0.001). Inter-group comparison by χ^2 test found that Turner syndrome(45,X) detection rate of the abnormal ultrasound group (1.67%) was significantly higher than that of the advanced maternal age group (0.11% ,χ^2=8.848, P=0.003)and the Down syndrome high risk group (0.06%, χ^2=16.099, P＜0.001) .

The relationship between 8 cases of Turner syndrome karyotype and amniotic fluid puncture indications are shown in Table 2

Table 2.The relationship between karyotype of 8 cases of Turner syndrome and amniotic fluid puncture indications

Maternal age and gestational age	Amniotic fluid puncture indications	karyotype of Turner syndrome(45,X)
23-year-old,20weeks+5	Fetal nuchal fold thickening	**45,X**
31-year-old,20weeks+2	Fetal edema,neck cystic mass,ascites and pleural fluids	**45,X**
31-year-old,20weeks	High risk of Down syndrome 1/7	**45,X**
37-year-old,21weeks	Advanced maternal age	**45,X**
32-year-old,22weeks	High risk of Down syndrome 1/150	**45,X(81) /46,X X(19)**
38-year-old,22weeks	Advanced maternal age Combined with High risk of Down syndrome 1/250	**45,X(24) /46,X X(76)**
39-year-old,20weeks	Advanced maternal age	**45,X(11) /46,X X(89)**
38-year-old,21weeks	Advanced maternal age	**45,X(5) /46,X X(33)**

The relationship between Turner syndrome and ultrasound abnormality In this study, Turner syndrome (45,X)ultrasound abnormality NF thickening one cases;fetal neck cystic mass with Fetal edema and Ascites and pleural fluids 1 cases.

Discussion

Common methods for prenatal diagnosis of chromosomal abnormality include serum screening, ultrasonography and karyotype analysis, the first two as non-invasive examinations and the last one as invasive examination, which is considered the gold standard for prenatal diagnosis . Invasive prenatal diagnostic techniques have certain risks. Since most of chromosomal abnormality fetuses are delivered by reproductive age women , non-invasive screening methods have grown in popularity. Serum screening has certain shortcomings, while fetal Turner syndrome (45,X) can have fetal morphology and anatomy of the malformation. Therefore, the inspection of Turner syndrome (45, X) with ultrasonography screening is preferred.

Turner syndrome, also known as congenital ovarian hypoplasia syndrome, belonging to the sex chromosome number and structural abnormalities, leads to ovarian hypoplasia and the appearance of female secondary sexual characteristics dysplasia or no development and certain congenital malformations of a group of diseases. There are many of its karyotype, and(45, X) is the most typical. Turner syndrome is divided into two categories,
fatal(karyotype 45, X) and nonfatal(more for other karyotype chimera). 10% of Turner syndrome embryos abort in early pregnancy. Intrauterine fatality rate was 75% during 12 to 40 weeks of pregnancy.

The ultrasonography of Turner syndrome (1)Neck cystic lymphangioma ,also known as lymphatic hygroma of the the neck is lethal Turner syndrome the main characteristic performance. It is divided into non-separate hygroma(mainly as a single cystic mass,usually located on both sides of anterior Department, its volume much smaller,easily missed.)and separated hygroma (Showed as multiple cystic mass,there are strong echoes with a clear separation)(Figure 1.) Sometimes the cyst is divided into two halves, which is separated by only a single visible central hyperechoic band.Most of the cysts are big,mostly found in back of the neck,occasionally located in the anterior Department.axillary and mediastinal. There are separate hygroma is often associated with chromosomal abnormalities, cardiovascular malformations and fetal edema.The most common chromosomal abnormalities, cardiovascular malformations and fetal edema.The most common chromosomal abnormalities as Turner syndrome(45,X) accounted for 75%, 5% of which is 18-trisomy, 5% is 13- trisomy,15% is no abnormal fetal karyotype.Fetal systemic edema showed extensive subcutaneous tissue edema of the fetalbody was hypoechoic band .(Figure 2.)It increases significantly thicker in the neck, it seems that the fetal body is in a thick layer of “spacesuits”, namely the sign for space suit hydrops, including pleural effusion,peritoneal effusion(Figure 3.),pericardial effusion.

Associated with fetal hydrops, More than 68% in Turner syndrome appears. Heart malformarions occur in approximately 15%,common with coarctation of the aorta,aortic valve abnormalities,heart defects.(2)Oligohydramnios or without amniotic fluid;(3)There are often choroid plexus cysts.(4)Kidney malformations,such as hydronephrosis.Renal hypoplasia or dysplasis,horseshoe kidney.(5)Omphalocele (6)10～13 plus 6 d weeks pregnant, Turner syndrome (45, X) nuchal translucency, NT, whose thickness was significantly higher than normal(< 3 mm). Umbilical cord around the neck when the NT thickness measurements may be false increased[4].

Relationship with fetal chromosomal abnormalities: Different chromosomal abnormalities of the fetus,the NT thickness are different. With the NT thickness increases, nearly 50% of fetal chromosomal abnormalities can be detected. The NT thickness of most trisomy 21 fetuses. < 4.5 mm, the majority of trisomy 13 or 18 fetal, NT thickness is 4.5～8.4mm,the Turner syndrome (45,X) fetal NT thickness > 8.5 mm[5-7]. (7)The nuchal fold, NF) thickness of Turner syndrome(45,X) the back of the neck increases,16 to 18 weeks pregnant NF thickness ≥ 5 mm, 18 to 24 weeks pregnant NF

thickness ≥ 6 mm as abnormal[8], NF is now considered as the most sensitive and most specific soft targets of ultrasound screening for fetal chromosomal abnormalities in middle pregnancy[9].There are factors such as gestational age,fetal position and whether there are umbilical cord around neck will affect the thickness measurement of NF.Thickening of the NF should be differentiated from cystic in back and neck tumors.For different gestational age fetus, NF thickness of the index can be applied (Nix). Formula: Nix=[NF thickness (mm)/ biparietal diameter (mm)]×100. Nix measured values are not affected gestational age, when Nix > 11,diagnosis of fetal chromosomal abnormalities, 50% sensitivity and specificity of 96% .In this study ,first fetal karyotype of NF thickening (45,X) (Figure 4.)The Nix=[7.8 mm/ 49 mm]×100= 15.92 > 11.

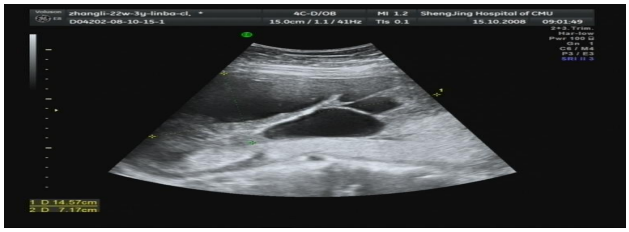

The fetal neck visible to 14.57×7.17 cm cystic mass,border clearance, liquid with more separated in it.

Figure 1 The sonographic of fetal neck cystic mass

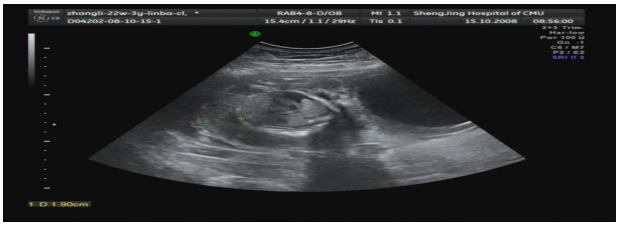

Fetal whole body skin edema thickness of 1.9 cm

Figure 2 The sonographic of fetal edema

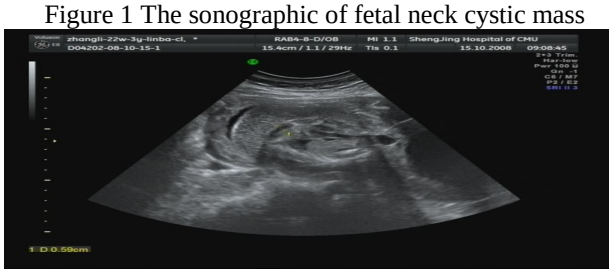

Abdominal visible effusion depth of approximately 0.59 cm

Figure 3 The sonographic of fetal seroperitoneum

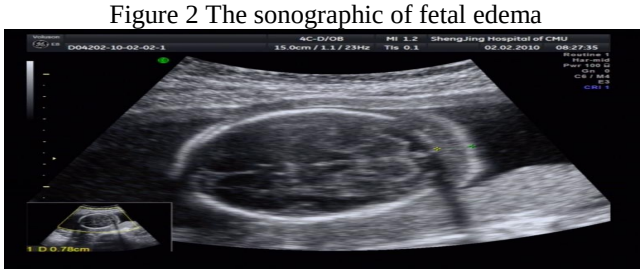

Fetal biparietal diameter 4.9 cm , NF thickness of 0.78 cm

Figure 4 The sonographic of NF thickness

Clinical value of ultrasonography in screening Turner syndrome(45,X) It can be seen from Table 1 to 2 the detection rate of Turner syndrome (45,X)detected by ultrasound was higher than advanced age group，the Down's syndrome high risk group; 8 Turner syndrome45,X-4 cases, 4 Turner syndrome 2 cases ultrasound abnormalities,but in this study ,other karyotype of Turner syndrome ultrasonography found no abnormaliries, indicating that During the second trimester, ultrasonography has great value in screening Turner syndrome (45,X),the value of other karyotype of Turner syndrome detected is not large.

False negatve ultrasound screening over the same period Table 1-2 shows a simple ultrasound abnormalities screening 2 Turner syndrome,accounting for 25% of the detection of Turner syndrome(2/8), accounting for 50% of the detection of Turner syndrome(45,X)(2/4),showing that ultrasonography in screening Turner syndrome(45,X)is an effective method,but there are some ultrasonic no abnormal fetuses with Turner syndrome detected by other puncture indications 6 cases, accounting for 75% of the detection of Turner syndrome(6/8), showing that the negatve results of these ultrasonic no abnormal fetuses is a false negatve,if not combined with maternal age,serum screening puncture indications

karyotype analysis of the positive,will result in 6 Turner syndrome was missed,so the joint screening can reduce the false negatve rate of ultrasoung screening to improve the detection rate Turner syndrome.

In short, During the second trimester, ultrasonography found that the fetal neck cystic lymphangioma cystic tumor,systemic edema,pleural effusion,peritoneal cavity effusion,NT or NF thickening

ultrasound abnormalities can prompt Turner syndrome(45,X)possible to suggest that patients with amniotic fluid puncture check the karyotype to confirm the diagnosis.

Conclusions

During the second trimester, ultrasonography has great value in screening Turner syndrome (45,X).

Acknowledgement

The subject is funded by the research foundation of Eastern Liaoning University, project number 2015JC014.

References

[1]Li Wei jing.The clinical significance of prenatal screening by fetal chromosomal abnormalities,serology and ultrasound morphology.Practical Obstetrics and Gynecology, 2006，22(3):134-136.

[2] Czuba B，Borowski D，Cnota W，et al. Ultrasonographic assessment of fetal nuchal translucency(NT)at 11th and 14th week of gestation-Polish multicentre study. Neuro Endocrinol Lett，2007，28(2):175-181.

[3] Sághy T. Periodontal changes in Down syndrome. A literature review. Fogorv Sz，2008，101(3):113-118.

[4] Prefumo F, Sairam S, BhideA, eta.l First-trimesternuchal translucency, nasalbones, and trisomy21 in selected and unselected populations.AMJObstetGyneco,l 2006, 194(3): 8328-8334.

[5] Harry WG, Reed KL. Nuchal translucency and first-trimester screening. J SocGynecol Investig, 2006, 13(3): 153-154.

[6]Kagan KO, Avgidou K, Molina FS, et a.l Relation between increased fetal nuchal translucency thickness and chromosomal defects. ObstetGyneco,l 2006, 107(1): 2-3.

[7]Meng Hua,Jiang Yuxin.Application of ultrasound in the diagnosis of birth defects. Chinese Journal of
Practical Gynecology and Obstetrics,2005, 21(7): 515-516.

[8] Gianferrari EA, Benn PA, Dries I, et al. Absent or shortened nasal bone length and the detection of Down Syndrome in second-trimester fetuses Obstet Gynecol 2007,109(2pt l):371-375.

[9]Nyberg DA, et al. Isolated sonographic markers for detection of fetal Down syndrome in the second trimester of p regnancy . J UltrasoundMed, 2001, 20: 1053-1063.

[10] Cho JY, Kim KW, Lee YH, et al. Measurement of nuchal skin fold thickness in the second trimester influence of imaging angle and fetal presentation Ultrasound Obstet Gynecol 2005, 25(3):253-257.