

## **ANATOMICAL PATHOLOGY AND RADIOLOGY APPEARANCE OF BALLISTIC WOUND RESULT OF CAL. 177 AIR RIFLE WITH 4,5 MM PELLETS ON THE EXTRIMITY OF THE DOG (*Canis lupus familiaris*) AT DIFFERENT SHOOTING DISTANCES**

\*Bilqisthi Ari Putra<sup>1</sup>, Jola Rahmahani<sup>2</sup>, E.Bimo Aksono<sup>3</sup>, Djoko Legowo<sup>4</sup>, Benjamin Christoffel T.<sup>5</sup>

<sup>1</sup>Undergraduate Student of Faculty of Veterinary Medicine, <sup>2</sup>Veterinary Microbiology Department, <sup>3</sup>Basic Medical Sciences Department, <sup>4</sup>Veterinary Pathology Department, <sup>5</sup>Veterinary Anatomy Department, Veterinary Medicine Faculty, Airlangga University

\*bilqisthi.ari.putra-2016@pasca.unair.ac.id

**Abstract**— This study was undertaken to investigate the impact of several shooting distances of cal.177 (4,5 mm) air rifle toward the anatomical pathology changes of gunshot wounds (ballistic wounds in particular). This observational study used four domestic dogs (Non-SPF) obtained from a local dog breeder. The shooting distance were divided into 2 (two) different ranges at 0 cm as the contact range and 500 cm as the distance shooting range, respectively. Adequate anaesthesia was performed on the dogs prior to shooting. The use of experimental animals was approved by the Ethics Committee (Animal Care and Use Committee) Faculty of Veterinary Medicine, of the University of Airlangga. Ethical procedures were strictly followed in this research. The parameters were the depth of the gunshot wound and specific lesions at the site of the entry and exit wound. *Forensic Photomacrography* and x-rays were performed to observe the specific lesions of the gunshot wound. This study revealed that the average depth of gunshot wounds in the extremities at contact shooting distance is 57.5 mm and 55.5 mm for distant shooting. Each gunshot wound has a specific lesion in the context of both contact and distant shooting.

**Keywords**— *Air rifle, Cal.177 Pellets, Shooting distance, gunshot wound, forensic photomacrography.*

### I. INTRODUCTION

The crime of using an airgun/ air rifle against an animal is one of the most common crimes and becomes a legal case where and when the role of veterinarian is indispensable, both in investigation and inquiry. Airguns are often used to kill or maim domesticated and wild animals [1]. The occurrence of gunshot wounds caused by airguns is quite common in pets, including dogs and cats in both urban [2] and rural areas around the world.

The type of air rifle that is commonly found in the community is the type with a pneumatic multiple pump with 4,5mm pellet bullet (Diabolo pellet, hourglass-shaped, soft lead missile) because it is cheaper than the BB type [4].

The estimation of the shooting range can be determined by photography and x-rays to identify the presence of projectiles, and for the identification of shot and exit injuries [5][4]. The shooting range is divided into 4 categories namely, Touch (contact), Near (close), Medium (intermediate), and Far

(distant). Respectively, estimation data based on the appearance of the ballistic wound in animals rarely exists. In this research study, we tried to reveal the first information about gunshot wounds at contact and far/distant ranges in this context.

In the disclosure of animal crime cases with firearms, as well as with air rifles, a veterinarian who acts as a veterinary forensic expert needs to understand the science of Forensic Ballistics and Pathology as well. Forensic ballistics includes the type of weapon or rifle that is used, the state of the gun, the type of bullet, the distance and the direction of firing, as well as the wound figure (ballistic wound). Research on forensic ballistics in animals is still rarely done [3].

### MATERIAL AND METHODS

#### *Sample*

Two mongrel dogs were utilised for the study, after being given zolazepam-tiletamine (zoletil®) anaesthesia. The use of experimental animals was approved by the Ethics Committee (Animal Care and Use Committee) Faculty of Veterinary Medicine, of the University of Airlangga.

#### *Shooting Techniques*

An air rifle (Multi-pump), round shaped cal.177 pellets, gun scopes and lasers, a rifle tripod, and a wooden board with hole box were used to increase focus when shooting. The animals were placed on the stand position supported with a modified holder.

The shooting was done by 10 pumps on the gun with a perpendicular shooting angle to the dog's surface. The shooting distance was measured between the muzzle and the surface of the target [5].

The shot was directed at the exact point of the dog's humerus and femoral region [6]. The target shots were marked using a sterile and biological marker.

#### *Forensic Photography*

Photographs are taken in close-up (photomacrography) of the labelled gunshot wounds. The photo was taken after the measurement of the gunshot wound with an ABFO ruler [7] to give an interpretation of the size of the wound and the bullet

using a Digital Single-lens Reflex (DSLR) Camera and 50mm fixed lens [3].

**X-Ray**

X-Ray capture was done on the cranial extremities (os.humerus) and caudal (os.Femur) extremities. In the cranial extremities, the Central Ray (CR) was directed at the middle of the scapulo-humeri region with a lateral recumbency. In the caudal extremity, the Central Ray (CR) was directed to the sacro-femoral region (the link between the anterior femoral cap and the acetabulum) due to the position of the ventro-dorsal body (dorsal recumbency). [8]

**Post Operation**

Treatment using broad-spectrum antibiotics was essential as a prophylaxis against infectious agents that cause osteomyelitis and complications during recovery after surgery. The administration of ADONA (AC-17) ® (carbazochrome sodium sulfonate) was performed to stop the bleeding from the gunshot wounds. Bandaging was done using Modified Roberts Jones wrapping for 3 days to minimise swelling. Also administered was an intramuscular injection of Ampicillin 10-20 mg / kg with an interval of 8 hours for 5 days, a subcutaneous injection of caprofen® 4 mg / kg after surgery and an intramuscular injection Ketoprofen® 1 mg / kg for 3 days. The stitches were removed on day 14. Radiographic evaluation was performed 1 month after surgery with callus formation evident.

**Data Analysis**

All of the data obtained from this observational study was analysed descriptively.

**RESULT AND DISCUSSION**

The firing using maximum pump at a contact and distant shooting distance showed different results (Table 1). Both shooting distances can penetrate the extremity at contact, and are able to form an exit wound (Fig.1).

Tabel.1 : Mean of depth of gunshot assisted x-ray virtual trajectory wound.

Distance (cm)	Mean (mm)
0 (Contact)	57,5
500 (Distant)	55,5

The results of anatomical pathology observations on gunshot wounds using forensic photography methods shows different appearance at each shooting range. The entry wound and exit wound were differentiated based on the edge of the wound, the wound diameter, scuffed skin and subcutaneous bleeding (contusion ring).

The observation results show that at 0 cm distance (contact), there is an entry wound and exit wound. In the incoming wound (entry wound), there is a compression area that occurs around the wound (Figure.2). Compression can also be known through the hair pattern around the wound. The penetration of projectiles in to the muscle causes active

bleeding. Extravasation and minor blood spatter can also be observed in the gunshot wounds. (Figure 2)

The contusions on the entry and exit wound appear different. The contusions on the outbound wound are larger and firmer than the incoming wound. Further observation showed that the entry wound and exit wound appear to have acute subcutaneous bleeding. Contusions in the entry wound have an average diameter of 5.49 mm. The average wound diameter is 4.60 mm. The the exit wound also appears to have a contusion with an average diameter of 9.71 mm. The average diameter of the exit wound is 4.65 mm. The mean diameter of the contusions on the outflow was 9.71 mm and the average diameter of the wound was 4.65 mm. (Table.2)

Blisters can be seen on the inside edge of the wound. Abrasions at the edge of the gunshot wound appear in the entry wound. The grease collar on the edges of the wound appear to be blackish. (Figure.3)

A follow-up observation at 500cm indicates that the entry wound and exit wound appears to have acute subcutaneous bleeding around the wound (Figure 4.10). Contusions in the entry wound have an average diameter of 8.50 mm. The average diameter of the entry wound is 4.44 mm. The exit wound also appears to have contusions with an average diameter of 9.71 mm. The average diameter of the exit wound is 5.50 mm (Table.2). The description of the contusions of the entry wounds and exit wounds appear different. The contusions of the entry wound are firmer and smaller than that of the exit wound. Blisters can be seen on the inside edge of the wound. Abrasions at the edge of the gunshot wound appear in the entry wound. The grease collar on the wound edges are not visible.

Table.2:

Distance	Type of Wound	Diameter (mm)	
		contusion	wound
0 cm ( <i>contact</i> )	entry	5,49	4,60
	exit	9,71	4,65
500 cm ( <i>distant</i> )	entry	8,50	4,44
	exit	8,68	5,50

Figure.1: Estimation of trajectory wound from x-ray.

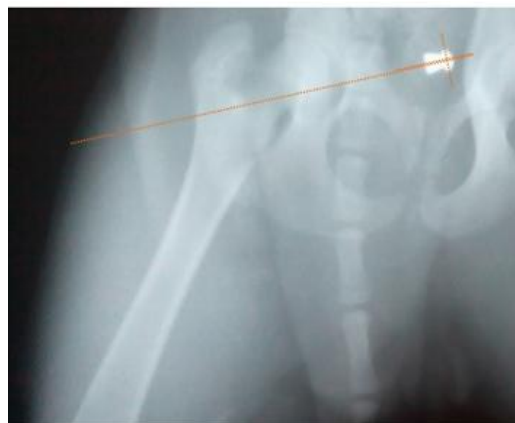

Figure.2: Comparison of the contusion ring between the entry and exit wound at contact (0 cm) shooting.

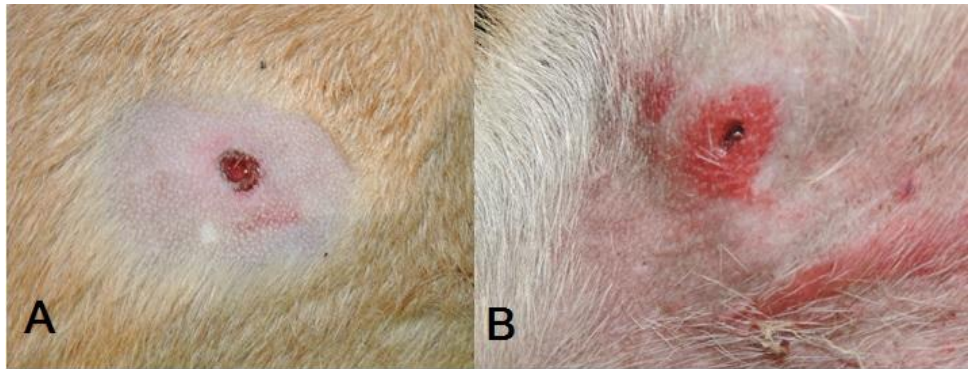
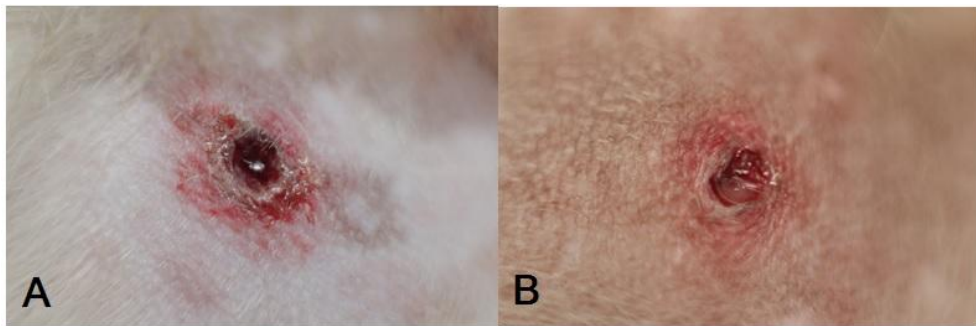


Figure.3: (A) The blisters at the edge of the entry of the contact shooting wound (0 cm). (B) Grease collar/ring

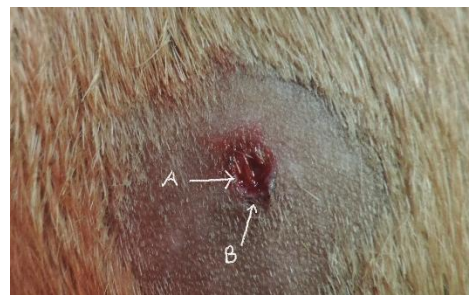

Figure.4: Comparison of the entry and exit wound at distance shooting (500 cm).



The pellet used was of the round shape type and had an average weight of 0.54 g. The 10x pumping result based on the specification of the air rifle used in this research showed that the muzzle velocity (projectile speed as it leaves the barrel) is 715 fps or 218m / s if it is equalised up to 784.8 km / h. The energy generated by the rifle used in this study belongs to the low energy bracket i.e <400J [9].

The kinetic energy at the time of the projectile leaving the barrel can be known through the following formulation:

$$E_0 = 1 / 2.M.V_0^2$$

$E_0$  = Kinetic energy (J)

$M$  = Mass (g)

$V_0$  = The speed of the projectile when leaving the barrel (m / s) [10]

The kinetic energy of the projectile upon leaving the barrel is 12.83 J or equivalent to 9.42 fpe. It also means that  $E_0$  is the kinetic energy of the projectile at a distance of 0 cm (contact wound). Kinetic energy at the 500 cm range can be known after the projectile velocity is calculated when touching skin ( $V_1$ ):

$$V_1 = V_0 - (Br) \times L$$

$V_1$  = The speed of the projectile at a distance of 500 cm (m / s)

$V_0$  = Projectile velocity when leaving the barrel (m / s)

$Br$  = Constants derived free flight table

$L$  = Distance Shoot

[10]

The speed of the projectile at the time before touching the skin or at a distance of 500 cm is 208 m / s or 682.4 fps if equalised at 748.8 km / h. The kinetic energy before the projectile touches the skin or at 500 cm range can be calculated through the following formulation:

$$E_1 = 1 / 2.M.V_1^2$$

E0 = Kinetic energy (J)

M = Mass (g)

V<sub>0</sub> = The speed of the projectile when leaving the barrel (m / s)

[10]

The kinetic energy before the projectile touches the skin or at a distance of 500 cm is 11.66 J.

The penetrating wound at contact and distant shooting indicates that the kinetic energy loaded by the mass and speed of the projectile is still relatively capable of penetrating all extremities except bone. The speed of the projectile required to penetrate the bone is 250 cm / s or equivalent to 900 km / j. [10].

The difference in the average of depth of the wound at the range of 0 cm (contact) and 500 cm (distant) is due to the loss of kinetic energy of the projectile at the time it is in flight. The kinetic energy lost during the flight at 500 cm distant range can be detected through the following formulation:

$$\Delta E = E_0 - E_1$$

ΔE = Missing kinetic energy

E<sub>1</sub> = Initial energy (muzzle energy)

E<sub>0</sub> = Energy at a distance of 500 cm (distant)

The energy lost during the air at a 5 cm range is 1.17 J.

#### CONCLUSION

The following conclusions can be drawn from this study; the average depth of the ballistic wound on the dog's extremity due to a air rifle using a cal.177 pellet projectile at a range of 0 cm (*contact*) is deeper than at 500 cm (distant). Based on the description of the anatomical pathology of the ballistic wound, there is a distinctly different appearance of the entry wound and exit wound at the different shooting distances.

#### ACKNOWLEDGEMENT

The author would like to thank Dr. Jola Rahmahani, Dr.E.Bimo Aksono, Djoko Legowo, DVM and Dr. Benjamin Christoffel T as my supervisors for this research. I would also

like to thank AKP Sudriyo from the Forensic Laboratory of the National Police Department in Surabaya.

#### REFERENCES

- 1) Coulson, Arlene and Noreen Lewis. *An Atlas of Interpretative Radiographic Anatomy of the Dog & Cat*. Blackwell Science. Ltd. United Kingdom.:p
- 2) Conner J.F., Cooper M.F. *Introduction to Veterinary and Comparative Forensic Medicine*. Blackwell Publishing. Swanston Street, Carlton, Victoria 3053, Australia.77-333.
- 3) Di Maio. V.I.M. *Gunshot Wounds: Practical Aspects of Firearms, Ballistics, and Forensic Techniques*. Boca Raton, FL: CRC Press.51-331
- 4) Idries. Abdul Munim dan Agung Legowo Tiintomartono. *Penerapan Ilmu Kedokteran Forensik dalam Proses Penyidikan*. Jakarta : CV Sagung Seto.
- 5) Lu Huchen. MD. Lian Wang. MD. PhD. Wuzhao Zhong. MD., Rongfeng Qi. MD. PhD. Ning Li. MD. Wanchun You. MD. PhD. Xingfeng Su. MD. PhD. Zong Zhuang. MD. PhD. Huilin Cheng. MD. PhD. Jixin Shi. MD. PhD. Establishment of swine-penetrating craniocerebral gunshot wound model. *Journal of Surgical Research*, December 2015 Volume 199, Issue 2, Pages 698–706
- 6) Massimiliano, Ferrucci, Theodore D. Doiron, Robert M. Thompson, John P. Jones II, Susan M. Ballou, Janice A. Neiman. *Dimensional Review of Scales for Forensic Photography*. National Institute of Standards and Technology (NIST). University of Delaware.
- 7) Merck, Melinda.D. *Veterinary Forensics: Animal Cruelty Investigation*. Black Publishing Ltd. USA.
- 8) Panagiotis K. Stefanopoulos, Georgios F. Hadjigeorgiou, Konstantinos Filippakis, Dimitrios Gyftokostas. Gunshot wounds: A review of ballistics related to penetrating trauma. *Journal of Acute Disease* (2014)178-185
- 9) Park,S. J.Park, J.M. Kim, J.H. Kim, J. Son, D. Chang, S.H. Choi, G. Kim. Penetrating cranial injury due to gunshot in a dog: a case report. *Veterinari Medicina*, 55, 2010 (5):253–257
- 10) Rybeck. B. and Janzon. B. Abstrak. Absorption of missile energy in soft tissue. *Acta Chir, Scand*. 142:p201–207.