ATLANTIS PRESS

Advances in Health Science Research, volume 8

International Dental Conference of Sumatera Utara 2017 (IDCSU 2017)

Case Report: Mandibular Third Molar Impaction Features in CBCT 3D Radiography

Gunawan
Faculty of Dentistry, Universitas Andalas
Padang, Indonesia
gunawan_drg107@yahoo.com

Lusi Epsilawati
Faculty of Dentistry, Universitas Padjadjaran
Bandung, Indonesia

Ivony Fitria
Faculty of Dentistry, Universitas Andalas
Padang, Indonesia

***Abstract*–The mandibular third molar impaction is a frequent case in dentistry. Various investigations are required prior to the removal of the mandibular third molar impaction, such as CBCT 3D radiography. This radiograph can provide optimum results for the investigation of mandibular third molar impaction. Case I: a 20-year-old woman came to Radiology Installation, RSGM FKG UNPAD with a referral letter for CBCT 3D photos. Anamnesis showed that patient had complaints of repeated pain in the area of left posterior teeth. Patient was pre-medicated and referred for radiographic images. Case II: a 33-year-old woman came to Radiology Installation, RSGM FKG UNPAD with a referral letter for CBCT 3D photograph. Anamnesis revealed patient with complaints of pain in the left posterior teeth. Patient was pre-medicated and referred for radiographic images. The radiodiagnosis of both cases above is Class II position B mesioangular. In cases of mandibular third molar impaction, investigation with CBCT 3D can provide optimal information. CBCT 3D can provide information about the shape, position and relationship of the impacted third molars to its surrounding anatomy in sagittal, coronal and axial view. This accurate information will make it easier for clinicians to perform adequate maintenance. CBCT 3D can provide an optimal features in the management of mandibular third molar impaction.**

Keywords–CBCT 3D, impaction, sagittal, coronal, axial

I. INTRODUCTION

Dental impaction is a common case in dentistry. According to Archer, quoted from Rahayu, as many as nine out of ten people have an impacted tooth. Impacted teeth often occur in permanent molar, canine, premolar, and incisors. One of the highest prevalence of impaction cases is the impacted mandibular third molars[1]. An impaction is a condition when tooth failed to erupt into the dental arch within the expected time. The word '*impaction'* is derived from Latin word '*Impactus*', meaning 'cessation of eruption caused by physical barrier/ectopic eruption.' The tooth is categorized as impacted by the presence of another tooth, bone or soft tissue. Impacted teeth are the teeth that are blocked during an eruption to achieve a normal position [2,3,4].

Accurate examination prior to the removal of the impacted mandibular third molar is necessary. An accurate preoperative assessment of the radiograph is crucial for the success of impacted third molars surgery, but unfortunately, this is often overlooked. Some things to consider before the removal of the impacted third molars are: 1) form (both crown and root), size, shape, caries status, shape, amount, periapical bone loss. 2) Angulation of impacted molar to the occlusal plane. 3) Relationship of the second molar, both the crown (size, shape, caries status) and roots (size, shape, amount). 4) The relationship of inferior dental canals to the impaired molar should be determined appropriately using radiographs. 5) Distal bone level [5,6].

The use of radiography aims to reduce post-operative complications. These can be pain, swelling, excessive bleeding, infection and reduced mouth opening, however, sensory disturbances to the nerves, e. g. the alveolar inferior nerve (IAN), the buccal nerve and the lingual nerve, are seen as the most severe postoperative complications after removal of a mandibular third molar. In a radiographic image of the third molar region, only the course of the IAN may be assured since the mandibular canal, within which the nerve is situated, is usually visible. The course of the other two essential nerves in the region are not seen in radiographs [6].

Despite the presence of certain radiographic signs on panoramic radiograms (darkening, narrowing or deflection of the root, dark and bifid apex of the root, interruption of cortical outline of mandibular canal, canal diversion or narrowing, island-shaped apex), mostly associated to a mural and the mandibular canal, only a cross-sectional CT image (CBCT) can define the several types of relationships in a buccal/lingual direction [7].

Cone-beam computed tomographic (CBCT) imaging is the most significant technologic advance in maxillofacial imaging since the introduction of panoramic radiography. CBCT imaging was initially developed commercially for angiography in the early 1980s. It uses a divergent cone-shaped or pyramid shaped source of ionizing radiation and a two-

dimensional fixed area detector on a rotating gantry to provide multiple sequential transmission images that are integrated directly, forming volumetric information [8,9].

Over the last years, CBCT is becoming more common in clinical practice because of its spatial resolution and lower radiation dose as compared to conventional CT. Its applications in implantology, endodontic, orthodontics and oral and maxillofacial surgery have been reported [7].

II. CASE REPORT

Case I: A 20-year-old female patient came to Radiology Installation of RSGM FKG UNPAD with a referral letter for CBCT 3D photograph. During anamnesis, patient complained of pain in the lower left posterior teeth. Patients were pre-medicated and referred for radiographic images. Clinical examination shows the presence of redness at the distal second molar. The 3D CBCT radiograph examination showed impaction on tooth 38 with classification of Class II position B mesioangular. The third molar had 2 roots, mesial and distal, located on the mandibular canal.

Case II: a 26-year-old female patient came to the Radiology Installation of RSGM FKG UNPAD with a referral letter for a CBCT 3D photograph. The patient's anamnesis revealed pain in the lower left posterior teeth. Patients were pre-medicated and referred for radiographic images. On clinical examination, there is no visible third molar. The results of 3D CBCT examination showed dental impaction of tooth 38 classified as Class II position B mesioangular. The tooth 38 has 3 roots, two in mesial and one distal, and the root is on the mandibular canal.

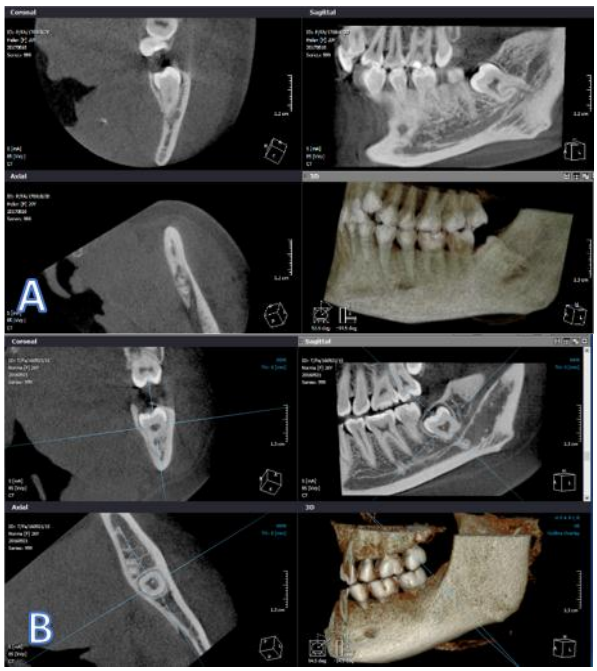

Figure 1. MPR view case I (A) and case II (B).

Figure 2. Coronal view case I (A) and case II (B).

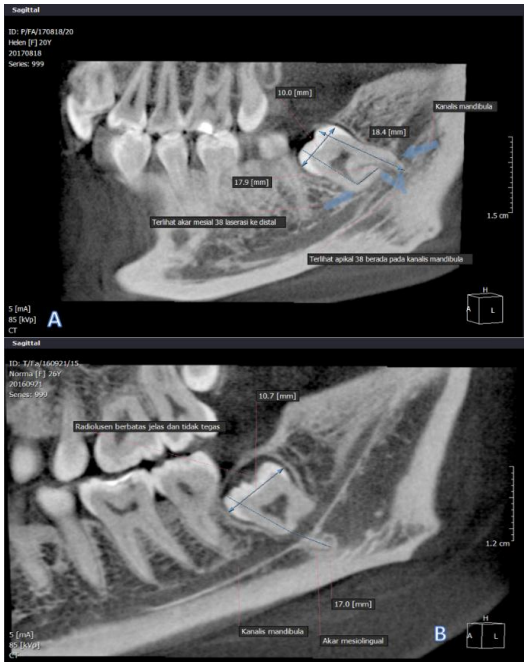

Figure 3. Sagital view case I (A) and case II (B).

Figure 4. Axial view case I (B) and case II (B).

Figure 5. 3D and segmentation view case I (A) and case II (B).

III. DISCUSSION

Adequate investigation is necessary to obtain an optimal treatment and action plan for the patient. In the case of impaction, examining with CBCT 3D can provide the information necessary to assist the clinician while going to do the extraction on the tooth. CBCT 3D can provide a sagittal, coronal and axial features (Figure 1). So the features of dental impaction condition can be known more accurately. The coronal view can reveal the distance of the crown to the bone of cortical bone in lingual and buccal view, and its relationship of root with mandibular canal (Figure 2). To assess the visibility of the mandibular canal in buccolingual direction, cross-sectional CBCT images can be used. Cross-sectional images can be generated using different slice thicknesses, interslice interval and angulations. This, in turn, might affect the visibility of the MC as shown in a few studies [10].

The sagittal view will provide features about the position of impacted third molars, the length of the crown to the apical at the mesial and distal roots, and the abnormalities in the root form (Figure 3). The axial view will provide information about mesial - distal and buccal - lingual width, and the proximity of its root tip to the mandible canal (Figure 4). Since CBCT images can display the examined volume in all anatomical planes, when an over projection of the mandibular canal occurs in the traditional 2D images, it is expected that the CBCT can reveal the exact relationship between the third molar and the mandibular canal in cross-sectional image sections. However, due to the high resolution and low radiation dose in the case of CBCT, the use of CBCT is recommended [6].

Cone Beam Computed Tomography (CBCT) can be used as a technique of choice where three dimensional view of mandibular third molar and its adjacent anatomical structures are required. Hence, CBCT contributes to optimal risk assessment and adequate surgical planning, compared to panoramic radiography [3].

The course of the mandibular canal is traced through the mandibular ramus and body, starting from the lingula on the lingual aspect of the ramus to the mental foramen on the buccal aspect of the mandibular body. In cross-sectional and coronal slices, the mandibular canal is typically seen as an oval or round radiolucency with corticated borders. Sometimes, the cortication may be thin or imperceptible. The relationship of the canal to the tooth roots should be assessed. This relationship varies greatly among patients, especially in the molar region, with the mandibular canal occupying a position from close to the root apices to adjacent to the inferior border of the mandible. Other variations include bifid mandibular canals, with a reported frequency of about 15%. The mandibular canal exits to the buccal surface of the mandible, via the mental foramen, usually at the premolar region. There is significant variation in the size, shape, and location of the mental foramen [4].

It is concluded that CBCT 3D can provide adequate features in cases of mandibular third molar impaction as the images can be obtained coronally, sagittally and axially, so that the anatomy, position, and dental relationships of the impacted teeth with the surrounding area can be analyzed.

REFERENCES

[1] S. Rahayu, “Odontektomi, tatalaksana gigi bungsu impaksi,” E-Journal WIDYA Kesehatan dan Lingkungan, vol. 1, pp. 81-89, 2014.

[2] T.D. Sahetapy, S.P. Anindita, B. Hutagalung, "Prevalensi gigi impaksi molar tiga partial erupted pada masyarakat desa totabuan," Jurnal e-GiGi, vol. 3, pp. 641-646, 2015.
[3] S. Singh, H. Rahman, R. Chandra, S. Tripathi, J. Jain, K.G. Tarun, et al., "Assessment of inverted mandibular third molar impaction by 3d reconstruction - a rare case series," Journal of Dental and Medical Sciences, vol. 15, pp. 4-7, 2016.
[4] J.L. Peterson, Oral and maxillofacial surgery chapter 9, 4th ed., Mosby, 2012.
[5] A.D. McGowan. An atlas of minor oral surgery principle and practice. 2nd ed. United Kingdom: Martin Dunitz, 1999.
[6] L.H. Matzen, A. Wenzel, "Efficacy of CBCT for assessment of impacted mandibular third molars: a review – based on a hierarchical model of evidence," Dentomaxillofacial Radiology, vol. 44, 2015.
[7] M. Michele, C. Fulvia, B. Gabriele, "Classification of impacted mandibular third molars on cone-beam CT images," J. Clin. Exp. Dent., vol. 7, pp. 224-31, 2015.
[8] S.C. White, M.J. Pharoah. Oral Radiology Principles and Interpretations. 7th ed., Canada: Mosby, 2014.
[9] E. Whaites. Essential dental radiography and radiology. 4th ed. Spain: Elsevier, 2007.
[10] M. Alkhader, J. Fadi, "Visibility of the mandibular canal on crosssectional CBCT images at impacted mandibular third molar sites," Biotechnology & Biotechnological Equipment, vol. 30, pp. 578-584, 2016.