ATLANTIS PRESS

Advances in Health Science Research, volume 8

International Dental Conference of Sumatera Utara 2017 (IDCSU 2017)

The Relationship between Morphology of Sella Turcica and Class II Skeletal Malocclusion in RSGMP FKG USU

Indah Fitriasary
Orthodontics
Faculty of Dentistry, Universitas Sumatera Utara
Medan, Indonesia

Muslim Yusuf
Nazruddin
Departemen of Orthodontics
Faculty of Dentistry, Universitas Sumatera Utara
Medan, Indonesia

Nazruddin
Department of Orthodontics
Faculty of Dentistry, Universitas Sumatera Utara
Medan, Indonesia

***Abstract*–In lateral cephalometric analysis sometimes found a borderline results, its difficult to ascertain the jaw skeletal relationship, in this situation, taking into account the morphological variation and the sidelines of the tursika on cephalometric radiography are expected to help to determine whether skeletal relationships Class I, II or III malocclusion. The sample in this study are 104 photos of lateral sefalometri divided into two groups Class I and Class II malocclusion based on the ANB value, each group was randomized and identified by morphology sella turcica following the theory of Axellson et al (2004), then compared with the value ANB from each group. The results of this study indicate that there is a significant differences between morphology variation of sella tursika in Class I and class II malocclusion, obtained normal morphology sella turcica at most in sample group of Class I (35 sample (83,3%)) and Class II (7 sample (16.7%)), ANB angle indicates the discrepancy of sagittal growth from the apical base of the jaw. Irregular (notching) posterior wall greater found in Class II malocclusion (26,9%) and in Class I malocclusion only 7,7%. There was significant differences in morphology of sella turcica in the group of patients with skeletal Class II malocclusions compared to patients with skeletal Class I malocclusions and there is a correlation of morphological variation of the sell of patients with skeletal Class II malocclusion.**

Keywords–malocclusion, morphology sella turcica, ANB, class I, class II

I. INTRODUCTION

Lateral cephalometric radiography plays an important role in orthodontic treatment when determining diagnosis, type of malocclusion, treatment plan, facial growth and development, assessment of changes before and after treatment. In diagnosis of facial skeletal type and assessment of orthodontic treatments, several points in the craniofacial region of patients are used as reference points in tracing lateral cephalometry radiographs. Sella turcica is of special significance due to its role as the central reference point in the assessment of cranial morphology and intermaxillary relations [1-10].

The pituitary gland is located in the sella turcica. Thus, various pathologies of this gland can change the shape and size of sella turcica [1,6,7]. During the development of embryology, sella turcica is an important key in neural crest cell migration to the frontal, palatal and maxillary development so that if an morphological anomaly of sella tursika will be followed by functional disorders of the pituitary gland such as regulatory disorders glandular secretion of hormones, prolactin, growth hormone and follicular stimulating hormone. Malformations of the pursary or pituitary gland may be associated with growth malformations in the craniofacial region (frontonasal, maxilla, palatal and mandible) occasionally involving the brainstem, thymus, thyroid and heart [5,8].

The differences morphology and the size of sella tursika were significantly found in people with different ethnicities in previous studies [9], therefore further research is required to obtain more data and information on this. Data on standard morphology of sella turcica for all communities is needed so that knowledge can be obtained that can assist in detecting anatomical abnormalities in sella turcica [1,5,9-12].

Since dentists and orthodontists frequently order and evaluate cephalometric radiographies, by learning and knowing the normal variations of the sella turcica, they will be able to recognize abnormalities of this area if there is change in these normal variations, even before the appearance of clinical manifestations. At present, determining the morphology of the human craniofacial region is the focus of attention for researchers in various fields of study. A recent theory, still under investigation, is the correlation of shape and size of sella turcica with class I, class II, or class III facial skeletal types [1,2].

Type of maloclusion is classified into three types (class I, II, and III) based on the anteroposterior relationship of the maxilla and the mandible (upper and lower jaws). Resolution of this issue can help the diagnosis and treatment of patients who are candidates for orthodontic treatment. Necessary orthodontic treatments for facial skeletal class I, II, and III types are completely different. Before beginning treatments that are usually expensive and complicated it is important to determine the definite type of skeletal relationship between the jaws. Sometimes, measurements resulting from lateral cephalometric analysis may provide borderline findings and it is not possible to differentiate between different skeletal types, especially class I and class III. So, making definitive decision for the treatment plan is difficult. In this situation, attention to the variation in the shape of the sella turcica on the existing cephalometric radiograph that was analyzed before cephalometric measurements helps to determine if the skeletal relationship is progressing to class III or class I [1,13]

Research on the morphology of sella turcica associated with malocclusions especially Class III, dental anomalies, craniofacial deviation, cleft and various syndromes has been widely reported, but there are still few reports of Class II malocclusion, so this study is taken [4].

The results of the study by Sujaani et al 2014, the morphology of sella tursika in Class I malocclusion is reported 71% normal sella tucica and in Class II malocclusion 50%. Bridging sella, irregular (notching) posterior wall and pyramid are more common in Class II than in Class I. Abdel Kader et al 2007 reported that bridging sella is more common in Class III malocclusions than Class I and II malocclusions, this is in line with the study by Marcotty et al and Sathyanarayana et al. While research by Bush, Muller and Platzer reported irregular (notching) posterior wall more common in Class II malocclusion [1]. From the above reviews the authors wanted to know the relationship of morphological variation of sella tursika with Class II malocclusion in patients in Indonesia, especially in RSGMP FKG USU Medan.

II. MATERIALS AND METHODS

This research is an observational research with cross sectional method at Orthodontic Clinic of Dental Hospital and Mouth Education of FKG USU conducted in October 2016. The research population was taken from patients at RSGMP FKG USU clinic with age range 17-35 years, taken in the form of a lateral cephalometric photograph of the patient with skeletal malocclusion Class I and II. Based on the large sample calculation with 1: 1 proportion, the minimum sample for each treatment group is 52 people so that the total sample is 104 people. The samples selected in this study were determined by inclusion and exclusion criteria, radiographs were taken by an expert, trained technician in a standard position with a specific device and a cephalostat with a fixed magnification factor. Only the radiographs showing a crystal clear image of the sella turcica were selected for interpretation and analysis.

Radiographs were divided into different classes based on ANB angle value (SNA and SNB) (class I: ANB angle equal to ± 2°, class II: ANB angle > 4°. Facial skeletal pattern is classified into three types, based on the anteroposterior relationship of the maxilla and the mandible (class I, II, and III). These three types are explained by ANB angle based on steiner analysis. “A”, “N” and “B” points are detectable on lateral cephalometric radiographies and present A: the deepest point of the anterior border of the maxillary alveolar ridge concavity. N: nasion (frontonasal suture), and B: the deepest point of the concavity of the anterior border of the mandible (Figure 1).

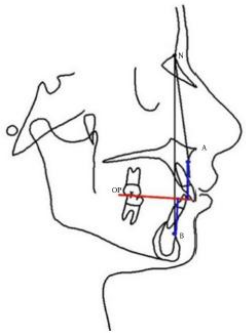

Figure 1. Anteroposterior relationship of the maxilla and the mandible based on steiner analysis.

The sella turcica region was traced on each lateral cephalometric radiography on thin acetate paper under ideal lighting. Then, different parts of the sella turcica including tuberculum sella, floor of sella turcica, dorsum sella and anterior and posterior clinoid processes were all traced (Figure 2).

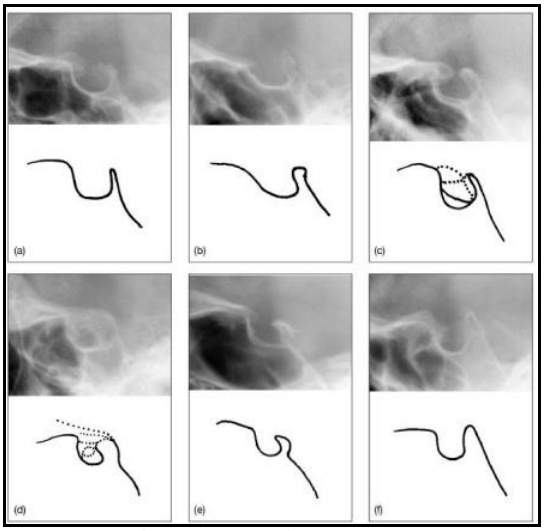

Figure 2. Types of morphology of sella turcica: (a) normal sella turcica, (b) oblique anterior wall, (c) double contour of the floor, (d) sella turvica bridge, (e) irregularity in the posterior part of the sella turcica, (f) pyramidal shape of the dorsum sellae [14].

Methods Analysis of the study using SPSS program, the data will be analyzed descriptively to see the frequency distribution based on the characteristics of the research sample. The numerical data will be presented in terms of average and standard deviation. To assess the relationship between the morphology of sella tursika and the type of skeletal Class II malocclusion, a Somers test was conducted and to assess the morphological differences between the subjects and the control group used Chi Square test.

III. RESULTS

From the results of this study indicated that the normal morphology of sella turcica is most often found in the sample group of Class I skeletal that is as many as 35 samples (67.3%). The second morphological variation of the second highest sella turcica was bridging for 7 samples (13.5%) (Table 1).

TABLE I. DISTRIBUTION OF SELLA TURCICA MORPHOLOGY IN SKELETAL CLASS II MALOCCLUSIONS

Morfology	Klas I Skeletal (n=52)	
1. Normal	35	67.3 %
2. *Oblique anterior wall*	2	3.8 %
3. *Double contour of the floor*	1	1.9 %
4. *Bridging*	7	13.5 %
5. *Irregularity in the posterior part*	4	7.7 %
6. Piramida dorsum sella	3	5.8 %

The results of this study it is shown that the morphology of sella turcica in skeletal class II malocclusion group is mostly found in irregularity of posterior part of 14 samples (26.9%) compared to normal morphology of sella tucica that is only 7 sample (13.5%). Furthermore, the second highest morphological variation of sella tursika on skeletal Class II malocclusion was bridging by 13 samples (25%) (Table II).

TABLE II. DISTRIBUTION OF SELLA TURSIKA MORPHOLOGY IN SKELETAL CLASS II MALOCCLUSIONS

Morfology	Klas II Skeletal (n=52)	
1. Normal	7	13.5 %
2. *Oblique anterior wall*	4	7.7 %
3. *Double contour of the floor*	11	21.2 %
4. *Bridging*	13	25.0 %
5. *Irregularity in the posterior part*	14	26.9 %
6. Piramida dorsum sella	3	5.8 %

The results of this study indicate a significant difference between morphological variations of sella turcica in the Class I malocclusion group compared with the Skeletal Class II malocclusion group (Table III).

TABLE III. DIFFERENCES IN MORPHOLOGICAL VARIATION OF SELLA TURSICA IN CLASS I SKELETAL AND CLASS II MALOCCLUSION

Malocc-lusion	Normal	*Oblique*	*Double contour*	*Bridging*	*Irregularity*	Pyramid	P
Klas I	35 (83.3 %)	2 (33.3 %)	1 (8.3.%)	7 (35.0 %)	4 (22,2 %)	3 (50.0%)	0.0001
Klas II	7 (16.7 %)	4 (66.7%)	11 (91.7 %)	13 (65.0 %)	14 (77.8 %)	4 (50.0 %)	0.0001

**Chi Square test*, p<0,05

The results of this study indicate that there is a correlation between Skeletal Class II malocclusion with morphological variation of sella turcica. Table IV shows the results of Somers test there is a positive correlation between Skeletal Class II malocclusion with morphology variation of sella turcica, with correlation coefficient value (r) = 0.549 which means that the bigger the ANB value, the more morphology of sella turcica.

TABLE IV. CORRELATION BETWEEN VARIABLES BY SOMERS TEST

Correlation between Variable	N	R	P
Class II malocclusion with sella turcica morphology variation	104	0.549	0.0001

*Chi Square test, p>0.05

IV. DISCUSSION

The morphological assessment of sella turcica is a measuring tool in assessing the pituitary gland because the development of sella turcica is directly related to the development of pituitary gland, this is because the pituitary gland is in sella turcicaa and its development has been perfect before the development of sella turcica is completed so that pathological conditions that occur in the gland can cause morphological changes and the size of sella turcica. Morphological variations of sella turcica are reported in cases with severe craniofacial deviation, genetic disorders, abnormalities of the syndrome and dental anomalies such as ectopics and impaction [7,15,19,22-25].

The latest theory that is constantly being studied is the morphological relationship and the size of sella turcica with the type of malocclusion [1,2]. Jones et al reported research as well reported Meyer-Marcotty et al that morphological variations of sella turcica in patients with Class II and III skeletal malocclusions were higher than those of skeletal Class I malocclusion [7].

The results of research by Sujaani et al 2014, the morphology of sella turcica in Class I malocclusion is reported to be about 71% having normal sella turcica. Bridging sella, irregular (notching) posterior wall and pyramid are more common in Class II than in Class I. Abdel Kader et al in 2007 reported that bridging sella is more common in Class III malocclusions than in Class I and II malocclusions, this is in line with the study by Marcotty et al. and Sathyanarayana et al., while Bush, Muller and Platzer studies reported that the posterior wall irregular (notching) is more common in Class II malocclusions [1].

The results of Solmaz et al's study on Iranian subjects, normal morphology of sella turcica were 24.4% and 75.6% had morphological variation. whereas Alkofide in his study evaluating morphology and size of sella turcica in patients with skeletal classification Class I, Class II and Class III reported normal morphology of 67% of cases, the remaining 33% had variations of morphology of sella turcica. Research by Mahmood Shah, a normal morphology of 66% of the subject number [6].

In this study the most normal sella turcica morphology was found in the first sample group of skeletal class as many as 35 samples (79.5%) while in the sample group of 7 skeletal Class II (16.7%), this was consistent with the study by Alkofide et al., Mahmood Shah et al., And Sujaani et al., Solmaz et al [1,6,7].

The union of the anterior and posterior clinoideus bone is also called bridging sella turcica (STB). The prevalence of STB in the general population is reported to be 1.75 to 6% in anatomical and radiographic studies, whereas according to Cedeberg et al. and Axelsson et al. STB incidence was 3.8-13% [8]. In this study the prevalence of STB in Class I was 7 samples (13.5%) while in Class II 13 samples (25%). The occurrence of irregular (notching) posterior wall sella turcica may also occur in normal individuals although the prevalence of irregular (notching) posterior wall is more common in patients with dental anomalies and craniofacial deviation. Bush, Muller and Platzer reported that the irregular (notching) posterior wall is more common in Class II malocclusion.1 This is consistent with the results of this study, the prevalence of posterior wall irregular (notching) on Class II for 14 samples (26.9%) while Class I of 4 samples (7.7%).

In accordance with the results of this study indicate a significant difference in morphology variation of sella turcica in class maloklusi Class I compared with group of Skeletal Class II maloklusi, obtained the most normal morphology of sella turcica in the sample group of Class I skeletal with ANB value 0-4 value of 35 samples (83.3%) than in the Class II skeletal sample group with an ANB value of 4 of 7 samples (16.7%), wherein we know that the ANB angle indicates a sagittal growth discrepancy of the apical base of the jaw.

The results of research by Sujaani et al 2014, the morphology of sella turcica in Class I malocclusion is reported to be about 71% having normal sella turcica. Bridging sella, irregular (notching) posterior wall and pyramid more commonly found in Class II than Class I, this is in accordance with the results of this study, obtained sella turcica normal on Class I of 83.3% while in Class II of 16.7% . Bridging sella on Class I of 35% while Class II of 65%, irregular (notching) posterior wall on Class I of 22.2% while in Class II of 77.8%.

This research shows that the correlation between morphological variation of sella turcica with skeletal Class II malocclusion per ANB can't be known due to uneven distribution of samples, where the number of samples each ANB value is not the same.

REFERENCES

[1] S. Valizadeh, S. Shahrzad, S. Mohseni, "Correlation of shape and size of sella turcica with the type of facial skeletal class in Iranian group," Iran J. Radiol., vol. 3, pp. 1-7, 2015.
[2] A.M Shah, U. Bashir, "The shape and size of the sella turcica in skeletal class I, II & III in patients presenting at Islamic International Dental Hospital, Islamabad," Pakistan Oral & Dental Journal, vol. 31(1), pp. 104-110, 2011.
[3] I.N. Ize-Iyamu, "Sella turcica shape, linear dimensions and cervical vertebrae staging in preorthodontic patients in Benin City, Nigeria," Sahel Medical Journal, vol. 17(4), pp. 151-158, 2014.
[4] G.S. Ani, J. James, S.P. Prasanth, "Morphology of sella turcica in skeletal class II subjects," Medical Sciences-Faculty of Dentistry, vol. 4, pp. 1-12, 2014.
[5] R. Leonardi, E. Barbato, M. Vichi, "A sella turcica bridge in subjects with dental anomalies," European Journal of Orthodontics, vol. 28, pp. 580-585, 2006.
[6] A. Kucia, T. Jankowski, M. Siewniak, "Sella turcica anomalies on lateral cephalometric radiographs of Polish children," Dentomaxillofacial Radiology, vol. 43: 1-6, 2014.
[7] M. Andredaki, A. Koumantanou, Dorotheou, "A cephalometric morphometric study of sella turcica," European Journal of Orthodontics, vol. 29, pp. 449-456, 2007.
[8] P. Meyer-Marcotty, T. Reuther, A Stellzig-Eisenhauer, "Bridging of the sella turcica in skeletal class III subjects," European Journal of Orthodontics, vol. 32, pp. 148-153, 2009.
[9] I. Kjaer, "Sella turcica morphology and the pituitary gland-A new contribution to craniofacial diagnostics based on histology and neuroradiology," European Journal of Orthodontics, vol. 37(1), pp. 28-35, 2015.
[10] J.P. Becktor, S. Einersen, I. Kjaer, "A sella turcica bridge in subjects with severe craniofacial deviations," European Journal of Orthodontics, vol. 22, pp. 69-74, 2000.
[11] T. Nagaraj, R. Shruthi, L. James, "The size and morphology of sella turcica: A lateral cephalometric study," Journal of Medicine, Radiology, Pathology & Surgery, vol. (1), pp. 3-7, 2015.
[12] H.P. Sathyanarayana, V. Kailasam, A.B. Chitharanjan, "Sella turcica-Its importance in orthodontics and craniofacial morphology," vol. 10(5), pp. 571-575, 2013.
[13] B. Ali, A. Shaikh, M. Fida, "Association between sella turcica bridging and palatal canine impaction," Am. J. Orthod. Dentofacial Orthop., vol. 146, pp. 437-41, 2014.
[14] S. Axelsson, K. Storhaug, I. Kjaer, "Post-natal size and morphology of the sella turcica. Longitudinal cephalometric standards for norwegians between 6 and 21 years of age," European Journal of Orthodontics, vol. 26, pp. 597-604, 2004.
[15] R.M. Jones, A. Faqir, D.T. Millett, "Bridging and dimensions of sella turcica in subjects treated by surgical-orthodontic means or orthodontics only," Angle Orthod., vol. 75, pp. 714-718, 2005.
[16] G.S. Ani, J. Jose, S.P. Prasanth, "Morphology of sella turcica in subjects with highly placed canines," Int. J. Bioassays, vol. 4(06), pp. 3968-3972, 2015.
[17] I.E. Perez, A.K. Chavez, D. Ponce, "Frequency of sela turcica bridge and clinoid enlargement in lateral cephalometric plain film radiography from Peruvians," Int. J. Morphol., vol. 31(2), pp. 373-377, 2013.

[18] A. Becker, S. Chaushu, "Etiology of maxillary canine impaction: A review," Am. J. Orthod. Dentofacial Orthop., vol. 148, pp. 557-67, 2015.
[19] R. Leonardi, M. Farella, M.T. Cobourne, "An association between sella turcica bridging and dental transposition," European Journal of Orthodontics, vol. 33, pp. 461-465, 2011.
[20] A. Gracco, L. Luca, M.C. Bonhodgiorno, "Computed tomography evaluation of mandibular incisor bony support in untreated patients. Am. J. Orthod. Dentofacial Orthop., vol. 138, pp. 179-87, 2010.
[21] A.R.P. Kusuma, "Bernafas lewat mulut sebagai faktor ekstrinsik etiologi maloklusi," Majalah Ilmiah Sultan Agung, vol. 48 (123), pp. 1-19, 2010.
[22] W.R. Proffit, Contemporary orthodontics. 4th ed., Missouri: Mosby, 2007, pp. 3-21, 208-9.
[23] M.T. Coubourne, A.T. Dibiase, Handbook of orthodontics. Missouri: Mosby, 2010, pp. 150-79.
[24] G. Singh, Textbook of orthodontics, 2nd ed., New Delhi: Jaypee, 2007, pp. 3-6, 30-6, 94-116.
[25] A. Jacobson, Radiographic cephalometry: From basics to videoimaging, London: Quintessence Publishing Co., 1995, pp. 77-85, 131-2.