ATLANTIS PRESS

Advances in Health Science Research, volume 8

International Dental Conference of Sumatera Utara 2017 (IDCSU 2017)

Treatment of Class III Malocclusion with Reverse Twin Block in the Growing Child (Case Report)

Trio Novalia
Postgraduate Student
Department of Orthodontics
Faculty of Dentistry, Universitas Sumatera Utara
Medan, Indonesia

Nazruddin
Department of Orthodontics
Faculty of Dentistry, Universitas Sumatera Utara
Medan, Indonesia

Abstract–Class III malocclusion has a great variation of skeletal pattern in either the antero-posterior orvertical planes. If left untreated, Class III malocclusion in the growing children will become worse with age, presented by the growth of the mandible exceeding the growth of the maxilla.A male patient aged 10 years and 6months came to Orthodontic Clinic Faculty of Dentistry University of Sumatera Utara with a chief complaint of unaesthetic appearance of lower front teeth. Diagnosis showed Class III malocclusion with mandibular prognathism, anterior cross-bite, and smaller upper jaw relative to lower jaw. In this case, stage 1 treatment was done by using Twin Block Class III or Reverse Twin Block appliance to correct the skeletal relationship in sagittal plane, obtain normal overjet and also prevent concave and asymmetry facial profile. Reverse Twin Block is designed by reversing the angulation of the inclined planes, drives forward maxillary development and restricts forward mandibular growth by harnessing occlusal forces as the functional mechanism to correct arch relationship. The results of this treatment were the correction of skeletal relationship, normal overjet, and stable facial profile. As a conclusion, Reverse Twin Block appliance can be used as an early treatment for skeletal Class III malocclusion in growing child.

Keywords–class III malocclusion, Reverse Twin Block, growing child

I. INTRODUCTION

Class III malocclusion has a great variant of skeletal patterns in either the antero-posterior or vertical planes. Bolton-Brush Growth study conducted by Guyers and co-workers showed considerable skeletal variability in the Class III malocclusion, with the following characteristics being noted on cephalometric analysis: mandibular prognathism alone 18,7%; maxillary retrusion alone 25%; maxillary retrusion/mandibular protrusion 22%; increased lower anterior face height 41% [1-4].

Growth potential complicates the treatment of Class III malocclusion in growing patient. If left untreated, Class III malocclusion in the growing children will become worse with age, presented by the growth of the mandible exceeding the growth of the maxilla [1,2,5]. This unfavourable growth can also occur late in adolescence or in early adulthood, especially in relation to mandibular prognathism. Hence, although in Class III cases that are successfully treated, there is still a risk thatthe Class III growth pattern may re-establish itself [1,5,6].

Functional appliance is commonly used for the treatment of an increased overjet and a Class II malocclusion. However, this appliance has also been reported to be used in the treatment of Class III malocclusion by some clinicians. Indeed, for every Class II functional appliance, there is usually a modification for the treatment of Class III malocclusion [1,2,7].

In the Twin Block technique, functional correction of Class III malocclusion is achieved by reversing the angulation of the inclined planes and utilizing occlusal forces as the functional mechanism to correct arch relationships. Reverse Twin Blocks are designed to advance maxillary development by the action of reverse occlusal inclined planes and at the same time inhibit forward mandibular development [2,3,6,7,8].

II. CASE REPORT

A male patient aged 10 years and 6months came to Orthodontic Clinic Faculty of Dentistry University of Sumatera Utara with a chief complaint of unaesthetic appearance of lower front teeth.Patient was in good general health without deleterious oral habit. He had no history of trauma, surgery or infection.

Extraoral examination showed symmetrical leptoprosopic face, a straight profile and incompetent lips. He exhibited no temporomandibular joint symptoms (Figure 1).

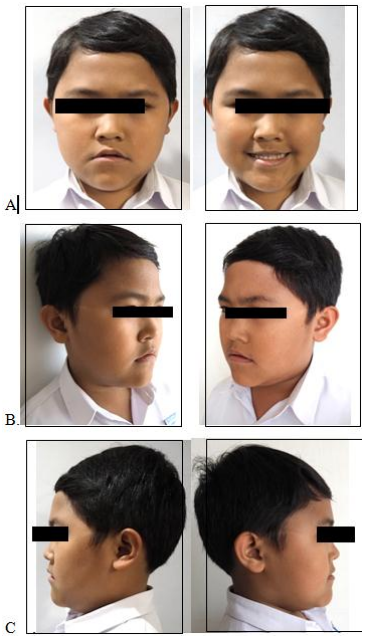

Figure 1. Pretreatment facial photographs.

Intraorally, patient had anterior crossbite on his maxillary right canine and incisors. He had good oral hygiene with healthy gingiva. Reverse overjet -2 mm and overbite 4 mm were noted. The mandibular dental midline was shifted 0,5 mm to the right and diastema presented on lower teeth. He had mild Class III molar relationship on both sides, a Class I canine relationship on the right side, and a Class III ¼ P canine relationship on the left side (Figure 2).


Figure 2. Pretreatment intraoral photographs.

The lateral cephalometric analysis (Fig 3) indicated a skeletal Class III pattern with a prognathic mandible (SNB 82°, ANB -1^0, Wits Appraisal -7 mm), concave skeletal convexity (NaPog -2°), clockwise mandibular rotation (MP-SN 38°), normal growth pattern (NSGn 67^0), maxillary incisor proclination (UI-SN 100^0) and mandibular incisor retroclination(LI-MP 86°). Upper and lower lips were behind E-line -5 mm and -2 mm respectively.

Hassel and Farman cervical vertebral maturation analysis showed that patient was in transition stage with 25%-65% of adolescent growth expected.

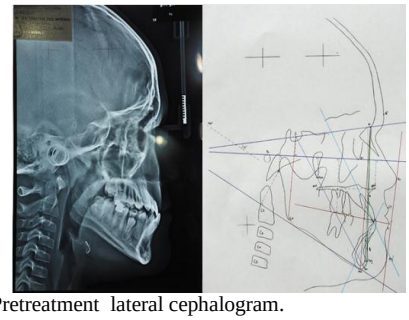
Figure 3. Pretreatment lateral cephalogram.

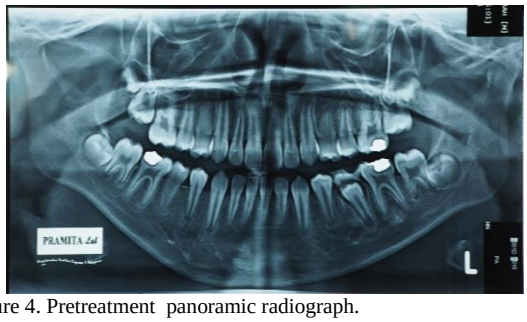
Figure 4. Pretreatment panoramic radiograph.

TABLE I. CEPHALOMETRIC MEASUREMENTS

Measurements	X Mean (S.E.Bishara) 10-17years-old	SD St. Dev	March 20th 2017	August 30th 2017
Skeletal				
SNA°	81°	±3,8°	81°	82°
SNB°	78°	±3,3°	*82°	81°
ANB°	3°	±1,7°	*-1°	1°
NAPog°	7°	± 4,3°	*-2°	0°
MP :SN°S	32°	±5,2°	*38°	37°
NSGn°(Y-axis)	68°	± 3,2°	67°	67°
Pog : NB mm	1 mm	±1,8 mm	+ 1 mm	+ 1,5 mm
SGo :Nme %	69%	± 4,7°	75/128 x100% = 58,59%	75/128 x100% = 58,59%
Dental				
1 : ī°	128°	± 6,7°	126°	127°
1 : SN°	102°	± 4,9°	*110°	115°
ī : MP°	98°	±5°	*86°	81°
1 :APog mm	5 mm	±1,6 mm	6 mm	7,5 mm
ī: NB mm	5 mm	±1,2 mm	*8 mm	7 mm
Soft Tissue				
E-line:LS mm	-1 mm	±1,9 mm	*-5mm	-3 mm
E-line : LI mm	0	±1,7 mm	*-2mm	-2 mm
Witts Appraisal AO-BO	-1 mm	± 2 mm	*-7mm	-6 mm

Diagnosis showed Class III malocclusion with mandibular prognathism, anterior cross-bite, and smaller upper jaw relative to lower jaw.In this case, stage 1 treatment was done by using Twin Block Class III orReverse Twin Block appliance to correct the skeletal relationship in sagittal plane, obtain normal overjet and also prevent concave and asymmetry facial profile.Stage 2 will be aimed to correct dentition on maxilla and mandibula by using fixed appliance.

III. CASE MANAGEMENT

Treatment was started by inserting Reverse Twin Block on upper and lower jaw. Reverse Twin Block is

designed by reversing the angulation of the inclined planes, drives forward maxillary development and restricts forward mandibular growth by harnessing occlusal forces as the functional mechanism to correct arch relationship.

In order to accelerate adaptation, Twin Blockwasfixed by using cement on the tooth-bearing areas of the appliance but not on the gingival areas. The appliance was positioned and secured in place with glass ionomer cement adhering to the teeth, but ensured that the appliance could be freed easily from the teeth. Zinc phosphate or zinc oxide cement or composite could also be bonded directly to the teeth for temporary fixation.

It is important to assure that the patient closes consistently on the inclined planes with the new position of retruded mandible. Instruction for activating the expansion screw (one quarter turn every 3 days) was given when the patient had learned to insert and remove the appliance. The screw should be activated for the first time after the appliances have attached in comfortably on both upper and lower jaw.

In the beginning of treatment, lower bite-block was trimmed to drive eruption of the lower molars.In order to stimulate maxillary advancement, the leading edge of the inclined plane on the upper bite block should remain intactin contact with the lower inclined plane.Reactivation could be achieved by extending the inclined plane of the lower Twin Block mesially to increase the forward posture of the maxilla. Labial bow at lower jaw was activated to retrude mandibular anterior teeth and to remove mandibular diastema.

When the molars had erupted into occlusion, a lateral open bite was present in the premolar region because the upper bite block was still intact. Final adjustment at the end of the Twin Block stage aims to reduce the lateral open bite. It could be reduced by trimming the upper occlusal surface of the upper bite block over the premolars by 2 mm. Lower premolars will erupt into occlusion once they are relieved of occlusal contact so that the lateral open bite in the premolar region now reduces and the occlusal plane begins to level. The tongue itself couldinhibitthe eruption of lower premolars soit is important to leave only a small vertical clearance about 1 or 2 mm over the lower premolars. A probe could be used to check the clearance between the premolar teeth and lower blocks to establish that the lower premolars are free to erupt.

Appliance is wornonly at night time when the posterior occlusion is fully established. A good buccal segment occlusion is the key of stability after correction of arch-to-arch relationships.Treatment is followed by retention with Hawley retainer until maturation of root apex of permanent teeth. After maturation of all permanent teeth and posterior occlusion has fully established, this treatment will be continued into stage II with fixed appliances. Fixed appliances will be used to achieve ideal intercuspation.

Figure 5. Appliances insertion in oral cavity photographs.

After 6 months, negative overjet was corrected into + 1 mm and the stage 1 treatment objectives were achieved. The results of this treatment were the correction of skeletal relationship, normal overjet, and stable facial profile.Cephalometric post treatment showed significant skeletal changes from Class III skeletal into Class I (SNA from $81^o$to 82°, SNB from 82° to 81°, ANB from -1° to 1°) (Table 1). The superimposition of pretreatment and posttreatment lateral cephalograms showed the advancement of maxilla and the setback of mandible.

Figure 6. Post-Treatment facial photographs

Figure 7. Posttreatment intraoral photographs.

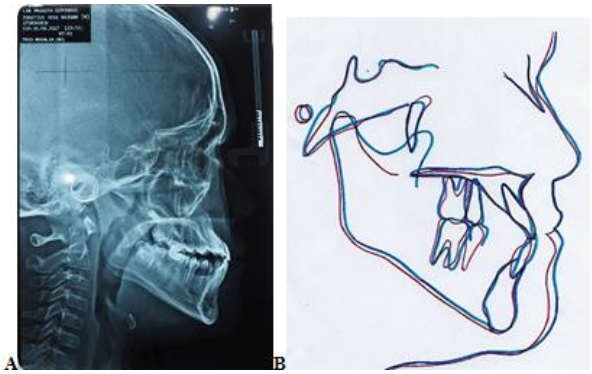

Figure 8. A. Posttreatment lateral cephalogram B. superimposition of pretreatment (blue) and posttreatment (red).

IV. DISCUSSION

Early treatment of Class III malocclusion should be conducted as soon as the abnormality is seen to prevent it from becoming permanent Class III malocclusion. Orthopedic treatment of Class III malocclusion in prepubertal stage is more effective either in the maxilla (which exhibits a supplementary growth of about 2 mm over Class III untreated controls) or the mandible (where it shows restriction in growth of about 3,5 mm over controls) [3,9,10].

The Twin Block appliance is widely used for the treatment of Class II malocclusion and not many cases are reported in the literature about its use in Class III malocclusion. In this case, we were using Reverse Twin Block to see its effectivity in the treatment of Class III malocclusion. Reverse Twin Blocks are different with Twin Blocks Class II. In Reverse Twin Blocks, occlusal forces are directed to move the mandible downward and backward to the posterior [2,6]. These forces contribute in correcting jaw relationship. In this case, pre treatment lateral cephalometric showed Class III skeletal relationship and post treatment became Class I skeletal relationship.

Twin Blocks are well-tolerated because the appliances can be worn during eating and speaking without overly restricting normal movements of the tongue, lips and mandible. This means that patient could eat with the appliances in the mouth and the forces of mastication are harnessed as functional forces to change arch relationship.The patient may be suggested to remove the appliance while eating for the first few days. Then it is important to learn with the appliance attached in the mouth while eating. Learning to eat with the appliance is important because the force of mastication could accelerate treatment time. In a few days, patients should be eating with the Twin Block attached and within a week, should be more comfortable with the appliance in the mouth than without it [6].

Twin Block has the unique advantage compared to the other functional appliances in the way that they can be fixed to the teeth. Such temporary fixation guarantees full-time wear, 24 hours per day and excellent cooperation is established at the start of treatment [6].

Few months after the insertion of Twin Block, maxillary anterior teeth started to move anteriorly, showed an edge-to-edge incisor relationships. In this case, skeletal relationship improved after 5 months of treatment, ensured by lateral cephalometric analysis. We concluded that this happened because the mandible rotated downward and backward. Dentoalveolar changes were also observed after Twin Block treatment. Maxillary incisors showed greater proclination and increased retroclination of mandibular incisors. We also added maxillary expansion screw to expand the maxilla in transverse dimension to improve posterior edge-to-edge occlusion.

As a conclusion, reverse Twin Block application to correct skeletal relationship in Class III malocclusion is proven. Appropriate appliance design, adequate use and patient compliance are the keys for good outcomes. Reverse Twin Block appliance can be used as an early treatment for skeletal Class III malocclusion in growing child.

ACKNOWLEDGMENT

Acknowledgments are addressed to the Minister of Research, Technology and Higher Education of Indonesia, at the expense of this study was derived from DRPM Directorate General of Strengthening Risbang in 2017.

REFERENCES

[1] P. Fleming, R. Lee, Orthodontic functional appliances-theory and practice, India: Wiley, 2016, pp. 119.
[2] S.S. Sargod, N. Shetty, A. Shabbir, “Early class III management in deciduous dentition using reverse twin block,” J. Indian Soc. Pedod. Prev. Dent., vol. 31, pp. 56-60, 2013.
[3] M. Mittal, et al., “Reverse twin block for interceptive management of developing class III malocclusion,” J. Indian Soc. Pedod. Prev. Dent., vol. 35, pp. 86-89, 2017.
[4] P.V.P.O. Navarro P, et al., “Early treatment protocol for skeletal class III malocclusion,” Brazilian Dental Journal, vol. 24(2), pp. 167-173.
[5] J. Seehra, F.S. Fleming, N. Mandall, A.T. DiBiase, “A comparison of two different techniques for early correction of class III malocclusion,” Angle Orthod., vol. 82, pp. 96-101, 2012.
[6] W.J. Clark, Treatment of class III malocclusion: Twin block funcional therapy applications in dentofacial orthopedics, 3rd ed., New Delhi: Jaypee, 2015, pp. 227.
[7] G. Kidner, A. DiBiase, D. DiBiase, “Class III twin blocks: a case series,” Journal of Orthodontics,” vol. 30, pp. 197-201, 2003.
[8] N. Negi, K.S. Negi, “Management of pseudo class III malocclusion with reverse twin block,” Scholar Journal of Applied Medical Sciences, vol. 5(1 D), pp. 244-248, 2017.
[9] V.K. Chugh, P. Tandon, V. Prasad, A. Chugh, “Early orthopedic correction of skeletal class III malocclusion using combined reverse twin block and face mask therapy,” J. Indian Soc. Pedod. Prev. Dent., vol. 33, pp. 3-9, 2015.
[10] T. Baccetti, L. Franchi, J.A. McNamara, “The cervical vertebral maturation (CVM) method for the assessment of optimal treatment timing in dentofacial orthopedics,” Semin. Orthod., vol. 11, pp. 119-129, 2005.